



ORIGINAL ARTICLE

# Spinal N13 versus cortical N20 and dermatomal somatosensory evoked potential studies in patients with cervical radiculopathy

Mohamed Imam \*, Marwa Hassan

*Physical Medicine, Rheumatology and Rehabilitation Department, Faculty of Medicine, Alexandria University, Egypt*

Received 9 May 2012; accepted 5 March 2013

Available online 6 April 2013

## KEYWORDS

Spinal SEP;  
N13;  
Cervical Radiculopathy

**Abstract** *Introduction:* Most studies on somatosensory evoked potentials (SEPs) in cases of cervical radiculopathy routinely analyze scalp (cortical) responses (mixed or dermatomal SEPs), depending mainly on evaluation of N20 whose origin is the primary somatosensory cortex. It was suggested that selective study of the N13 potential, might be a useful technique to improve both accuracy and sensitivity of the diagnosis of cervical radiculopathy.

*Aim:* The aim of our study was to test the sensitivity of the spinal N13 potential in uncovering lesions of cervical nerve root; and to compare it to dermatomal and mixed nerve SEPs.

*Methods:* Forty patients with clinical suspicion of cervical nerve root lesion had been selected. Twenty normal subjects constituted the control group. Magnetic resonance imaging (MRI) of the cervical spine was performed for all patients to reveal the presence of any cervical nerve root compression. The following electrophysiological studies were done (sensory and motor conduction studies of the median and ulnar nerves, mixed SEP of median nerve, dermatomal SEP and spinal N13 SEP study of the median nerve).

*Results:* There was a positive correlation between the mixed and the dermatomal SEPs and between the mixed SEP and N13. On the other hand there was a positive correlation between the dermatomal SEPs and N13. There was a positive correlation between the MRI and the mixed SEP, the dermatomal SEP and N13, respectively. Sensitivity and specificity of N13, dermatomal somatosensory evoked potentials (DSEP) and mixed SEP were determined using MRI as a gold

\* Corresponding author.

E-mail addresses: [imammohamed884@gmail.com](mailto:imammohamed884@gmail.com), [maramimam@yahoo.com](mailto:maramimam@yahoo.com) (M. Imam).

Peer review under responsibility of Alexandria University Faculty of Medicine.



Production and hosting by Elsevier

standard. N13 is the most sensitive followed by DSEP and the least was the mixed somatosensory evoked potentials (MSEP). They were all specific with a high positive predictive value. N13 had the highest negative predictive value followed by DSEP and the least was MSEP and we concluded from this study that N13 is a sensitive technique which is suitable for detecting early and mild symptomatic cervical nerve root lesion.

© 2013 Production and hosting by Elsevier B.V. on behalf of Alexandria University Faculty of Medicine.

## 1. Introduction

The difficulties in diagnosing nerve root involvement due to compressive cervical nerve root lesions are well known in clinical neurology. Several electrophysiological methods have been used to evaluate nerve root functions in those cases.<sup>1</sup> Among these tests are needle electromyography (EMG) and *F*-wave studies which are useful, but they only give information concerning efferent fibers and do not allow evaluation of sensory fiber function. Therefore, if motor fibers are not damaged, needle EMG and *F* wave studies will be normal.<sup>2,3</sup>

There is probably no area that has generated as much controversy as the use of somatosensory evoked potentials (SEPs) in the evaluation of radiculopathies.<sup>4</sup> The interest in using SEPs for the evaluation of radiculopathies is based on the fact that symptoms and signs in radiculopathies can usually be related to injury to afferent fibers, and SEPs can monitor injury to these fibers.<sup>4</sup>

Mixed somatosensory evoked potentials (MSEPs) derived by stimulation of major nerve trunks as median or ulnar nerves are generally normal in cases of monoradiculopathy because of the polysegmental nature of these nerves.<sup>5</sup> Dermatome SEPs are more segmentally specific but their sensitivities in diagnosing cervical radiculopathies were reported to have varying sensitivity 28–72%.<sup>4</sup> A possible reason for discordance between SEP results and abnormal sensory symptoms is the affection of small nerve fibers which are not evaluated by standard SEP techniques.<sup>6</sup>

The SEP pathway follows the classical posterior column pathway. The stimulus must excite the largest myelinated afferent fibers in the peripheral nerve then the dorsal column sensory fibers, the cell bodies of which lie in the dorsal root ganglion. The response then travels in the ipsilateral posterior column to synapse in the dorsal column nuclei. They cross in the medial lemniscus to the ventral posterior lateral nucleus of the thalamus. After synapse in the thalamus the third relay goes to the cortex. The stimulation techniques may be through mixed nerve stimulation, cutaneous nerve stimulation, dermatome nerve stimulation, motor point stimulation or paraspinous nerve stimulation. Because electrical stimulation of a mixed nerve initiates a relatively synchronous volley that elicits a sizeable SEP, it becomes the standard clinical use. Dermatome stimulation may produce desynchronized SEPs that may be difficult to interpret. Care must be taken to avoid stimulation of the nearby dermatomes and the underlying muscle which induces activity of the Ia afferents and the digital cutaneous nerve. This is achieved if the stimulus is kept at 2.5 times the sensory threshold, which gives about 80% of the maximum amplitude. The spinal potential, termed N13 potential reflects the activity of dorsal horn neurons receiving their inputs from large myelinated fibers.<sup>5</sup> N13 spinal potential reflects the response of dorsal horn neurons to stimulation of collateral

branches of somatosensory ascending pathways.<sup>7,8</sup> N13 refers to the potential recorded at the lower level of the neck most often at sixth cervical spinal process.<sup>3</sup> N13 is considered to originate from postsynaptic dorsal neuron activity in the spinal cord.<sup>1</sup>

Most studies on SEPs in cases of cervical radiculopathy routinely analyze scalp (cortical) responses, depending mainly on evaluation of N20 whose origin is the primary somatosensory cortex.<sup>9</sup> It was suggested that selective study of the N13 potential, might be a useful technique to improve both accuracy and sensitivity of the diagnosis of cervical radiculopathy.<sup>4</sup>

### 1.1. Aim

The aim of our study was to test the sensitivity of the spinal N13 potential in uncovering lesions of cervical nerve root versus dermatome and mixed nerve SEPs.

## 2. Methods

(a) *Subjects*: Forty patients with clinical suspicion of cervical nerve root lesion had been selected. Twenty normal subjects constituted the control group to determine the cut off points for the electrophysiological parameters.

(b) *Procedures*:

1. MRI of the cervical spine was performed for all patients to detect cervical nerve root compression if present.
2. The following electrophysiological studies were done:

- Sensory and motor conduction studies of the median and ulnar nerves.
- Mixed SEP of median nerve.
- Dermatome SEP studies of the affected upper limb. DSEP was done according to the root suspected clinically.
- Spinal N13 SEP study of the median nerve.
- Electromyography was done in myotome distribution based on MRI findings. EMG activity in upper limb muscles was considered abnormal when fibrillation potentials and positive sharp waves were found or MUAPs are polyphasic or of increased duration in two or more muscles under study.

The SEP recording procedure was done while the patients were lying on a couch in a warm and semi-darkened room. Two hundred stimuli were commonly used with at least 60 stimuli used if a good response was recorded; on the other hand, more stimulation were required if a bad response was recorded. The used sweep speed was 10 ms/division, sensitivity of 1–5  $\mu$ V/division and a filter band setting between 10 Hz and 3 kHz. The stimulation was done with pulse duration of

0.5 ms and a frequency of 1 Hz. The recorded findings included the latency of the N20 for mixed and dermatomal SEP and the N13 latency.

For the dermatomal SEP, the stimulus intensity used was three times the sensory threshold, without exceeding the pain threshold and avoiding visible contractions of the underlying muscles. Dermatomal stimulation was done according to dermatomal SEP maps<sup>10,11</sup> in order to minimize the possibility of dermatome overlapping.

Scalp–scalp montages were used where the C3' scalp recording point for the right upper limb stimulation and the C4' for the left upper limb stimulation. The reference electrode was placed at the FZ point according to the international 10–20 system of electrode placement.<sup>5</sup> The cervical spine C6 was the spine recording point for N13 and the reference point was immediately above the thyroid cartilage. The recording electrode placed over C6 root with surface marking was immediately above the thyroid cartilage, just above occipital protuberance with the active electrode on the midline and the reference electrode paramedian in position. Surface recording electrodes were used and needle recording was sometimes used if the recording potentials were badly reproduced.

Obtained data were considered abnormal if exceeded the cut off points (mean  $\pm$  2 SD) of control group of patients (20 patients).

### 3. Statistical analysis

Data were analyzed using the Statistical Package for Social Sciences (SPSS ver. 18 Chicago, IL, USA). Comparing quantitative variables in two groups was conducted using Mann–Whitney U test while correlation between two quantitative variables was done using Spearman rho correlation test.

In all statistical tests, level of significance of 0.05 was used, below which the results are considered to be statistically significant.

The cut off values were calculated according to the following equation:

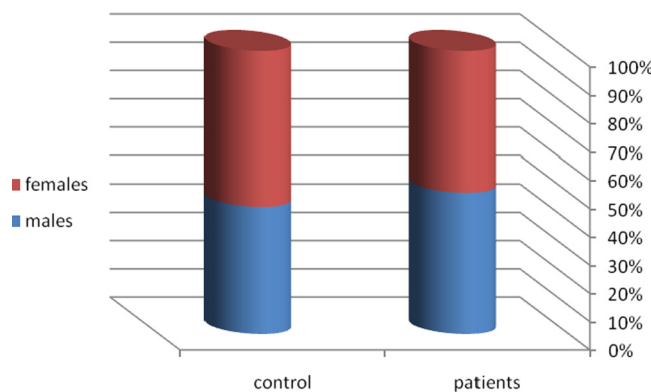
Latency cut off value = the mean latency + 2SD.

Sensitivity, specificity, positive predictive and negative predictive values of N13, DSEP and mixed SEP were determined using MRI as a gold standard.

### 4. Results

Forty patients with clinical suspicion of cervical radiculopathy and a mean age of 41.5 years (ranged from 29 to 60 years) were enrolled in this study. Males constituted 50% and females 50%. Their results had been compared with twenty normal subjects having a mean age of 43.2 years and comparable sex distribution (45% males and 55% females) as a control group (Fig. 1).

All the patients suffered from cervical pain while radicular pain or paraesthesia in upper limbs was present in 28 patients (70%). Clinical examination of upper limbs revealed hypoesthesia of dermatomal pattern in 16 patients (40%). Reduced or absent tendon reflexes were observed in four patients (10%). No weakness or wasting of upper limb muscles was found in any of the patients. No patient had any pathological reflex (Fig. 2).



**Figure 1** The distribution of sex of the examined patients and the control group.

MRI revealed cervical nerve root compression in 31 patients (78%). Single root affection was detected in eight patients (20%) by MRI while in 23 patients (58%) there was compression on more than one root. In all patients with MRI findings of root compression, the root compressed was consistent with the patient complaint of radicular pain and hypoesthesia detected by clinical examination (Fig. 3).

Nerve conduction studies and needle EMG examinations were within normal limits in all the studied patients. Twenty patients (50%) had delayed N13 latency. DSEP latency delay was detected in 16 patients (40%) while delay in mixed SEP latency was detected in only 10 patients (25%).

All cases which had MSEP abnormalities showed abnormal DSEP and N13 latencies. On the other hand, all cases – except one case – that showed delayed DSEP latency had abnormalities in N13 latency (Fig. 4).

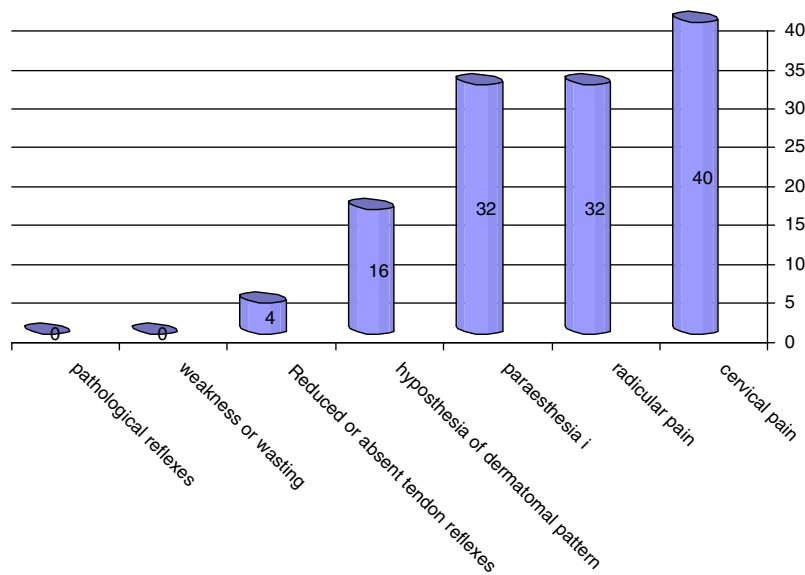
The relation between the mixed, dermatomal and spinal N13 SEPs is shown in Table 1. There was a positive correlation of a statistical significance between the mixed and the dermatomal SEPs ( $P < 0.001$ ) and between the mixed SEP and N13 ( $P < 0.001$ ). On the other hand there was a positive correlation of a statistical significance between the dermatomal SEPs and N13 ( $P < 0.001$ ) (Table 1).

The relation between the MRI and the mixed, dermatomal and spinal (N13) SEPs is shown in Table 2. There was a positive correlation of a statistical significance between the MRI and the mixed SEP ( $P = 0.001$ ), the dermatomal SEP ( $P = 0.004$ ) and N13 ( $P = 0.002$ ), respectively (Table 2).

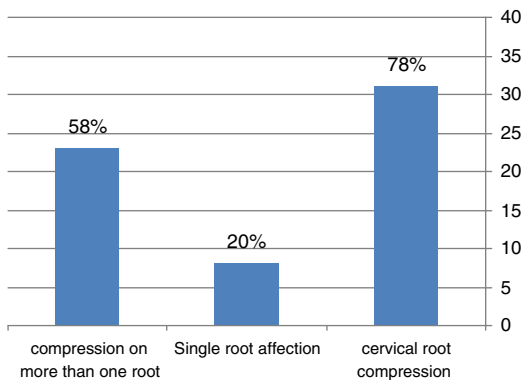
Sensitivity and specificity of N13, DSEP and mixed SEP were determined using MRI as a gold standard (Table 3). N13 was the most sensitive (64.5%) followed by DSEP (51.6%) and the least was MSEP (32.2%). They were all specific (100%) with a high positive predictive value (100%). N13 had the highest negative predictive value (45%) followed by DSEP (37.5%) and the least was MSEP (30%).

### 5. Discussion

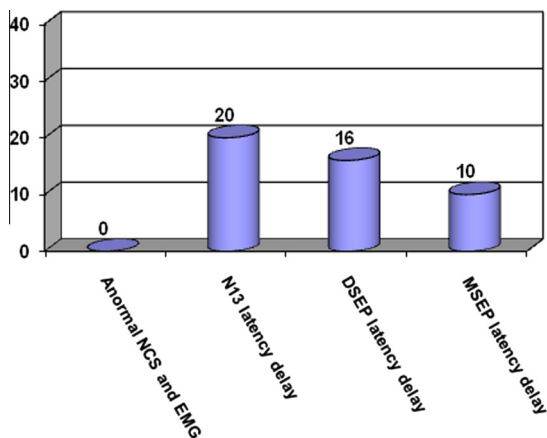
Several electrophysiological methods have been used to evaluate nerve root functions.<sup>12</sup> Among these tests the most commonly used are needle EMG which may show denervation in a myotomal distribution, and *F* wave latency measurements which may reveal slowing of proximal motor conduction. Both tests are



**Figure 2** The frequency of the clinical findings of the examined patients.



**Figure 3** The frequency of the MRI findings of the examined patients.



**Figure 4** The frequency of the electrophysiological abnormalities of the examined patients.

useful, but they only give information concerning efferent fibers and do not allow evaluation of sensory fiber function.

**Table 1** Correlation between MSEP, DSEP and N13.

		DSEP	N13
<i>MSEP</i>	rho	0.597*	0.535*
	<i>p</i>	< 0.001	< 0.001
<i>DSEP</i>	rho		0.593*
	<i>p</i>		< 0.001

rho ( $\rho$ ): Spearman coefficient.  
\* Statistically significant at  $p \leq 0.05$ .

**Table 2** Relation between MRI and MSEP, DSEP and N13.

	MRI		<i>p</i>
	Normal ( <i>n</i> = 9)	Abnormal ( <i>n</i> = 31)	
<i>MSEP</i>			
Range	18.10–20.10	19.0–27.50	0.001*
Mean $\pm$ SD	19.19 $\pm$ 0.62	21.19 $\pm$ 2.03	
Median	19.0	20.20	
<i>DSEP</i>			
Range	18.50–19.70	18.0–28.20	0.004*
Mean $\pm$ SD	19.22 $\pm$ 0.38	22.64 $\pm$ 3.42	
Median	19.20	23.0	
<i>N13</i>			
Range	12.0–12.90	10.90–20.80	0.002*
Mean $\pm$ SD	12.33 $\pm$ 0.30	15.91 $\pm$ 3.10	
Median	12.30	16.70	

*p*: *p* value for Mann–Whitney test.  
\* Statistically significant at  $P \leq 0.05$ .

Therefore, if motor fibers are not damaged, needle EMG and *F* wave studies will be normal. The utility of mixed and dermatomal somatosensory evoked potentials in the diagnosis of root lesion had been evaluated in several papers.<sup>12–14</sup> Many studies

**Table 3** Sensitivity, specificity, positive and negative predictive values of MSEP, DSEP and N13 taking the MRI results as a gold standard.

	Sensitivity (%)	Specificity (%)	PPV (%)	NPV (%)
MSEP	32.2	100	100	30
DSEP	51.6	100	100	37.5
N13	64.5	100	100	45

PPV: positive predictive value.

NPV: negative predictive value.

which analyzed only scalp responses after mixed nerve or dermatomal stimulation have led to contradictory results concerning the sensitivity of which ranged from 7%<sup>1</sup> to 95%.<sup>12</sup> It was suggested that selective study of the N13 potential might be a useful technique to improve the accuracy and sensitivity of the SEPs in diagnosing cervical monoradiculopathy especially in patients with radicular sensory manifestations.<sup>2</sup>

In our study, forty patients with clinical suspicion of cervical radiculopathy and a mean age of 41.5 years were enrolled in this study, males constituted 50% and females 50%. Their results had been compared with twenty normal subjects having a mean age of 43.2 years and comparable sex distribution (45% males and 55% females) as a control group. The age and sex distribution of the selected patients was comparable to similar studies and there was no recognizable difference between the patients and the control groups.

All the patients suffered from cervical pain, while radicular pain or paraesthesia in upper limbs was present in 28 patients (70%). Clinical examination of upper limbs revealed hypoesthesia of dermatomal pattern in 16 patients (40%). Reduced or absent tendon reflexes were observed in four patients (10%). No weakness or wasting of upper limb muscles was found in any of the patients. No pathological reflexes were detected in any of the patients. It was observed that most of the examined patients had sensory manifestations which constitute the major abnormality in patients with cervical disorders.<sup>2,7,8</sup>

MRI revealed cervical nerve root compression in 31 patients (78%). Single root affection was detected in eight patients (20%) by MRI while in 23 patients (58%) there was compression on more than one root. In all patients with MRI findings of root compression, the root compressed was consistent with the patient complaint of radicular pain and hypoesthesia detected by clinical examination. There was a positive correlation of a statistical significance between the MRI and the mixed SEP ( $P = 0.001$ ), the dermatomal SEP ( $P = 0.004$ ) and N13 ( $P = 0.002$ ), respectively (Table 2). It was recognized that there was no superiority of any of the SEPs over one another in relation with the MRI.

Nerve conduction studies and needle EMG examinations were within normal limits in all the studied patients. Twenty patients (50%) had delayed N13 latency. DSEP latency delay was detected in 16 patients (40%) while delay in mixed SEP latency was detected in only 10 patients (25%). All cases which had MSEP abnormalities showed abnormal DSEP and N13 latencies. On the other hand, all cases – except one case – that showed delayed DSEP latency had abnormalities in N13 latency. It was recognized that the spinal SEP (N13) was abnormal in half of cases and it was associated with the other SEP tests (mixed and dermatomal) in most of the cases. This had been proved after performing the correlation study demonstrated in Table 1

which showed a positive correlation of a statistical significance between the mixed SEP and N13 ( $P = 0.001$ ) and between the dermatomal SEPs and N13 ( $P = 0.001$ ). From Tables 1 and 2 one can see that N13 correlated significantly with the MRI. Other studies had shown similar results and even a detailed explanation of the sole effect of N13 on the basis that N13 spinal potential reflects the response of dorsal horn neurons to stimulation of collateral branches of somatosensory ascending pathways.<sup>2</sup> Abnormalities of the N13 potential with normal cortical N20 potentials have been found in diseases which affect the cervical central gray matter, leaving dorsal columns unaffected, such as cervical syringes<sup>15</sup> and intramedullary tumors.<sup>16</sup> Alternatively, another hypothesis that can be suggested to explain the discrepancy between abnormal N13 potential and normal N20 responses is that the different distributions of peripheral fibers projecting to the spinal cord gray or white matter would lead to a differential effect of compression acting on these fibers.<sup>2</sup>

Sensitivity and specificity of N13, DSEP and mixed SEP were determined using MRI as a gold standard. N13 is the most sensitive (64.5%) followed by DSEP (51.6%) and the least was MSEP (32.2%). They were all specific (100%) with a high positive predictive value (100%). N13 had the highest negative predictive value (45%) followed by DSEP (37.5%) and the least was MSEP (30%). This is especially true when N13 and DSEP abnormality is due to dysfunction of the dorsal horn cells following cervical nerve root deafferentation which constituted most of our patients. Since collateral branches of dorsal column fibers which supply dorsal horn neurons originate above the site of root compression, we may wonder why N20 components were not also impaired in cervical radiculopathies. Our patients showed only minor root lesions, since all the patients suffered from cervical pain while radicular pain or paraesthesia in upper limbs (28 patients) (70%) and the clinical examination of upper limbs revealed sensory involvement more than motor affection hypoesthesia in 16 patients (40%) while the reduced or absent tendon reflexes were observed in four patients (10%) and no weakness or wasting of upper limb muscles was found in any of the patients. Therefore we may imagine that, in such cases, the conduction block and/or temporal dispersion of the afferent volley at the level of the dorsal roots do not cause abnormalities of scalp SEP because they are compensated by amplification phenomena at more rostral levels. On the contrary, the cervical N13 potential might be particularly sensitive to deafferentation, maybe because the spatial distribution of cells generating N13 response is lower than that of intracranial neurons.<sup>2</sup>

The higher sensitivity of N13 (64.5%) and DSEP (51.6%) more than MSEP (32.2%) in our patients is explained that most of our patients were having sensory complaints which may be more reflected with N13 and DSEP because of their pure sensory component of stimulation. The superiority of N13 over DSEP would be explained by the absence of the possible amplification phenomena at more rostral levels above the level of the cervical nerve root till recorded from the scalp because the spatial distribution of cells generating N13 response is lower than that of intracranial neurons. On the other hand due to this high sensitivity, they were having the highest negative predictive value. All the SEP procedures used in our patients had a high specificity and positive predictive value due to the nature of the patients examined who had mainly sensory complaints which correlate well with the SEP studies.



From this study we can conclude that N13 is a sensitive technique that is correlated with the MRI findings and is sensitive and specific with a high positive predictive value which is suitable for detecting early and minor cervical nerve root lesion with sensory complaints.

## References

1. Bono C, Ghiselli G, Gilbert T, Kreiner S, Reitman C, Summers J, et al. An evidence-based clinical guideline for the diagnosis and treatment of cervical radiculopathy from degenerative disorders. *Spine J* 2011;**11**:64–72.
2. Le Pera D, Valiriani M, Tonali P, Restuccia D. Selective abnormality of the N13 spinal SEP to dermatomal stimulation in patients with cervical monoradiculopathy. *Clin Neurophysiol* 1998;**28**:221–9.
3. Bono C, Ghiselli G, Gilbert T, Kreiner S, Reitman C, Summers J, et al. An evidence-based clinical guideline for the diagnosis and treatment of cervical radiculopathy from degenerative disorders. *Spine J* 2011;**11**:64–72.
4. Fisher M. Electrophysiology of radiculopathies. *Clin Neurophysiol* 2002;**113**:317–35.
5. Cruccu G, Aminoff M, Curio J, Guerit R, Kagigi R, Mauguire F, et al. Recommendations for the clinical use of somatosensory-evoked potentials. *Clin Neurophysiol* 2008;**119**:1705–19.
6. Garcia-Larrea L. Pain evoked potentials. In: Jenssen T, Cervero F, editors. *Handbook of neurology*, vol. 81. Amsterdam: Elsevier; 2006. p. 439–62.
7. Tsiptsios I, Fotiou F, Sitzoglou K, Fountoulakis N. Neurophysiological investigation of cervical spondylosis. *Electromyogr Clin Neurophysiol* 2001;**41**(5):305–13.
8. Fujimoto H, Kaneko K, Taguchi T, Ofuji A, Yonemura H, Kawai S. Differential recording of upper and lower cervical N13 responses and their contribution to scalp recorded responses in median nerve somatosensory evoked potentials. *J Neurol Sci* 2001;**187**:17–26.
9. Mauguire F. Anatomic origin of the cervical N13 potential evoked by upper extremity stimulation. *J Clin Neurophysiol* 2000;**17**(3):236–45.
10. Downs MB, Laporte C. Conflicting dermatome maps: educational and clinical implications. *J Orthop Sports Phys Ther* 2011;**41**(6):427–34.
11. Schwartz D, Albert T, Hilibrand A, Vaccaro A, Sestokas A. Are dermatomal somatosensory evoked potentials useful for assessing adequacy of cervical nerve root decompression? *Spine J* 2003;**3**(5):127.
12. Aminoff MJ, Goodin DS, Parry GJ, Barbaro NM, Weinstein PR, Rosenblum ML. Electrophysiologic evaluation of lumbosacral radiculopathies: electromyography, late responses, and somatosensory evoked potentials. *Neurology* 1985;**35**:1514–8.
13. Aminoff MJ, Goodin DS, Parry GJ, Barbaro NM, Weinstein PR, Rosenblum ML. Somatosensory evoked potentials in unilateral lumbosacral radiculopathy. *Ann Neurol* 1985;**17**:171–6.
14. Alrawi M, Khalil N, Mitchell P, Hughes S. The value of neurophysiological and imaging studies in predicting outcome in the surgical treatment of cervical radiculopathy. *Eur Spine J* 2007;**16**:495–500.
15. Owen JH, Bridwell KH, Lenke LG. Innervation pattern of dorsal roots and their effects on the specificity of dermatomal Somatosensory evoked potentials. *Spine* 1993;**18**(6):748–54.
16. Ibanez V, Fischer G, Mauguire F. Dorsal horn and dorsal column dysfunction in intramedullary cervical cord tumours. A Somatosensory evoked potential study. *Brain* 1992;**115**:1209–34.