

East African Medical Journal Vol. 89 No. 5 May 2012

INTERNAL ROOT MORPHOLOGY IN MANDIBULAR FIRST PERMANENT MOLARS IN A KENYAN POPULATION

N. J. Muriithi, BDS, MDS, Prosthodontist, Ministry of Medical Services, Division of Oral Health, Rift Valley Provincial Hospital, P.O. Box 3356-20100, Nakuru, S. W. Maina, BDS, MSc, AEGD and Anaesthetic Densistry, Senior Lecturer, Department of Conservative and Prosthetic Dentistry, J. Okoth, BDS, MSc, Section Head, Division of Conservative Dentistry, Kenyatta National Hospital, Honorary Lecturer, Department of Conservative and Prosthetic Dentistry, L. Gathece, BDS, MPH, PhD, Senior Lecturer and Head, Department of Periodontology, Community and Preventive Dentistry, School of Dental Sciences, University of Nairobi, P.O. Box 19676-00202, Nairobi, Kenya

Request for reprints to: Dr. N. J. Muriithi, Ministry of Medical Services, Division of Oral Health, Rift Valley Provincial Hospital, P.O. Box 3356-20100, Nakuru, Kenya

INTERNAL ROOT MORPHOLOGY IN MANDIBULAR FIRST PERMANENT MOLARS IN A KENYAN POPULATION

N. J. MURIITHI, S.W. MAINA, J.OKOTH and L.W. GATHECE

ABSTRACT

Objective: To determine the internal root morphology and gender variations in mandibular first permanent molars in a Kenyan population.

Design: *In vitro* descriptive cross sectional study.

Setting: School of Dental Sciences, University of Nairobi

Results: The mesial root of mandibular first molars had two canals in 96.3% of the teeth in both males and females and type IV canal configuration was most prevalent in the mesial root. The distal root of the mandibular first molar had one canal in 57.7% of the teeth in males and females. There were significant gender variations in the number of canals and canal configurations in the distal root. Two canals were more prevalent in females (53.6%) compared to males (30.4%) and a single canal was more frequent in males (69.6%) compared to females (46.4%) ($P=0.001$). Canal types I, II and IV were the most frequent in the mandibular distal root. The gender variation in the frequency of canal types I, II and IV in the distal root was statistically significant ($P=0.001$).

Conclusion: Most of the mandibular first molars have three canals (56%). Two canals in the distal root are more frequent among females (53.6%) compared to males (30.4%).

INTRODUCTION

The scientific advances in analysing endodontic treatment outcomes, improvement of its treatment techniques and designing of the armamentarium has a great bearing on the root morphology. Thus, studying the internal and external anatomy of permanent teeth, specially permanent molars, has been the main scope of many morphological and morphometric studies in different populations (1,2). Various studies have shown different trends in the shape and number of roots and canals amongst different races (1-4).

Root morphology studies have demonstrated that it is not only critical to know the normal or the usual root morphology but it is equally important to be aware of the variations.

The knowledge of internal root morphology is vital in the elimination of all infected debris, toxic materials and pulpal remnants. Unless the practitioner is familiar with the morphology of the roots of all teeth and the associated intricate

root canal anatomy, effective debridement and obturation may be impossible.

Research has shown that the hard tissue repository of the human dental pulp takes on numerous configurations and shapes (1-9). False assumptions about root and root canal morphology may lead to incomplete debridement and obturation of canal space and can eventually lead to unfavourable endodontic treatment outcome. Clearly, the number of roots, canals and their configurations can vary and- literature, as shown in Table 1, demonstrates an extensive number of anatomical variations (10-12). Previous studies on root and canal morphology, which predominantly have been carried out on different tooth types of Caucasian and Asian populations have indicated these variations (2, 11, 13).

Application of conventional radiography at various stages of root canal treatment is based on its ability to visualise the internal root aspect. However, conventional radiography may only

demonstrate the main features and it is unlikely to show the complexities of root canal anatomy (14, 15). In addition, plain radiographs are two dimensional and are open to a wide range of interpretation as noted by Omear *et al.* (14). In Kenya, there is a scarcity of published data on root morphology in the mandibular first permanent molars. Thus, this *in-vitro* study was carried out to investigate the root morphology, configuration and number of root canals and their anatomical variations in the mandibular first permanent molars in a Kenyan population.

MATERIALS AND METHODS

This was an *in vitro*-cross sectional descriptive study which was conducted at the University of Nairobi, School of Dental Sciences. One hundred and eighty nine mandibular first permanent molars extracted from Kenyans of African descent aged between 10 and 40 years were collected in four oral health care facilities within Nairobi. The teeth were grouped into two at the collection point based on gender. The extracted teeth were washed under tap water immediately after extraction before being immersed in 3.85% *m/v* sodium hypochlorite solution (Reckitt Benckiser E.A. Nairobi, Kenya) for a minimum of thirty minutes to remove adherent soft tissue and for disinfection. Subsequently, the teeth were washed with plain water. Calculus and organic debris were removed using an ultrasonic scaler (Parkell, inc., Edgewood, USA). After evaluating the external root morphology, a standard clearing technique was applied with adapted modifications from previous studies to determine the number and types of root canal configurations (1-6).

Access cavities were prepared in the teeth using a high speed hand piece and diamond fissure burs and the coronal pulp tissues extirpated until the canal orifices. They were then immersed in 5.25% sodium hypochlorite solution (Chlorex-5, Synerchemie, Nairobi, Kenya) and agitated for 24 hours then washed in running water for two hours. This was followed by drying for 12 hours. An endodontic irrigation syringe with a 27 gauge needle (BU Kwang Medical Inc., Seoul, Korea) was used to inject Indian ink (Sanford rotring GmbH, Hamburg, Germany) into the root canal system. The root apex was then immediately connected to a central suction system, until the ink exited through the apical foramina.

After another 12 hours of drying, the teeth were decalcified in 10% nitric acid (Ridel Thaen, Germany) for five days. The acid was agitated daily and the process was monitored periodically by radiography to avoid over-decalcification. Decalcified teeth were then washed in running tap water for four hours, dried and dehydrated in ascending concentrations (70%, 95%, 100%) of ethyl alcohol (Scharlab S.L.

Sentmenat, Spain) for three days. They were then rendered transparent by immersing in methyl salicylate (RANKEMRFCL Limited Okhla-India) for six hours. The observations for the number of canals per root and canal configurations were done under a lens with a magnification power of 3X. The Vertucci (8) classification of canal configurations was taken as the main reference. The data collected were entered into a computer and analysed using the Statistical Package for Social Sciences (SPSS) 12.1 (SPSS Inc, Chicago, Illinois, USA).

RESULTS

All the mandibular first molars had two roots: a mesial and a distal. Figure 1 shows the number of canals as they exited the pulp chamber in mandibular first molars. Two canals were more frequent in mesial roots 182(96.3%) compared to the distal roots 82(42.3%) at the floor of pulp chamber. One canal was observed more frequently in the distal roots 109(57.7%) compared to mesial roots at six (3.2%). Three canals were observed in one (0.5%) of the mesial roots. The variation in the frequency of two canals between the mesial and distal roots at the floor of the pulp chamber was statistically significant ($\chi^2=131.96$, d.f 1, $P<0.05$). The frequency of two canals in the distal root was higher in females 52(53.6%) compared to males 28(30.4%). This gender variation was statistically significant ($\chi^2=10.39$, d.f. 1 and $P<0.05$).

Table 2 shows the gender variations in canal configurations in the mesial and distal roots. In general, the type IV canal configuration was more frequent in the mesial roots 165(87.3%) compared to the distal root 42(22.2%) while type II was more frequent in the distal root 95(50.3%) compared to mesial roots 15(8.2%). Figure 2 shows the canal configurations in the mesial and distal roots. Of the mesial roots with two canals, 90.2% had type IV canal configurations while all mesial roots with a single canal had type I canal configuration six (100%). Of the 109 distal roots with one canal, majority (87.2%) had type I configuration while out of 80 roots with two canals (52.5%) had type IV configuration. In the mandibular first molars, type I canal configuration was more prevalent in the distal roots while type IV was the most prevalent in the mesial roots in both males and females. In the distal roots, type I canal configuration was observed more frequently in males 59(68.6%) than in females 36(41.9%). The frequency of type II canal configuration was higher in females (31.4%) compared to males (9.3%). Type IV canal configuration was observed more frequently in females (23.7%) than in males (20.7%). The gender variation in canal configurations in the distal roots in relation to canal type I, II and IV configurations was statistically significant ($\chi^2 =16.26$, d.f. 2 and $P<0.05$).

Table 1
Anatomical variations in root canal configurations in mandibular first molars based on Vertucci classification

Investigator	Teeth	Roots	Percentages for types I-VIII							
			I	II	III	IV	V	VI	VII	VIII
Ahmed	200	M	3.0	14.0	1.0	73.0	1.0	0	1.0	2.0
<i>et al.</i> (2007) ¹		D	38.0	28.0	0	22.0	1.0	6.0	0	3.0
Gulabivala	104	M	3.8	33.7	1.9	41.4	5.8	2.9	0	0
<i>et al.</i> (2001) ³		D	60.6	15.4	2.9	13.4	3.8	2.9	0	0
Vertucci	100	M	12.0	28.0	0	51.0	8.0	0	0	1.0
<i>et al.</i> (1984) ⁸		D	70.0	15.0	0	7.0	8.0	0	0	0

Figure 1
Number of canals in mandibular first molars

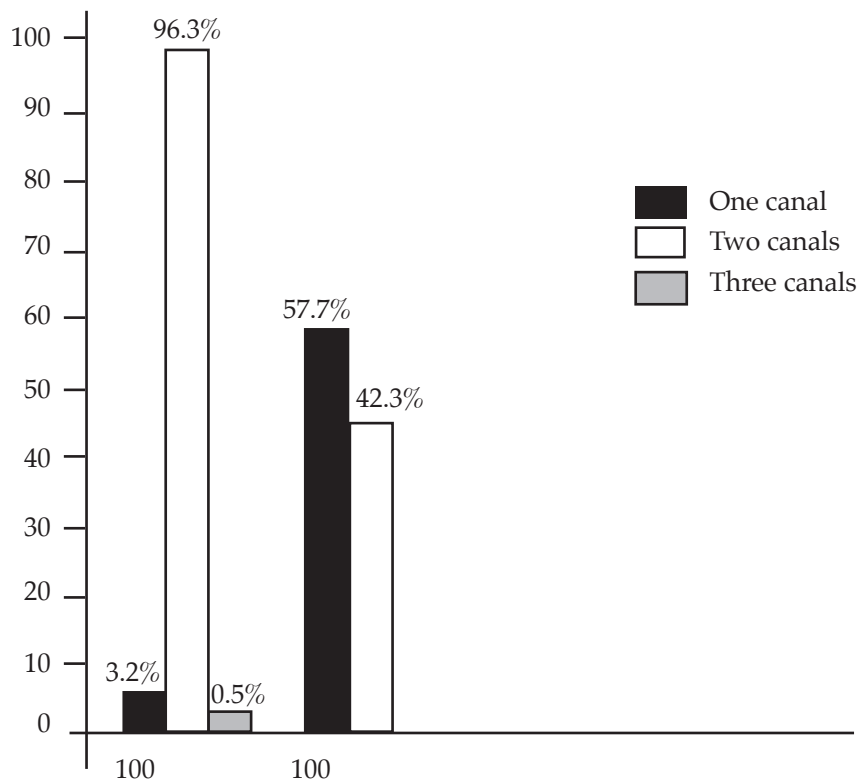



Figure 2
Canal configurations observed in mandibular first molars



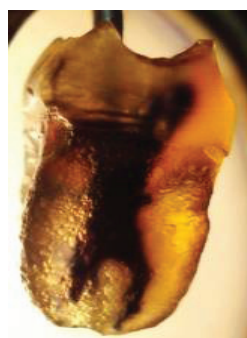
Type I



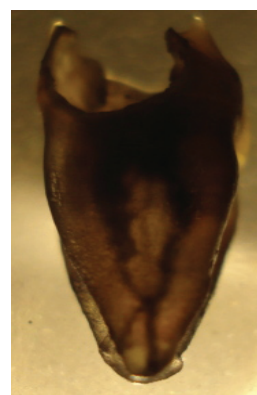
Type II



Type IV



Type V



Type VI

Table 2

Root canal configurations in mandibular first molars among males and females based on Vertucci classification.

Mandibular first permanent molars		Canals types I-VIII in percentage(%)								
Root	M-male	I	II	III	IV	V	VI	VII	VIII	Test
F-female										
Mesial root	M(n=92)	3.3	6.5	0.0	88.0	0.0	2.2	0.0	0	χ^2 =0.46 p=0.50 (II&IV)
	F(n=97)	3.1	9.3	0.0	86.6	0.0	0	0.0	1.0	
	Total(187)	3.3	7.9	0.0	87.3	0.0	1.1	0.0	0.5	
Distal root	M(n=92)	64.1	8.7	1.1	20.7	4.3	1.0	0.0	0.0	χ^2 =16.26 p<0.05 (I,II&IV)
	F(n=97)	37.1	27.8	2.1	23.7	6.2	4.1	1.0	0.0	
	Total(187)	50.3	18.5	1.6	22.2	5.3				

DISCUSSION

Most of the mandibular mesial roots had two canals while the distal roots had a single canal (96.3% for mesial and 42.3% for distal roots). Ahmed *et al.* (1) reported a lower frequency of two canals at 86% in the mandibular mesial root and a higher frequency of two canals at 59% in the distal roots among the Sudanese. The variations in the findings may be attributed to sample variations and gender proportions in the study. Study methodology together with intrapopulation variations in root morphology may explain the differences in the study findings. In this study, the frequency of two canals in the mesial roots among females was 53.6% compared to 59% reported in Sudanese population. The gender ratio in this study was approximately 1:1 while the gender ratio in the Sudanese study was unknown. The frequency of two canals in the distal roots was higher in females than in males in the current study. Sert *et al.* studied root morphology in a Turkish population and reported 88% and 22% frequencies of two canals in the mesial and distal roots respectively (17). The frequency of

two canals was low in both roots compared to this study. A study in the same population by Semih *et al.* reported 88 and 86% frequencies of two canals in the mesial roots among males and females respectively (18). Semih *et al.* also reported a higher frequency of two canals among females 26% compared to males 18% in the distal roots. The frequency of two canals in distal root among females was higher than among males in this study. The variations in frequencies between this study and those among the Turkish population may be attributed to racial variations in root morphology between Africans and Asians. However, Al-Nazhan in a clinical study among the Saudi Arabians reported 57.76% frequency of four canals in first permanent molars and observed that gender had no influence on the number of canals (19). Pattanshetti *et al.* reported no significant gender variations in the number of canals in the distal root among the Kuwaitis (20). However, Al-Nazhan and Pattanshetti *et al.* studies were different in that they were radiographic clinical studies.

Two dimensional radiographs are reported to be limited in displaying internal root morphology

as compared to the clearing technique. In addition, they are subject to a wide range of interpretations (14). Vertucci *et al.* using the clearing technique reported 71 and 20% frequencies of two canals in the mesial and distal roots respectively in a Caucasian population (8). These results are lower than the findings in this study. The differences may be attributed to the variation in sample size, gender differences or racial variations in root morphology. This study analysed 189 teeth among Africans compared to 100 teeth among Caucasians analysed by Vertucci *et al.* (8).

The frequency of three canals in the mesial roots was 0.5%. Vertucci *et al.* using a clearing technique reported a 1% frequency of three canals in the mandibular mesial roots in a Caucasian population. Semih *et al.* reported a 3% frequency of three canals in a study on mandibular mesial roots among males in a Turkish population using the clearing technique. The differences in findings between this study and studies by Vertucci *et al.* and Semih *et al.* may be attributed to racial variations in root morphology.

The canal type II and IV configurations were the most frequent in the mesial roots (7.9 and 87.3% respectively) while types I and IV were the most prevalent in the distal roots (50.3 and 22.2% respectively). Superber *et al.* reported 84 and 16% frequencies of Vertucci canal types IV and II respectively in mesial roots (21). Wasti *et al.* reported 67.7% frequency of type IV and 23.0% frequency of type II canal configuration in the mesial roots among Pakistanis (4). Vertucci *et al.* reported 43 and 28% frequencies of canal type IV and II in the mesial roots respectively in a study in a Caucasian population. The differences in the findings may be attributed to the sampling variations, sample sizes, intrapopulation differences or racial variations.

In the distal root, type I canal configuration was the most prevalent. This is in agreement with previous studies. In this study, gender had an influence on the canal configurations in the mandibular distal root. The knowledge from laboratory studies is essential in providing an insight in the complexity of root canal anatomy. The standard canal instrumentation may leave a significant proportion of the fins, webbing and branches of dividing canals unclean. Consequently, these spaces may remain unfilled and the remnant pathogenic micro-organisms may proliferate and sustain post-treatment periradicular disease (22-24).

In conclusion, majority of mandibular first molars had three canals (56%) and those of the mesial roots (96.3%) had two canals. Type IV canal configuration was the most prevalent in the mesial roots. Two canals in the distal roots were more frequent among females (53.6%) compared to males (30.4%) and canal types I, II and IV configurations were the most frequent in the distal roots.

ACKNOWLEDGEMENTS

To the dentists in the various dental clinics in Nairobi, who facilitated the collection of the extracted teeth for this study. We are also grateful to the departments of Conservative and Prosthetic Dentistry and the Oral and Maxillofacial Surgery, School of Dental Sciences, University of Nairobi where the study was conducted. The study was approved by the Ethics and research Committee of the Kenyatta National Hospital and University of Nairobi.(P219.8.2008).

REFERENCES

1. Ahmed, H. A., Abu-bakr, N. H., Yhia, N. A. and Ibrahim, Y. E. Root and root canal morphology of permanent mandibular molars in a Sudanese population. *Intern. Endodont. J.* 2007; **40**: 766-712.
2. Gulabivala, K., Opananon, A. and Ng Y-L, Alavi, A. Root and canal morphology of Thai mandibular molars. *Intern. Endodont. J.* 2002; **35**: 56-62.
3. Gulabivala, K., Aung, Y. H., Alavi, A. and Ng Y-L. Root and canal morphology of Burmese mandibular molars. *Intern. Endodont. J.* 2001; **34**: 359-370.
4. Wasti, F., Shearer, A. C. and Wilson, N. H. Root canal systems of the mandibular and maxillary first permanent molar teeth of South Asian Pakistanis. *Intern. Endodont. J.* 2001; **34**: 263-266.
5. DE Moor, R. J., Deroose, C. A. and Calberson, F. L. The radix entomolaris in mandibular first molars: an endodontic challenge. *Intern. Endodont. J.* 2004; **37**: 789-799.
6. Rwenyonyi, C. M., Kutesa, A. M., Muwazi, L. M. and Buwembo, W. Root and canal morphology of maxillary first and second permanent molar teeth in a Ugandan population. *Intern. Endodont. J.* 2007; **4**: 679-683.
7. Vertucci, F. J. Root canal morphology and its relationship to endodontic procedures. *Endodont. Topics.* 2005; **10**: 3-29.
8. Vertucci, F. J. Root canal anatomy of the human permanent teeth, Oral Surgery and Oral Medicine, Oral pathology, Oral Radiology. *Intern. Endodont. J.* 1984; **58**: 589-599.
9. Frank, J., Vertucci, James, E. and Haddix, Leandro, R. B. Tooth Morphology and Access Cavity Preparation in Pathways of the Pulp, Ninth Edition Elsevier Mosby 2006; 148 -232.
10. Baratto-Filho, F., Fariniuk, L. F., Femeira, F. L., Percora, J. D., Cruz - Filho, A. U. and Sousa-Neto, M. D. Clinical and microscopic study of maxillary molars with two palatal roots. *Intern. Endodont. J.* 2002; **35**: 796-801.
11. Evangelos, G., Kontakiotis, Giorgos, N. and Tzanetakis. Four canals in the mesial root of a mandibular first molar. A case report under the operating microscope. *Austral. Endodont. J.* 2007; **33**: 84-88.
12. Fernando, B. B., Sidney, R. D., Magda de, S. R., Ronise, F. and Rosana, M. C. T. Mandibular molar with five root canals. *Austral. Endodont. J.* 2008; **34**: 129-132.
13. Pecora, J. D., Woelfel, J. B. and Sousa, N. Morphologic study of the maxillary molars part I: External Anatomy. *Brazilian Dental Journal.* 1991; **2**: 45-50.
14. Omer, O. E., Al Shalabi, R. M., Jennings, M., *et al.* A comparison between clearing and radiographic

- techniques in the study of the root-canal anatomy of maxillary first and second molars. *Intern. Endodont. J.* 2004; **37**: 291-296.
15. Insoo k, Ki-suk, P. and seung-pyo, L. Quantitative Evaluation of the Accuracy of Micro-Computed Tomography in Tooth Measurement. *Clinical anatomy.* 2007; **20**: 27-34.
 16. Ngassapa, D., Hassanali, J., Amwayi, P. and Guthua. S. Essentials of Orofacial Anatomy. Dar es Salaam: Dar es Salaam University Press 1996 pp 98-129.
 17. Sert, S. V. and Aslanalp, Tanalp, J. Investigation of the root canal configuration of mandibular permanent teeth in the Turkish population. *Intern. Endodont. J.* 2004; **37**: 494-499.
 18. Semih, S. and Gunduz, B. G. Evaluation of the root canal configurations of the mandibular and maxillary permanent teeth by gender in the Turkish Population. *J. Endodont.* 2004; **30**: 391-398.
 19. Al-Nazhans. Incidence of four canals in root-canal treated mandibular first molar in a Saudi Arabian sub-population. *Intern. Endodont. J.* 1999; **32**: 49-52.
 20. Pattanshetti, N., Gaidhane, M. and Al Kandari, A. M. Root and canal morphology of the mesiobuccal and distal roots of permanent first molars in a Kuwait population a clinical study. *Intern. Endodont. J.* 2008; **41**: 755-762.
 21. Sperber, G. H. and Moreau, J. L. Study of the number of roots and canals in Senegalese first permanent mandibular molars. *Intern. Endodont. J.* 1998; **31**: 117-122.
 22. Marcus, T. The management of periapical lesions in endodontically treated teeth. *Austr. Endodont. J.* 2006; **32**: 2-15.
 23. Reham. M., Ameen and Rania M. Hassan. A study on the External and Internal Root Anatomy of Egyptian Maxillary First Permanent Molar; *Cairo Dent. J.* 2008; **29**: 36.
 24. Giuseppe, C., Elio, B. and Arnaldo, C. Missed anatomy: Frequency and clinical impact. *Endodont. Topics* 2009; **15**: 3-31.