



## Original Article

# Laparoscopic repair of penetrating injury of the diaphragm: an experience from a district hospital

Ali Yahya<sup>1</sup>, Hussein Shuweiref<sup>1</sup>, Ahmed Thoboot<sup>1</sup>, Mustafa Ekheil<sup>1</sup>, and Abdulmajid A Ali<sup>2</sup>

<sup>1</sup>Department of Surgery, Zliten Central Hospital, Zliten-Libya, and <sup>2</sup>Department of Laproscopic Surgery, AyrShire & Arran Hospital's NHS Trust-Scotland

*Received for publication on 18 October 2007. Accepted in revised form 08 January 2008*

**Key words:** Diaphragmatic injury; Trauma; Laparoscopic surgery.

### ABSTRACT

In this study we review our experience in using laparoscopy as a diagnostic and therapeutic tool in dealing with penetrating diaphragmatic injuries due to stab wounds and look at the feasibility of using this procedure in other similar institutions.

Thirty patients, all of whom were males 20-30 years of age, presented to the surgical emergency unit of our hospital with upper abdominal and lower chest wall stab wounds between 01-05-1998 and 30-11-2006. Diagnosis of the diaphragm injury was either obvious with omentum herniating through the chest wall, or occult with confirmation of the injury at laparoscopy.

All patients underwent diagnostic laparoscopy, which resulted in identification and efficient treatment of eight patients with diaphragmatic injury, and thereby laparotomy was avoided. The procedure converted to open surgery in one patient because of a small left-sided colonic tear.

Laparoscopy is an efficient tool for the diagnosis and management of diaphragmatic injuries. It should be used routinely instead of exploratory laparotomy in haemodynamically stable patients with penetrating lower chest injuries.

### INTRODUCTION

Traumatic rupture of the diaphragm is a diagnostic dilemma, requiring a high index of suspicion particularly in blunt trauma.

Failure to diagnose traumatic rupture of the diaphragm can result in the development of a diaphragmatic hernia with significant morbidity and mortality [1]. Since the introduction of diagnostic and therapeutic laparoscopy in our unit, the diagnostic dilemma has become less challenging.

Since 1998 we have been using diagnostic and therapeutic laparoscopy in both blunt and penetrating abdominal injuries in our unit. A total of 96 diagnostic and therapeutic laparoscopies and 4 diagnostic thoracoscopies were performed for patients with blunt or penetrating trauma over a period of eight

years. The aim of this study was to evaluate our experience in using laparoscopy as a diagnostic and therapeutic tool in dealing with penetrating diaphragmatic injuries due to stab wounds and assess its suitability in other similar institutions.

### MATERIALS AND METHODS

This is a retrospective study of all the patients who presented to Zliten central hospital with upper abdominal and lower chest wall stab wounds between 01-05-1998 and 30-11-2006. All patients were males aged 20-30 years. Eight patients had been stabbed in the lower left side of the chest wall with injury to the diaphragm confirmed by laparoscopy, four had stab wounds in the right side of the chest wall, 14 had the stab wounds in the anterior aspect of the abdomen, and four had the stab wounds in their backs.

All the patients had been resuscitated according to the Advanced Trauma and Life support standards at the Accident and Emergency Department before admission to the surgical ward. Routine investigations were carried out, including full blood count, urea, electrolytes, blood group and chest X-ray. All patients had an abdominal ultrasound examination to rule out solid organ injury and all were haemodynamically stable before the laparoscopy. All patients received adequate analgesia and those with stab wounds in the lower part of the chest had intercostal chest drain inserted on admission to the Accident and Emergency Department.

Three patients had clear pneumothorax, four had omentum protruding through the wound, and eight were suspected of having diaphragmatic injury because chest x-ray showed obliteration of the costophrenic angle on the left side, indicating fluid collection in the chest.

All 30 patients underwent diagnostic laparoscopy under general anesthesia to identify the pattern of injury. Port position is demonstrated in Figure 1. Pneumoperitoneum was created using the closed method (Veress Needle). The stab wounds were stitched or towel-clipped before introducing pneumoperitoneum. All intra-abdominal organs and bowels were examined carefully for any signs of injury. Air was pushed into the stomach and the bowels were observed for any gas bubbles indicating bowel injury. The fluid in the abdomen was sucked out and inspected for color. In the three patients in whom omentum was protruding externally, it was excised and the remaining omentum was pulled from inside by laparoscopic forceps. Air leak was demonstrated in the chest drain bottle in eight patients after introducing pneumoperitoneum, indicating diaphragmatic injury.

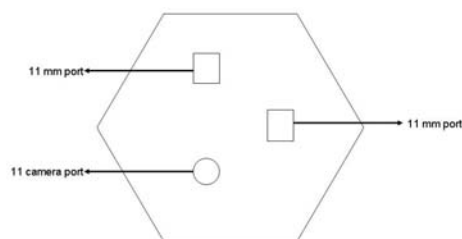


Figure 1: Port position of the diagnostic laparoscopy of traumatic diaphragmatic injuries.

Prolene round needle (2/0) was used to suture the defects in the diaphragm. Intra-abdominal drain was inserted routinely for 24 hours. The chest drain was inserted before laparoscopy, kept in position following the procedure, and then removed when the lung was fully expanded. All patients were completely stable throughout the procedure. The average operating time was 90 minutes.

## RESULT

The intra-operative findings in eight patients with stab wounds in left lower chest wall were as follows:

One patient had stomach perforation as well as diaphragmatic perforation of about 4 cm in the middle of the left dome of the diaphragm. The stomach perforation was diagnosed by careful examination and the use of air injected through a naso-gastric tube. Both perforations were repaired laparoscopically. The patient developed left-sided pleural effusion, but it resolved completely with conservative management and the patient was discharged on the seventh post-operative day.

Another patient had a stab wound in the left side of his chest and part of omentum was protruding through the wound. Laparoscopic examination demonstrated a penetrating wound in the left side of the diaphragm and a small left-sided colonic tear. The procedure was converted to open laparotomy with targeted incision. The diaphragmatic and colonic perforations were repaired and the patient was discharged on the fifth postoperative day.

Two patients had diaphragmatic perforation and small laceration in the spleen. The diaphragmatic perforation was repaired laparoscopically. The splenic laceration was minor and superficial and did not require any surgical intervention. Both patients were discharged on the third postoperative day.

Four patients had diaphragmatic perforation but no other associated intra-abdominal injuries. The diaphragmatic injuries were repaired laparoscopically and the patients were discharged on the third postoperative day.

## DISCUSSION

In our unit, 96 diagnostic and therapeutic laparoscopies and four diagnostic thorascopies were carried out for patients with both blunt and penetrating trauma over a period of eight years.

Thirty patients with penetrating stab wounds underwent diagnostic laparoscopy, which led to identification and efficient treatment of eight patients with diaphragmatic injury, and thereby non therapeutic laparotomy was avoided.

Before the introduction of laparoscopy in our institution, exploratory laparotomy was the normal practice in penetrating abdominal injuries [1]. The argument was that even if there are no clinical signs of intra abdominal injuries, the disadvantages of unnecessary laparotomy are minor compared to the danger of peritonitis resulting from delayed diagnosis of intestinal perforation. Furthermore, diaphragmatic injuries represent a diagnostic challenge to the most experienced surgeon. If diaphragmatic injuries are suspected, performing exploratory laparotomy on those patients usually results in delayed hospital discharge, increased need for analgesia, long scars, and possible long-term complications, such as adhesions and incisional hernias.

The use of diagnostic laparoscopy in trauma patients is a developing field that has the advantage of allowing the inspection of the peritoneum for signs of perforation and treating associated intra-abdominal injuries if they exist [2,3]. Moreover, incisions are smaller, which means that there is less pain, and recovery time and postoperative hospital stays are shorter [4]. When performed in carefully selected haemodynamically stable patients, laparoscopy is safe, technically feasible, and has been reported to reduce unneeded and non therapeutic laparotomy rates in this type of patient population [5].

Although laparoscopy is considered an increasingly useful tool in trauma patients, it is not widely practiced in developing countries, where trauma is on the rise. The absence of the experience required to safely perform this procedure made most surgeons feel technically uncomfortable with this approach. However, our experience demonstrated that laparoscopy is an effective tool for the diagnosis and management of diaphragmatic injuries [6-9]. We conclude that laparoscopy should be used routinely instead of exploratory laparotomy in haemodynamically stable patients with penetrating lower chest injuries.

Laparoscopy training should be an essential part of basic surgical training in hospitals dealing with trauma.

---

#### CORRESPONDING AUTHOR:

Dr Ali Yahya, e-mail: Aliyahya60@hotmail.com

---

#### REFERENCES

1. Ferrada R, Birolini D. New concepts in the management of patients with penetrating abdominal Wounds. *Surg Clin North Am.* 1999; 79(6):1331-56.
2. Sosa JL, Arrillaga A, Puente I, Sleeman D, Ginzburg E, Martin L. Laparoscopy in 121 consecutive patients with abdominal gunshot wounds. *J Trauma.* 1995; 39:501-506.
3. Zantut LF, Ivatury RR, Smith RS, Kawahara NT, Porter JM, Fry WR, Poggetti R, Birolini D, Organ CH Jr. Diagnostic and therapeutic laparoscopy for penetrating abdominal trauma: a multicenter experience. *J Trauma.* 1997; 42(5):825-9; discussion 829-31.
4. Cherkasov M, Sitnikov V, Sarkisyan B, Degtirov O, Turbin M, Yakuba A. Laparoscopy versus laparotomy in management of abdominal trauma. *Surg Endosc.* 2008; 22(1):228-31.
5. Dapri G, Himpens J, Lipski D, et al. Role of laparoscopy in the management of visceral injuries following abdominal stab wounds. *J Laparoendosc Adv Surg Tech A.* 2007; 17(6):713-8
6. Weinberg JA, Magnotti LJ, Edwards NM, Claridge JA, Minard G, Fabian TC, Croce MA. "Awake" laparoscopy for the evaluation of equivocal penetrating abdominal wounds. *Injury.* 2007; 38(1):60-4.
7. Mintz Y, Easter DW, Izhar U, Edden Y, Talamini MA, Rivkind AI. Minimally invasive procedures for diagnosis of traumatic right diaphragmatic tears: a method for correct diagnosis in selected patients. *Am Surg.* 2007; 73(4):388-92.
8. Baldassarre E, Valenti G, Gambino M, Arturi A, Torino G, Porta IP, Barone M. The role of laparoscopy in the diagnosis and the treatment of missed diaphragmatic hernia after penetrating trauma. *J Laparoendosc Adv Surg Tech A.* 2007; 17(3):302-6.
9. Cui H, Luckerth P, Peralta R. Laparoscopic management of penetrating liver trauma: a safe intervention for hemostasis. *J Laparoendosc Adv Surg Tech A.* 2007; 17(2):219-22.

**To cite this article:** Ali Yahya, Hussein Shuweiref, Ahmed Thoboot, Mustafa Ekheil, Abdulmajid A Ali. Laparoscopic repair of penetrating injury of the diaphragm: an experience from a district hospital. *Libyan J Med, AOP: 080322.*