

# Visual Outcomes after Phacoemulsification with AcrySof Toric Intraocular Lens Implantation

Jaya Kaushik<sup>1,2</sup>, Vaibhav K. Jain<sup>3</sup>, Jitendra K.S. Parihar<sup>4</sup>, Piyush Chaturvedi<sup>5</sup>, Vijay Mathur<sup>2</sup>, Sanjay K. Dhar<sup>5</sup>

<sup>1</sup>Department of Ophthalmology, Military Hospital, Pathankot, Punjab, <sup>2</sup>Department of Ophthalmology, Command Hospital, Chandimandir, Panchkula, Haryana,

<sup>3</sup>Department of Ophthalmology, Uttar Pradesh University of Medical Sciences, Saifai, Etawah, Uttar Pradesh, <sup>4</sup>Department of Ophthalmology, Army Hospital Research and Referral, New Delhi, India, <sup>5</sup>Command Hospital, Pune, India

## Abstract

**Introduction:** To study the visual outcome of AcrySof toric intraocular lens (IOL) implantation in patients having cataract associated with astigmatism. **Materials and Methods:** In this prospective interventional case series, 30 eyes of 28 patients with preoperative astigmatism of 1.5–4.5 D cylinder underwent phacoemulsification with AcrySof toric IOL implantation. All patients were assessed on day 1, 1 week, 1 month, 2 months, and 3 months postoperatively. The outcome measures were uncorrected visual acuity (UCVA), refractive cylinder, and degree of IOL rotation. **Results:** Mean UCVA improved significantly in study eyes ( $P < 0.05$ ) at 3 months. The mean refractive astigmatism reduced from the preoperative value  $3.05 \pm 0.06$  D to  $0.208 \pm 0.058$  D ( $P = 0.001$ ). The mean axis of rotation was  $2.76 \pm 1.88^\circ$  in all eyes. Ninety percent of all eyes had mean axis of IOL rotation  $10^\circ$ . Only three eyes had mean axis of rotation  $10^\circ$  or more. **Conclusion:** AcrySof toric IOL implantation is an effective method to correct preoperative astigmatism in cataract patients.

**Keywords:** Acrysof toric IOL, astigmatism, toric IOL, visual outcome

## INTRODUCTION

An increasing goal of modern cataract surgery is to make patient spectacle independent. Myopia and hyperopia can be corrected by implanting a suitable intraocular lens (IOL) and decrease the chances of spectacle dependence in these patients postoperatively.<sup>[1]</sup> Astigmatism is a frequent cause of poor uncorrected visual acuity (UCVA) post-cataract surgery. Astigmatism after cataract surgery causes significant visual blur and asthenopic symptoms, so it becomes imperative to reduce the pre-existing astigmatism. The focus of modern cataract surgery has now shifted toward eliminating the pre-existing astigmatism.<sup>[2,3]</sup> Various measures namely small incisions,<sup>[4,5]</sup> arcuate keratotomy,<sup>[6]</sup> limbal relaxing incisions,<sup>[7]</sup> excimer laser,<sup>[8]</sup> and opposite clear corneal incision<sup>[9]</sup> to reduce postoperative astigmatism have been described in the literature.

Toric IOL implantation offers a good, predictable, and stable method of correcting preoperative astigmatism. Several studies have published the successful visual and refractive outcomes after the implantation of different types of toric IOL.<sup>[10-17]</sup> In our case series, we report the various outcome

measures in patients undergoing phacoemulsification with AcrySof toric IOL implantation. We also analyzed the mean corneal incision axis and mean axis of IOL placement, which have been reported rarely.

## MATERIALS AND METHODS

This prospective interventional study was conducted at a tertiary level referral hospital from March 2012 to August 2013. In this study, 30 eyes of 28 patients of age group between 50 and 80 years were operated by a single surgeon (JK) using topical anesthesia. All patients were provided informed written consent to enroll for the study. Ethical clearance of hospital ethical committee was obtained prior to initiating the study. The study was conducted as per the guidelines laid down by Declaration of Helinski.

**Address for correspondence:** Dr. Jaya Kaushik, MS,  
Department of Ophthalmology, Command Hospital, Chandimandir,  
Panchkula, Haryana, India.  
E-mail: arnavjaya@gmail.com

This is an open access article distributed under the terms of the Creative Commons Attribution-NonCommercial-ShareAlike 3.0 License, which allows others to remix, tweak, and build upon the work noncommercially, as long as the author is credited and the new creations are licensed under the identical terms.

**For reprints contact:** reprints@medknow.com

**How to cite this article:** Kaushik J, Jain VK, Parihar JK, Chaturvedi P, Mathur V, Dhar SK. Visual outcomes after phacoemulsification with AcrySof toric intraocular lens implantation. Niger J Ophthalmol 2016;24:62-6.

### Access this article online

#### Quick Response Code:



#### Website:

[www.nigerianjournalofophthalmology.com](http://www.nigerianjournalofophthalmology.com)

#### DOI:

10.4103/0189-9171.195196

Patients aged between 50 and 80 years with senile cataract grade II to IV nuclear or corticonuclear (LOCS III), with pre-existing regular corneal astigmatism of equal or more than 1.50 D up to 4.5 D, with no other ocular disease, and willing for follow-up for 3 months were enrolled in study. Patients with corneal astigmatism <1.5 D and >4.5 D, irregular astigmatism, corneal infection, and opacities, and any previous ocular surgery were excluded from the study. Preoperative evaluation included refraction, slit lamp examination, keratometry, and fundus examination. IOL power calculation was done with ultrasound A scan. Correct toric IOL model, spherical equivalent power, and optimal axis of placement were determined using online toric IOL calculator ([www.acrysoftoriccalculator.com](http://www.acrysoftoriccalculator.com)) after considering personalized surgically induced astigmatism (SIA).

### Marking of axis of incision and intraocular lens placement

The axis was marked on the cornea with a reference marker with patient sitting in upright position at the slit lamp to prevent cyclotorsion in the supine position which may vary from 2° to 4° on an average. The coaxial thin slit of slit lamp turned to 0°–180°. The limbus was marked at horizontal position with sterile ink pen. Intraoperatively, the preoperative horizontal marks are used to position an angular graduation instrument. The actual alignment axis was marked using a toric axis marker.

### Surgical technique

Phacoemulsification surgery using 2.8 mm clear corneal incision based on axis of incision calculated by online toric IOL power calculator between 90° and 180° meridian without adjusting for the steep meridian was performed in all cases by a single surgeon. The capsulorrhexis was fashioned in a manner so as to achieve a diameter between 5.0 and 5.5 mm. After the phacoemulsification was completed and the ophthalmic viscosurgical device is injected, the single piece hydrophobic acrylic toric IOL (AcrySof, Toric IOL, Alcon Laboratories, Fort Worth, TX) was used in all the cases. The marks on the toric IOL indicating the flat meridian or plus cylinder axis of the toric IOL were identified and aligned with the marked alignment axis. First, gross alignment was achieved by rotating the IOL clockwise while it is unfolding, until approximately 20°–30° short of the desired position. Once the ophthalmic viscosurgical device is being removed, the IOL was rotated to its final position by exact alignment of the reference marks on the toric IOL with the limbal axis marks.

### Postoperative assessment

In the postoperative period uncorrected and best-corrected visual acuity were assessed at 1, 4, 8, and 12 weeks. IOL rotation, if any, was noted and the amount of off axis rotation was assessed. The number of cases requiring secondary intraocular surgery for realignment of IOL and other

complications if any was recorded. Postoperatively, all the patients were treated with topical steroid and antibiotic eye drops for 4–6 weeks. Proper documentation of all the findings in the study was prepared.

### Statistical analysis

The data were subjected to statistical analysis. Statistical analysis was performed using the Statistical Package for the Social Sciences (SPSS) for Windows software (version 16.0, SPSS, Inc., Chicago, IL, USA). Paired *t* test was used to compare the postoperative parameters with preoperative parameters.

## RESULTS

The mean ( $\pm$  standard deviation (SD)) age of all patients was 58.80 ( $\pm$ 6.65) years with range of 50–75 years. Two cases had bilateral cataract and rest 28 patients had unilateral involvement. Various preoperative characteristics of patients are shown in Table 1.

### Visual acuity

The mean UCVA improved significantly from preoperative 0.79  $\pm$  0.1 (logMAR) to 0.05  $\pm$  0.06 postoperatively at 3 months. All patients achieved 20/40 or better UCVA at 3 months after the surgery, in which 60% ( $n = 18$ ) of eyes were able to see 20/40, while 40% ( $n = 12$ ) achieved 20/20.

### Astigmatism

Pre- and postoperative corneal and refractive astigmatism were assessed. Astigmatism induced by the incision was less than or equal to 0.50 D in all cases. No statistical difference was observed between pre- and postoperative corneal astigmatism. The change in average K for the complete study is 0.367  $\pm$  0.0317 (0.302–0.431) which was not significant ( $P = 0.269$ ).

Mean final refractive astigmatism for the study at 12 weeks post-op was  $-0.208 \pm 0.058$  ( $-0.327$  to  $-0.089$ ) [Table 2]. There was a mean reduction of  $-2.832 \pm 0.073$  D ( $-3.055$  to  $-2.61$ ) from preoperative value of  $-3.04 \pm 0.059$  D ( $-3.161$  to  $-2.92$ ) to postoperative value of  $-0.208 \pm 0.058$  D ( $-0.327$  to  $-0.089$ ) at 12 weeks, which was of high statistical

**Table 1: Preoperative characteristics of study subjects**

Demographics	Value
Number of patients (eyes)	28 (30)
Mean age: years $\pm$ SD; range	58.80 $\pm$ 6.65; 50–75 years
Sex males/females	18/10
Unilateral/bilateral	26/2
Uncorrected visual acuity (UCVA) mean $\pm$ SD	0.79 $\pm$ 0.1
Mean refractive astigmatism (cylinder)	3.04 $\pm$ 0.06 D
Mean site of corneal incision axis (°)	103.33 $\pm$ 4.40
Mean axis of IOL placement (°)	88.73 $\pm$ 9.51
Mean IOL power (sphere); range	20.51 $\pm$ 4.68 D; 13–26 D
Mean IOL power (cylinder); range	2.12 $\pm$ 0.91 D; 1.5–4.5 D

**Table 2: Postoperative parameters in study eyes at 3 months**

UCVA logMAR (±SD)	Mean refractive astigmatism D (±SD)	Mean axis of rotation (°)	Eyes with 20/20 or better (%)	Eyes with 20/40 or better (%)
0.05 ± 0.06	0.208 ± 0.058	2.76 ± 1.88	40	100

UCVA = uncorrected visual acuity, SD = standard deviation

significance ( $P \ll 0.005$ ) [Figure 1]. A significant change of  $-2.415 \text{ D} \pm 0.123$  ( $-2.791$  to  $-2.04$ ) in refractive astigmatism was observed at the end of 1<sup>st</sup> week following surgery and toric IOL implantation, which was highly significant ( $P \ll 0.005$ ); during further follow-up, no significant change among the groups was observed. After 8<sup>th</sup> week refractive power of eye was stationary in all the patients.

### Incision location

Incision axis of the 30 eyes ranged from 70° to 160°. We observed incisions axis at various locations such as 70° ( $n = 1$ ), 75° ( $n = 1$ ), 80° ( $n = 6$ ), 90° ( $n = 7$ ), 110° ( $n = 7$ ), 120° ( $n = 2$ ), 130° ( $n = 2$ ), 135° ( $n = 1$ ), 140° ( $n = 2$ ), and 160° ( $n = 1$ ). The mean incision axis for the study was  $103.33 \pm 4.397^\circ$  ( $94.34$ – $112.33$ ). The incision size in all cases remained 2.8 mm.

### Intraocular lens axis placement in capsular bag

Intraoperative IOL axis placement in the capsular bag depends on axis of horizontal and vertical keratometric values (K1 and K2) which neutralize the cylinder value at corneal plane, so every patient’s IOL axis placement will depend on its K1 and K2 axes and will be different in each case. In our study, we noticed that IOL placement axis values were found to be between 0° (i.e., 180°) and 165° with mean placement axis of  $88.73 \pm 9.51^\circ$  ( $69.29$ – $108.17$ ).

### Rotational stability

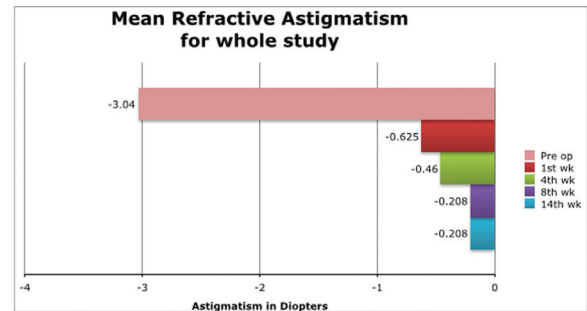
The IOL rotation was assessed under slit lamp with rotating slit in dilated pupil. Mean rotation of the study eyes was  $2.76 \pm 1.88^\circ$ . Patients were observed for an average of 12-week duration, and 90% of all IOLs remained stable within 10° of the target axis. In 10% of eyes ( $n = 3$  of 30), an IOL rotation of about 10° or more occurred. In two of these three eyes, we did not rotate the IOL because the patient was satisfied despite residual astigmatism. Another eye with residual astigmatism, further rotation was performed 4 weeks postoperatively which was successful.

### Complications

No significant intraoperative complication was noticed in any of the study eye.

### DISCUSSION

Though implantation of toric IOL has gained the importance in patients with cataract associated with corneal astigmatism, this procedure is not without many issues such as poor visual gain, rotational instability, residual refractive error, and



**Figure 1:** Mean refractive astigmatism in study population at various follow-up visits (preoperative, 1, 4, 8, and 12 weeks). cyl = cylinder; , D = diopter

myopic shift. This study reported the various outcome measures namely UCVA, corneal astigmatism, refractive astigmatism, axis of corneal incision, axis of IOL placement, and rotation instability.

The mean UCVA improved significantly in patients after phacoemulsification with toric IOL implantation. In this study, all patients were able to see 20/40 or better unaided out of which 60% ( $n = 18$ ) of eyes were able to see 20/40 unaided after 12-week post-op follow-up, while 40% ( $n = 12$ ) achieved 20/20 unaided. Bauer *et al.*,<sup>[18]</sup> in a case series of 53 eyes of 43 patients reported more than 90% of patients with UCVA of 20/40 or better and 80% achieved UCVA of 20/25 or better with AcrySof toric IOL implantation. Kim *et al.*,<sup>[19]</sup> in their case series of 30 eyes of 24 patients reported 73.3% patients with UCVA of 20/25 or better after AcrySof toric IOL implantation. The mean logMAR UCVA of 0.081 was reported in a series of 64 eyes of 40 patients after cataract surgery with AcrySof toric IOL implantation by Farooqui *et al.*<sup>[20]</sup> Our results compared favorably with previous studies and demonstrate good postoperative vision and likely spectacle independence for distance tasks.

The mean baseline cylinder for our study group was  $-3.04 \pm 0.059 \text{ D}$ , which was reduced to  $0.208 \pm 0.058 \text{ D}$  after AcrySof toric IOL implantation. We observed a significant improvement in postoperative refractive astigmatism in study eyes. Postoperative refractive cylinder in study eyes was reduced significantly; therefore, a reduction in refractive cylinder by using the AcrySof toric IOL was more likely to result in full spectacle independence for distance vision in patients with low to moderate degrees of corneal astigmatism. A similar trend in postoperative astigmatism  $0.28 \pm 0.38 \text{ D}$  is reported by Kim *et al.*, in their study.<sup>[19]</sup> In a randomized controlled trial, postoperative astigmatism was  $0.36 \pm 0.44 \text{ D}$  in low astigmatism group ( $< 2.25 \text{ D}$ ),  $0.31 \pm 0.46 \text{ D}$  in moderate to high toric group ( $3.00$ – $6.00 \text{ D}$ ).<sup>[21]</sup> AcrySof

toric IOL has been proven as a superior IOL in terms of postoperative refractive cylinder and spectacle freedom in a randomized, subject-masked 1 year study.<sup>[13]</sup> This randomized clinical trial by Holland *et al.*, included 517 patients: 256 patients received unilateral implantation of an AcrySof toric IOL (T3, T4 or T5) and 261 patients received unilateral implantation of spherical control IOL.<sup>[13]</sup> One year postoperatively, significantly more patients in the toric group achieved an UCVA of 20/40 or better compared to the control group: 92% versus 81% of patients, respectively. Furthermore, an UCVA of 20/20 or better was achieved in significantly more patients with a toric IOL compared to a control IOL (41% versus 19% of patients). As expected, the corrected distance visual acuity results in both groups were comparable: 93% of toric and 90% of control patients achieved a corrected visual acuity of 20/25 or better. Toric IOLs are further found to be superior in terms of astigmatism control in systematic review and meta-analysis by Kessel *et al.*<sup>[22]</sup>

Astigmatism induced by the incision was less than or equal to 0.50 D in all cases. The postoperative cylinder showed that the vast majority of patients require 1 D of postoperative cylinder. Preoperatively, 100% of patients had more than 1.5 D astigmatism, compared with two patients having residual of more than 1.25 D postoperatively. We summarize that toric IOLs may reduce refractive astigmatism to less than 0.25 D. However residual keratometric astigmatism was linked with the reduction in the corneal astigmatism due to effect of clear corneal incision on keratometric changes which has been invariably varying from 0.5 to 1 D cyl. It is worth considering that despite very less change in corneal astigmatism (as detected by the insignificant post-op change in average K), toric IOL neutralizes refractive astigmatism substantially due to toric component added in IOL.

Crucial to the efficacy of toric IOLs is an exact alignment of the toric IOL at the calculated alignment axis and rotational stability. Accurate marking of the alignment axis should be performed with the patient in an upright position to prevent cyclotorsion in the supine position. Most clinical studies on toric IOLs describe using a 3-step marking procedure for toric IOL implantation. The first step consists of preoperative limbal marking of the horizontal axis of the eye with the patient sitting upright to correct for cyclotorsion. This may be done with the patient seated at the slit lamp and with a coaxial thin slit turned to 0°–180°.<sup>[23-25]</sup> The limbus is then marked at the horizontal position with either a sterile ink pen or a needle. Another technique to mark the horizontal axis is by using a bubble-marker.

The correct toric alignment is always with the steepest meridian of the postoperative cornea, because the reference marks on the IOL are always on the lowest power meridian. Any deviation from aligning the lowest power meridian of the IOL with the steepest axis of the cornea will result in greater amounts of residual astigmatism. Predicting this axis with the cross-cylinder solution of the SIA and original corneal astigmatism before the cataract incision is very accurate provided the original corneal astigmatism is regular and the

magnitude and location of the SIA induced from the incision are precise. Because the SIA is on the order of 0.5 D or less in most small-incision surgery, the change in the axis of astigmatism will be more with lower amounts of original astigmatism than in more astigmatic corneas. Patients with 1.00 D of original corneal astigmatism will have more change in the resulting cross cylinder magnitude and axis from 0.50 D of SIA than 2.00 D of original corneal astigmatism. At 3 months postoperatively, 90% of all IOLs remained stable within 10° of the target axis. In 10% of eyes (3 eyes), an IOL rotation of about 10° or more occurred. In two of these three eyes, the IOL redialing was not performed, as the patients were satisfied and unwilling for further surgical intervention. The mean IOL rotation was  $2.76 \pm 1.88^\circ$  and it was comparable to the mean rotation observed in previous studies.<sup>[24,25]</sup> Mendicutte *et al.* demonstrated the mean rotation of  $3.63 \pm 3.11^\circ$  with rotation of <10° in 96.7% of eyes in their series of 30 eyes with AcrySof toric IOL implantation.<sup>[23]</sup> All eyes experienced the rotation of 10° or less with the mean axis rotation of  $1.75 \pm 2.93^\circ$  in a series of 21 eyes with toric IOL implantation.<sup>[24]</sup> Postoperative assessment of toric IOL alignment can be achieved by several methods. The most commonly used method in the clinic is assessment using a slit lamp with rotating slit. Since the IOL marks are located at the periphery of the IOL optic, full mydriasis of the pupil is required. In our study we confirmed optical alignment by seeing clinically the axis marks on IOL periphery on slit lamp after full pupillary dilation.

This study had various limitations such as small sample size, shorter follow-up, absence of randomization, and sample size calculation. Prospective nature and strict follow-up were the strength of the study. No patient was lost to follow-up. This study showed that the AcrySof toric IOL implantation is an effective, safe, and predictable method of correcting astigmatism in cataract surgery. Proper patient selection, surgical technique, and biometry are the key factors determining the success of toric IOL implantation.

## Acknowledgements

Authors wish to express their sincere gratitude to the Office of Directorate General, Armed Forces Medical Services and Armed Forces Medical Research Committee (AFMRC) for the grant sanctioned by Government of India under the aegis of AFMRC.

## Financial support and sponsorship

Grants were sanctioned from Raksha Mantralaya, Karyalaya Mahanideshak, Sashatra Sena Chikitsa Seva, Government of India.

## Conflicts of interest

There are no conflicts of interest.

## REFERENCES

1. Kershner RM. Clear corneal cataract surgery and the correction of myopia, hyperopia, and astigmatism. *Ophthalmology* 1997;104:381-9.

2. Yao K, Tang X, Ye P. Corneal astigmatism, high order aberrations, and optical quality after cataract surgery: Microincision versus small incision. *J Refract Surg* 2006;22:S1079-82.
3. Cavallini GM, Campi L, Masini C, Pelloni S, Pupino A. Bimanual microphacoemulsification versus coaxial miniphacoemulsification: Prospective study. *J Cataract Refract Surg* 2007;33:387-92.
4. Kohnen T, Dick B, Jacobi KW. Comparison of the induced astigmatism after temporal clear corneal tunnel incisions of different sizes. *J Cataract Refract Surg* 1995;21:417-24.
5. Jain VK, Khokhar S, Agarwal A, Vanathi M, Kaushik J, Ram J. Microincision versus standard corneal incision phacoemulsification: Visual outcome. *Optom Vis Sci* 2015;92:796-803.
6. Innoue T, Maeda N, Sasaki K, Watanabe H, Innoue Y, Nishida K, *et al.* Factors that influence the surgical effects of astigmatic keratotomy after cataract surgery. *Ophthalmology* 2001;108:1269-74.
7. Muller-Jensen K, Fischer P, Siepe U. Limbal relaxing incisions to correct astigmatism in clear corneal cataract surgery. *J Refract Surg* 1999;15:586-9.
8. Norouzi H, Rahmati-Kamel M. Laser *in situ* keratomileusis for correction of induced astigmatism from cataract surgery. *J Refract Surg* 2003;19:416-24.
9. Khokhar S, Lohiya P, Murugesan V, Panda A. Corneal astigmatism correction with opposite clear corneal incisions or single clear corneal incision: Comparative analysis. *J Cataract Refract Surg* 2006;32:1432-7.
10. Bachernegg A, Rückl T, Riha W, Grabner G, Dextl AK. Rotational stability and visual outcome after implantation of a new toric intraocular lens for the correction of corneal astigmatism during cataract surgery. *J Cataract Refract Surg* 2013;39:1390-8.
11. Hirschall N, Gangwani V, Crnej A, Koshy J, Maurino V, Findl O. Correction of moderate corneal astigmatism during cataract surgery: Toric intraocular lens versus peripheral corneal relaxing incisions. *J Cataract Refract Surg* 2014;40:354-61.
12. Jeon JH, Hyung Taek Tyler R, Seo KY, Kim EK, Kim TI. Comparison of refractive stability after non-toric versus toric intraocular lens implantation during cataract surgery. *Am J Ophthalmol* 2014;157:658-65.
13. Holland E, Lane S, Horn JD, Ernest P, Arleo R, Miller KM. The AcrySof toric intraocular lens in subjects with cataracts and corneal astigmatism: A randomized, subject-masked, parallel-group, 1-year study. *Ophthalmology* 2010;117:2104-11.
14. Sheppard AL, Wolffsohn JS, Bhatt U, Hoffmann PC, Scheider A, Hütz WW, *et al.* Clinical outcomes after implantation of a new hydrophobic acrylic toric IOL during routine cataract surgery. *J Cataract Refract Surg* 2013;39:41-7.
15. Hansegawa Y, Okamoto F, Nakano S, Hiraoka T, Oshika T. Effect of preoperative corneal astigmatism orientation on results with a toric intraocular lens. *J Cataract Refract Surg* 2013;39:1846-51.
16. Bissen-Miyajima H, Negishi K, Hieda O, Kinoshita S. Microincision hydrophobic acrylic aspheric toric intraocular lens for astigmatism and cataract correction. *J Refract Surg* 2015;31:358-64.
17. Lubinsky W, Kazmierczak B, Gronkowska-Sarafin J, Podboraczynska-Jodko K. Clinical outcomes after uncomplicated cataract surgery with implantation of the tecnis toric intraocular lens. *J Ophthalmol* 2016;2016:3257217.
18. Bauer NJ, de Vries NE, Webers CA, Hendrikse F, Nuijts RM. Astigmatism management in cataract surgery with the AcrySof toric intraocular lens. *J Cataract Refract Surg* 2008;34:1483-8.
19. Kim MH, Chung TY, Chung ES. Long-term efficacy and rotational stability of AcrySof toric intraocular lens implantation in cataract surgery. *Korean J Ophthalmol* 2010;24:207-12.
20. Farooqui JH, Koul A, Dutta R, Shroff NM. Management of moderate and severe corneal astigmatism with AcrySof® toric intraocular lens implantation – Our experience. *Saudi J Ophthalmol* 2015;29:264-9.
21. Emesez M, Dextl AK, Krall EM, Bachernegg A, Moussa S, Jell G, *et al.* Randomized controlled clinical trial to evaluate different intraocular lenses for the surgical compensation of low to moderate-to-high regular corneal astigmatism during cataract surgery. *J Cataract Refract Surg* 2015;41:2683-94.
22. Kessel L, Andresen J, Tendal B, Erngaard D, Flesner P, Hjortdal J. Toric intraocular lenses in the correction of astigmatism during cataract surgery: A systematic review and meta-analysis. *Ophthalmology* 2016;123:275-86.
23. Mendicutte J, Irigoyean C, Aramberry J, Ondarra A, Montés-Micó R. Foldable toric intraocular lens for astigmatism correction in cataract patients. *J Cataract Refract Surg* 2008;34:601-7.
24. Alió JL, Agdeppa MC, Pongo VC, El Kady B. Microincision cataract surgery with toric intraocular lens implantation for correcting moderate and high astigmatism: Pilot study. *J Cataract Refract Surg* 2010;36:44-52.
25. Koshy JJ, Nishi Y, Hirschall N, Crnej A, Gangwani A, Maurino V, *et al.* Rotational stability of a single-piece toric acrylic intraocular lens. *J Cataract Refract Surg* 2010;36:1665-70.