

# Surgical Excision Of A Craniopharynginoma By Transcallosal Septum Pellucidum Interforniceal Approach

Kong J<sup>1</sup>, Kahamba JF<sup>2</sup>

1-Department of Neurosurgery, Qingdao Municipal Hospital, Shandong Province, China

2-Department of Neurosurgery, Muhimbili Orthopedic and Neurosurgical Institute, Dar es Salaam, Tanzania

**Correspondence to:** Dr. Kong Jun: P.O. Box 65474, Dar es Salaam, Tanzania, Email: kongjff2003@hotmail.com, kongjff@163.com

## Abstract

Craniopharynginoma is a congenital benign tumor resulting from vestigial epithelial cell in the craniopharyngium during embryological development. It is one of the most common childhood tumors consisting about 16% of all intracranial neoplasms. We have surgically treated four children with craniopharynginoma which encroached the third ventricle by transcallosal septum pellucidum interforniceal approach from August, 2006 to December, 2009. The objective was to study this approach of removal of craniopharynginoma. Control CT or MRI scans of the brain were used to assess the postoperative degree of excision of the tumor. We believe that the surgical excision of craniopharynginomas by the transcallosal septum pellucidum interforniceal approach is a very important method. All the patients had good results.

**Key words** craniopharynginoma; transcallosal approach, septum pellucidum, interforniceal

## Material and Methods

**I. The Patients:** There were two male and two female patients with their age ranging from four to seventeen years. The average was 10.9 years. The presenting chief complaints included: polydipsia and polyuria in one case, progressive hypopsia in the second case; headache in the third case; and hormonal manifestations in the last case.

**II. Neuroimaging :** All the patients had CT and MRI done. Tumors in two patients encroached into the saddle area of the anterior aspect of the third ventricle. In three cases, tumors had complete cystic degeneration while one had partial cystic degeneration while in the last case the tumor was completely solid. Three of the cases had calcification whereas three cases had

different degrees of edema.

**III. The Operation:** A) Craniotomy: U-shaped incision is made on either the left or right side of the midline depending on the direction of tumor growth. The posterior line of the skin flap should be 1.5 cm posterior to the coronal suture. The inner edge of this incision should lie on the mid-line. The full thickness flap is then reflected anteriorly. Two burr holes, 4.5 cm apart, should be drilled at the level of the coronal suture posteriorly while the other two, 4 cm apart, anteriorly, making a ladder-shaped bone flap at the edge of the sagittal sinus medially. Precaution should be undertaken not to cross the midline so as not to cause injury to the sagittal sinus.

B) Separation between hemispheres: A curved incision should be made to allow the dura to be reflected to the midline. The operating microscope should be positioned in anteversion at twenty degrees. An interhemispheric longitudinal split is made perpendicularly towards the line connecting two ears. The bridging vein in front of the coronal suture should be coagulated and cut but the bigger vein should be maintained.

C) Incision of the corpus callosum: First, the pericallosal arteries are identified on both sides. The incision on the corpus callosum should be located between the two pericallosal arteries which can be either separated carefully when clinging to each other, or be pushed together to one side to make an incision lateral to the vessels while maintaining the mid-line. Where the three branches of the vessels meet, the wider gap in between them is chosen for the incision. There may exist a middle callosal artery. The corpus callosum should not be incised forcefully when only one artery supplies both medial surfaces of the hemispheres. The boundary should be the precentral sulcus on the medial surface of the right hemisphere.

(D) Separation of the septum pellucidum and

incision of inter-fornices : Following the incision of the corpus callosum, the septum pellucidum is opened on the right or the left side. The anatomical landmarks are: the choroid plexus in the lateral ventricle, vena thalamostriata and septal vein leading to the foramen of Monro and the fornix. Longitudinal separation of the fornix with a dissector along the mid-line following the foramen of Monro is done. There are eighty percent of patients who have septum pellucidum cavity which can make it easy to reach the inter-fornices. Incision of the inter-fornices at the roof of the third ventricle, exposes the tumor.

E) Tumor excision: The cystic tumour is punctured and drained slowly. When the tumor collapses, the wall of the tumor should be raised and separated from normal surrounding tissue. In the case of a solid tumour central excision is done, allowing it to collapse. Then the wall of the tumor should be raised and removed. The tumour should not be detached by force when it encroaches the hypothalamus especially when it is calcified. It should be carefully removed with the dissector. Oftentimes, it is not necessary to remove the tumour in its totality. Cottonoid should be used to block the proximal opening of the aqueduct to prevent bleeding into the fourth ventricle.

Apart from preventing injury to the bigger vessels constituted by the circle of Willis, precautions should be undertaken to maintain the blood supply from the small collateral arteries. Large ischemic areas of the hypothalamus will occur in case of injury of these arteries. There is no need to put in a drain tube when closing. In the case the aqueduct gets blocked we regard that the corpus callosum incision equals the opening of the roof of the third ventricle, creating a

communication with the basal cisterns thus preventing intracranial hypertension.

**IV. Postoperative treatment:** It is the complexity of water and electrolyte imbalance that may easily cause poor results in children because of their deficient abilities to adjust water and electrolyte metabolism. Sodium should be used judiciously intraoperatively and input, output and electrolyte monitoring be done every morning and night postoperatively. In principle, diuretics should not be used. Sodium administration depends on electrolyte status. Hypophysin and Minirin use is based on urine volume. It is usual to use postoperative anticonvulsants such as carbamazepine orally, steroids such as Dexamethasone and Prednisone and hormones such as Thyroxine and other necessary symptomatic treatments.

## Results

In all cases, tumour seen by the naked eye by the surgeon was removed. Control CT and MRI scans done shortly postoperatively showed that the calcifications had disappeared. Also, postoperative CT or MRI scan was used to establish the level of tumour excision. Among these four cases, two were totally resected, one case was subtotally resected and one case was partially resected. Three cases developed postoperative polydipsia and polyuria two of whom got better following treatment. One patient developed grand mal seizure, another patient developed memory disorder and the last patient developed hydrocephalus all of which were transitional.

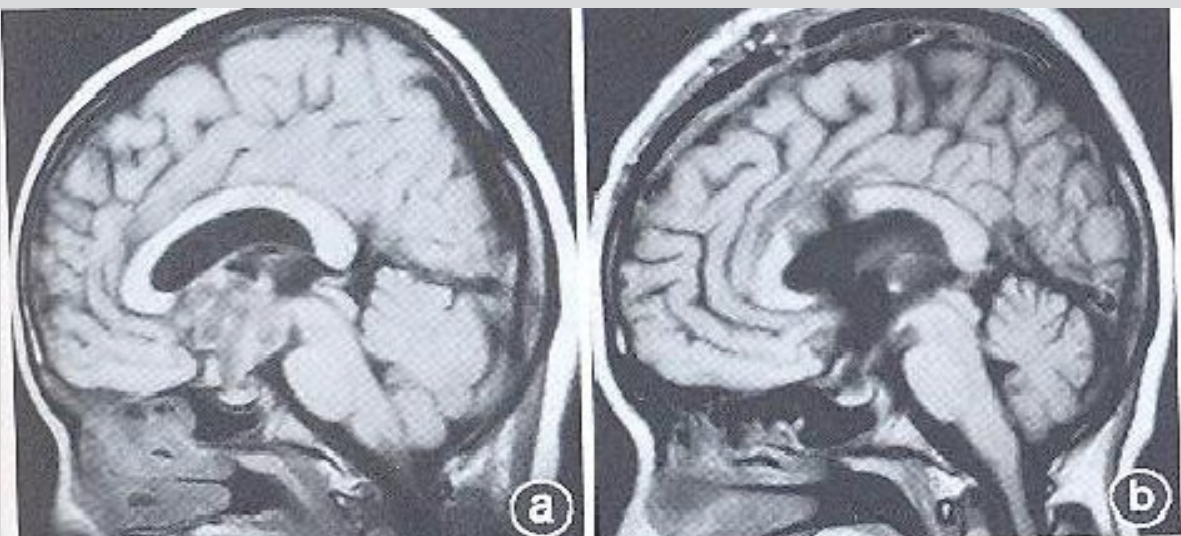


FIGURE 1, craniopharyngioma in third operation

FIGURE 2, tumour totally resected Ventricle before

## Discussion

It is very difficult to remove craniopharynginoma in the third ventricle. Total or partial removal of a highly calcified tumor adherent on the inferior part of the thalamus opticus is controversial. Rajan advocated on subtotal or partial tumor resection (6). He regards these tumors to recur easily and the frequency of complications from the second operation due to tumor recurrence is higher than the first operation after partial resection. So we advocate thorough removal of tumor in the first instance. In our series, two cases were totally removed, one case subtotally removed and one case partially removed due to its tight adherence onto the third ventricle. The decision on total resection of craniopharynginoma removal is based on thorough exploration of the tumor. The surgical approach depends on location of the tumor. The corpus callosum - septum pellucidum - interforniceal approach was first raised by Apuzzo in 1982 (7). Winkler thought there were less complications from this approach after he studied the clinical and anatomical details (2). Siwanuwantn thought the callosal-interforniceal approach was the best approach to the third ventricle(8). We think this approach has the following positive features: (1) It is the nearest approach to reach the third ventricle; (2) Operation under the microscope can expose both sides and extend vision anteriorly and posteriorly. The visual angles on the left and right can extend from ten to fifteen degrees thus allowing tumor exploration almost without limitations. It becomes easy therefore to see important structures on both sides clearly without undue pulling onto brain tissue. (3) Since there is no need to open the fornix column on one side and the anterior region of the thalamus, there is no risk of injury to the thalamus, vena thalamostriata and internal cerebral veins. For the same reason, the occurrence of postoperative hemiplegia, coma, memory disorder and mutism is lessened. (4) It is possible to explore bigger tumors located in frontal, middle and posterior part of the third ventricle and do total or subtotal resection by adjusting the patient's head position and the angle of the microscope. (5) There being no need to open the cerebral cortex lessens the occurrence of brain injury, hemiplegia as

well as postoperative epilepsy. (6) There is little effect on message transfer between two hemispheres after a limited incision of the corpus callosum.

In short, treatment of craniopharynginoma in children, is complex. Surgical removal and radiotherapy are the basic methods. However, outcome depends on the thoroughness of the operation and correction of water, electrolyte and endocrine imbalances.

## References

1. Woiciechowsky C, Vogel S, Lehmann R, et al. Transcallosal removal of lesions affecting the third ventricle: anatomic and clinical study. *Neurosurgery*, 1995,36:117-122
2. Winkler PA, Ilmberger J, Krishnan KG, et al. Transcallosal interforniceal-transforaminal approach for removing lesions occupying the third ventricular space : clinical and neuropathological results. *Neurosurgery*, 2000, 46, 879-888
3. Winkler PA, Weis S, Buttner A, et al. The Transcallosal interforniceal approach to the third ventricle : anatomic and microsurgical aspects. *Neurosurgery*, 1997,40 : 973-981
4. Holtzman RN, Brust JC, Ainvette IG, et al. Acute ventricular hemorrhage in adults with hydrocephalus managed by corpus callosotomy and fenestration of the septum pellucidum. *J Neurosurg*. 2001, 95: 111-115
5. Pascual JM, Gonzalez-Lianos F, Barrios L. Intraventricular craniopharyngiomas: topographical classification and surgical approach selection based on an extensive overview. *Acta Neurochir*, 2004, 146, 785-802
6. Ragan B, Ashley S, Gormon C, et al. Craniopharyngioma as a longterm results following limited surgery and radiotherapy. *Radiother Oncol*, 1999, 26: 1-10
7. Apuzaa ML, Chikovani OK, Gott PS, et al. Transcallosal approaches for lesions affecting the third ventricle: surgical considerations and consequences. *Neurosurgery*, 1982, 10: 547-554
8. Siwanuwatn R, Deshmukh P, Feiz-Erfan I, et al. Microsurgical anatomy of the transcallosal anterior interforniceal approach to the third ventricle. *Neurosurgery*, 2005,56: 390-396