

Histo-pathological pattern of intracranial tumours in the National Hospital, Abuja

Paul Jibrin¹, Kaunda Ibebuike², Aisha Nabila Ado-wanka¹

1. Department of Pathology, National Hospital, Abuja, Nigeria.
2. Division of Neurosurgery, Department of Surgery, Imo State University Teaching Hospital, Orlu, Nigeria.

Abstract

Background/aims: Intracranial tumours demonstrate characteristic diagnostic histopathological features. Our aims were to look at the histo-pathological pattern of intracranial tumours in our environment including their age and sex distribution.

Methods: The histology request forms and slides of all intracranial specimens submitted to the histo-pathology department of National Hospital, Abuja, over an 11 year period (2005 and 2015) were retrospectively reviewed.

Results: Intracranial specimens and intracranial tumours accounted for 0.6% and 0.5% respectively of all samples submitted. Meningiomas accounted for the most frequent diagnosis for all intracranial specimens and intracranial tumours at 35% and 41% respectively followed by pituitary adenoma at 19% and 22%, and astrocytoma at 13% and 20%. The male female ratio for all diagnoses was 1:1. The mean age at diagnosis was 35 ± 17.1 years. The frequency of intracranial tumours in children was 11.8% with a mean age of 8.3 ± 4.4 years and an equal sex distribution. In children, glioma and embryonal tumours were the most frequent diagnosis at 25%.

Conclusion: The histo-pathological pattern of intracranial tumours in our environment showed that meningioma is the most common intracranial tumour in adults, while glioma and embryonal tumours are the most common intracranial tumours in children.

Keywords: Histo-pathological pattern, intracranial tumour, meningioma, glioma, embryonal tumours.

DOI: <https://dx.doi.org/10.4314/ahs.v18i2.12>

Cite as: Jibrin P, Ibebuike K, Ado-wanka AN. Histo-pathological pattern of intracranial tumours in National Hospital, Abuja. *Afri Health Sci*. 2018;18(2): 281-286. <https://dx.doi.org/10.4314/ahs.v18i2.12>

Introduction

Intracranial tumours may arise from neural tissue within the brain as primary tumours or they may be due to metastases. They represent some of the most biologically aggressive tumours in both adult and paediatric age groups. Brain tumours have traditionally been classified based on

their presumed cell of origin and degree of differentiation as determined by light microscopy. However, it is known that these tumours have heterogeneous molecular profiles, giving rise to varying biological outcomes and hence treatment protocols. According to GLOBOCON 2012: Estimated cancer incidence, mortality and prevalence worldwide, the incidence of brain tumours was 1.9% (equal incidence of 1.8% in both males and females) and mortality was 2.3%.¹ The types of tumours seen in adults and children differ. Data on the frequency, sub-types and clinico-pathologic characteristics of intracranial tumours in Nigeria and Africa is limited. A few studies have been done in Nigeria with varying results. The Histo-pathology Department of the National Hospital, Abuja, is one of our major neuro-pathological centres in Nigeria and

Corresponding author:

Paul Jibrin,
Department of Pathology, National Hospital
Abuja, Nigeria.
Mobile: +234 803 713 4695
E-mail: jibson2014@gmail.com

therefore receives specimens from neurosurgery centres outside Abuja. This is the first review of intracranial tumours submitted to the department, and our aims were to look at the histo-pathological pattern of these tumours in our environment, increase awareness on their prevalence in our environment including their age and sex distribution. A proper understanding of the histologic type and its epidemiologic variable are important in the management of the patient with intracranial tumour.

Materials and methods

This was a retrospective data based study of all the intracranial tumours diagnosed in the Department of Histo-pathology, National hospital, Abuja, Nigeria between Jan 2005 and Dec 2015 spanning a period of 11 years. The histology request forms and slides of all intracranial specimens submitted to the Histo-pathology Department of National Hospital, Abuja, were retrieved and reviewed. It is worth noting that National Hospital, Abuja, has a state-of-the-art stainless steel tissue and slide cabinet, hence blocks from the inception of the hospital in 1999 are still intact. The hospital commenced immunohistochemistry

analyses of specimens in 2006, hence specimens from 2006 were subjected to immunohistochemistry. Data obtained were analyzed using Microsoft® Excel® for Mac 2011 (version 14.6.3). The cases were classified using 2007 WHO classification of intracranial tumours. Confidentiality of the identity of the patient and personal health information were maintained in strict compliance to the Guideline of Helsinki Declaration on Biomedical Research on Human Subject. The limitation of the study is the small number of the sample compared to the population of Nigeria which is over 170 million.

Results

A total of 121 intracranial specimens out of a total of 20,191 samples were submitted to the Histo-pathology Department, National Hospital, Abuja, over an 11-year period (2005 and 2015). These accounted for 0.6% of the total specimen received during that period. As shown in figure 1, there was an increase in the number of specimens over the years with the highest number of samples received in 2014 at 28% (n=34) followed by 2015 at 20% (n=25) and the year with the lowest recorded samples received was 2008 at 0.8% (n=1).

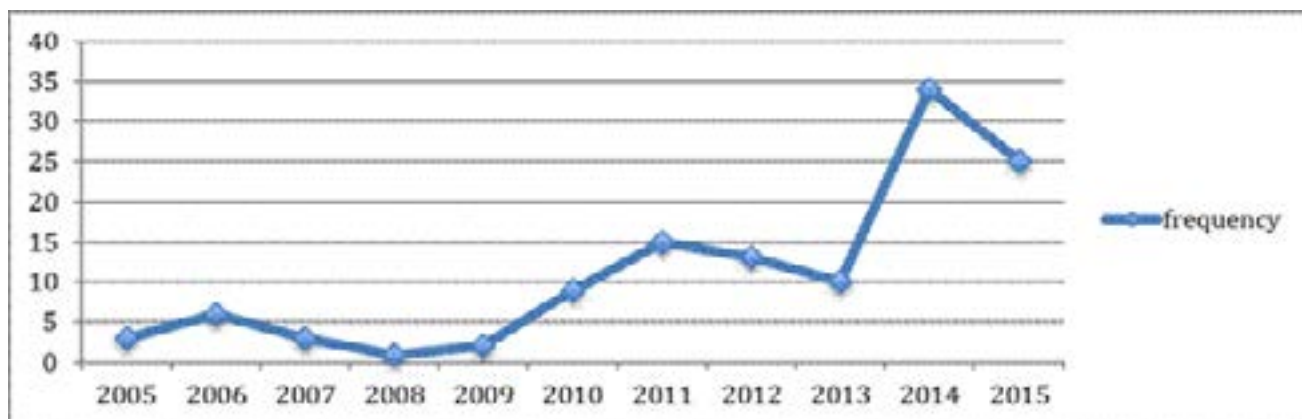


Figure 1: Chart showing the frequency of intracranial specimens received over 11 years

Meningiomas accounted for the most frequent diagnosis for all intracranial specimens (neoplastic and non-neoplastic) at 35% followed by pituitary adenoma 19% and astrocytoma at 13%. There were 102 intracranial neoplasms (benign and malignant), accounting for 0.5% of

all samples. Again, Meningioma was the most frequent diagnosis at 41%, followed by pituitary adenoma at 22% and glioma at 20% (figure 2). The least diagnoses were central neurocytoma and ependymoma and at 1% each. The male female ratio for all diagnoses was 1:1.

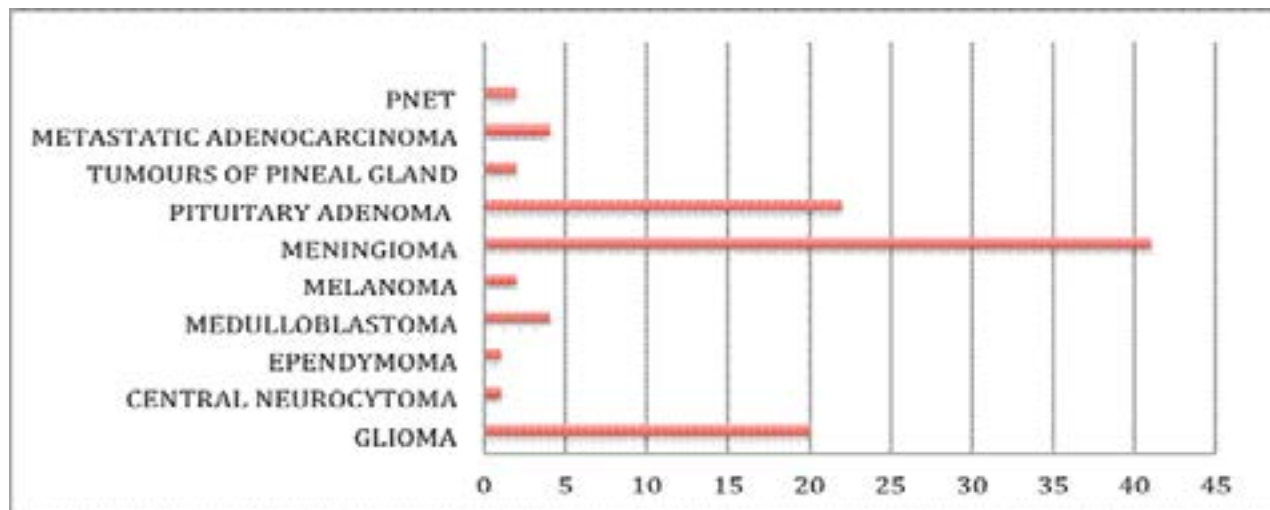


Figure 2: Chart showing the frequency of intracranial tumours

The mean age at diagnosis was 35 ± 17.1 years and as shown in figure 3, tumours were observed more in patients in their 30s and 40s. The majority of the tumours were seen in adults at 83.3% with an age range between 17-74 years and a mean age of 41 ± 12.5 years. The most common tumour in adults was meningioma followed by

pituitary adenoma and glioma. The frequency of intracranial tumours in children was 11.8% with an age range of between 1-15 years, a mean of 8.3 ± 4.4 years and an equal sex distribution. In children, glioma and embryonal tumours (medulloblastoma and ependymoma) were the most frequent diagnosis at 25% followed by meningioma and tumours of the pineal gland at 16.7% each.

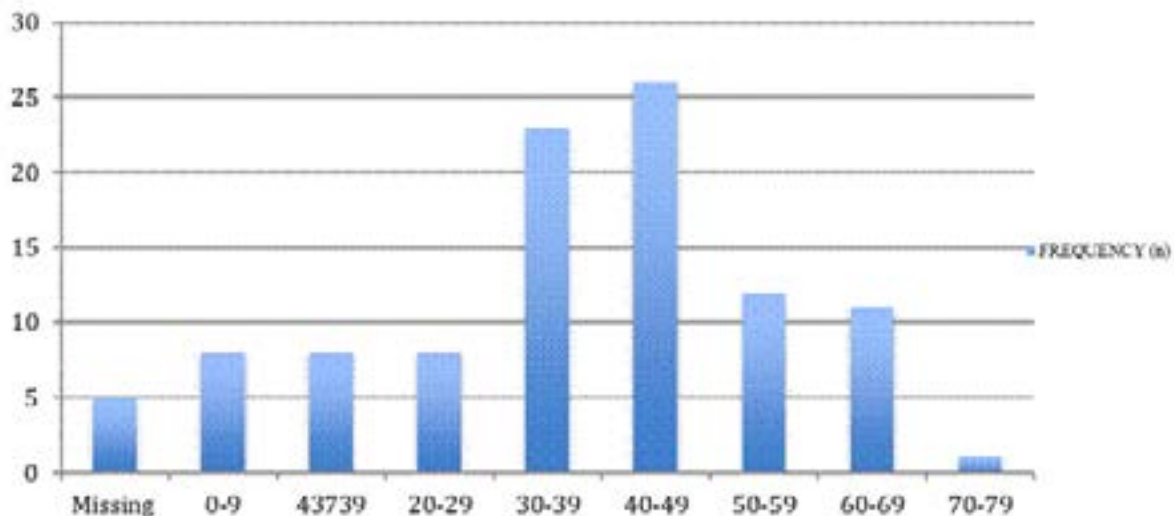


Figure 3: Chart showing the frequencies of intracranial tumours in the age groups

In meningioma, the male female ratio was 1:1, the age range was between 9-74 years and the mean age at diagnosis was 42.5 ± 12.8 years (table 1). Majority (95.1%) were seen in adults while 4.9% were seen in children. The most frequently diagnosed sub-type was meningothelial meningioma. Pituitary adenomas were the second most common tumours accounting for 22% of cases. There was a male predominance (male female ratio = 2:1) and a mean age of 44 ± 7 years. Gliomas accounted for the third most common tumour. It had a slight female preponderance (male female ratio = 1:1.7) and the mean age at diagnosis was 32 ± 18 years. The frequency of gliomas

seen in children was 12.5%. Metastatic adenocarcinomas accounted for 4% of the diagnoses and all the cases were seen in adults. All the tumours of the pineal gland were diagnosed in children with a mean age of 6 years and all were seen in males. Only one ependymoma was seen and it was diagnosed in an 8 year old boy. There was an equal distribution of the medulloblastoma cases as 50% were seen in adults and the remaining half in children. It had an equal sex distribution (male female ratio = 1:1) and a mean age of 15.5 ± 7.8 years. Cases of melanoma were diagnosed in adults with a mean age of 47 ± 7.1 years and all occurred in males.

Table 1: Table showing the sex and age distribution of intracranial tumours in both adults and children

Diagnosis	Male female ratio	Age range (years)	Average age (years)
Meningioma	1:1	9-74	42.5
Pituitary adenoma	2:1	7-64	44
Glioma	1:1.7	7-65	32
PNET	0:2	2-35	18.5
Metastatic adenocarcinoma	1:1	35-67	53
Tumours of the pineal gland	2:0	6-13	6
Ependymoma	1:0		8
Central neurocytoma	0:1		18
Medulloblastoma	1:1	1-27	15.5
Melanoma	1:0	42-52	47

Discussion

Not much research has been done on the histopathological pattern of intracranial tumours in Nigeria. This may be due to the limited availability of diagnostic facilities and lack of presentation of patients to hospital. It could also be due to the inadequate number of neurosurgeons in the country and hence surgical specimens available for diagnosis. In our centre, there was a progressive increase in the number of intracranial specimens submitted over the years, with a marked increase observed from 2010 onwards. This may have coincided with the presence of additional neurosurgeons employed by the hospital includ-

ing the utilization of our Histo-pathology Department by other neurosurgeons in Nigeria with the increased awareness of the availability of immunohistochemistry in our department.

The relative frequency of intracranial tumours (0.5%) among all specimens submitted over the study period is higher than that obtained by Soyemi et al² (0.004%) in a study from South-West Nigeria. However, it contrasts with the findings in the study by Awodele et al³ in South-West Nigeria in which brain cancer represented 3.9% of all cancers, and was the 6th most common tumour. In other reports, according to the National Cancer Regis-

try of South Africa, brain tumours accounted for 0.56% of all cancers in males and 0.36% in females.⁴ In Ghana, CNS tumours represented 0.31% of all hospital admissions and 22% of neurosurgical procedures.⁵ A review of the hospital and death registers of the Lagos University Teaching Hospital, Nigeria, showed that CNS-associated cancer was responsible for 4.9% of all deaths.⁶

There was equal gender distribution (male female ratio = 1:1) seen in our study. This is similar to that reported by Olasode et al⁷ and Soyemi et al² but in contrast to the slight male dominance observed by Idowu et al⁸, both studies from South-West Nigeria. The mean age in adults was 41 years with more tumours seen in the 4th and 5th decades. This is in contrast to studies seen in other parts of the country, which showed age range between 33-50 years.⁸⁻¹⁰ The mean age for children was 8 years and this is similar to that reported by Idowu et al.⁸

In this study meningiomas accounted for the most frequent diagnosis for all intracranial tumours at 41% followed by pituitary adenomas 22% and gliomas at 20%. The high prevalence of meningiomas in our study compares with the findings by Idowu et al⁸, Ibebuikwe et al¹¹ in Johannesburg, South Africa, which both reported meningiomas as the most common brain tumour in their studies. However, it contrasts with other studies showing gliomas to be the most common intracranial tumour.^{2,7,10} The equal male female ratio of 1:1 for meningiomas in our study agrees with earlier observations in the literature^{12,13}, which reported equal gender distribution, but contrasts with studies by Idowu et al⁸ and Ibebuikwe et al¹¹, which revealed female preponderance. However, Fynn et al¹⁴ in Pretoria, South Africa (2.5:1) and Gasparetto et al¹⁵ in Brazil reported a male preponderance in their study (2:1).

Pituitary adenomas had a frequency of 22% and were seen more in males. Olasode et al⁷ and Idowu et al⁸ reported a frequency of 17.1% and 16% in their studies. Gliomas, which have been reported as the most frequently observed brain tumours in some studies, was the third commonest in our study at 20%. In our study, the mean age for children was 8.3 years, and this was slightly higher than the 7.3 years reported by Ogun et al¹⁶ but similar to that reported by Ahmed et al¹⁷ in Pakistan of 8.8 years. Gliomas and embryonal tumours (medulloblastoma and ependymoma) were the most common tumours seen in

children. This contrasts with studies showing gliomas to be more common in children.^{7,16,18,19}

There are known risk factors associated with brain tumours and these include radiation exposure, hereditary factors, age, sex, ethnicity, infections, and heavy metal exposure.²⁰ Not many studies have been carried out in our environment to elucidate possible risk factors for development of intracranial tumours. However, high levels of lead have been associated with development of meningiomas. It has been suggested that ingestion of snails, canned meat and fish may be risk factors for development of meningiomas.²⁰

Conclusion

Our findings indicate that meningioma is the most common intracranial tumour in adults, while glioma and embryonal tumours are the most common intracranial tumour in children in our environment. The histopathological pattern of intracranial tumours in our environment provides significant information on the behavior of these tumours. However, inadequate facilities, dearth of neurosurgeons and resources hamper research. Additionally, genetic researches need to be carried out as they may provide greater understanding of CNS tumours.

Conflict of interest

None.

Abbreviations

CNS, central nervous system; PNET, primitive neuroectodermal tumour.

References

1. Ferlay J, Soerjomataram I, Dikshit R, Eser S, Mathers C, Rebelo M, et al. Cancer Incidence and Mortality Worldwide: Sources, Methods and Major Patterns in Globocan 2012. *Int J Cancer*, 2015;13:359-386.
2. Soyemi SS, Olugbenga OO. Spectrum of Intracranial Tumours in a Tertiary Health Care Facility: Our Findings. *Pan Afr Med J*, 2015;20(24).
3. Awodele O, Adeyomoye AA, Awodele DF, Fayankinu VB, Dolapo DC. Cancer Distribution Pattern in South-Western Nigeria. *Tanzan J Health Res*, 2011;13:125-31.
4. Fact Sheet on Cancer of the Brain and Central Nervous System [Internet]. 2015 [Cited July 2016]. Available from: cansa.org.za.

5. Andrews NB, Ramesh R, Odjidja T. A Preliminary Survey of Central Nervous System Tumors in Tema, Ghana. *West Afr J Med*, 2003;22:167-72.
6. Akinde OR, Phillips AA, Oguntunde OA, Afolayan OM. Cancer Mortality Pattern in Lagos University Teaching Hospital, Lagos, Nigeria. *J Cancer Epidemiol*, 2015; 2015:842032.
7. Olasode BJ, Shokunbi Mt, Aghadiuno PU. Intracranial Neoplasms in Ibadan, Nigeria. *East Afr Med J*, 2000;77:4-8.
8. Idowu O, Akang E, Malomo A. Symptomatic Primary Intracranial Neoplasms in Nigeria, West Africa. *JNS Turkish*, 2007;24:212-218.
9. Igun O. Diagnosis and Management of Brain Tumours at Jos University Teaching Hospital, Nigeria. *East Afr Med J*, 2001;78:148-51.
10. Ohaegbulam SC SN, Ikerionwu S. Intracranial Tumours in Enugu, Nigeria. *Cancer*, 1980;46:2322-24.
11. Ibebuike K, Ouma J, Gopal R. Meningiomas among intracranial neoplasms in Johannesburg, South Africa: prevalence, clinical observations and review of the literature. *African Health Sciences*, 2013; 13:118–121.
12. Bondy ML, Ligon BL. Epidemiology and aetiology of intracranial meningiomas: a review. *J Neurooncol*, 1996;29:197-205.
13. Haddad G, Al-Mefty O. Meningiomas: An overview. In: Wilkins RH, Rengachary SS, editors. *Neurosurgery*. 2nd ed. New York: McGraw-Hill; 1998. p. 833-41.
14. Fynn E, Khan N, Ojo A. Meningioma - a review of 52 cases. *SA Journal of Radiology*, 2004:3-5.
15. Gasparetto EL, Leite CC, Lucato LT, Barros CV, Marie SKN, Santana P, et al. Intracranial meningiomas: magnetic resonance imaging findings in 78 cases. *Arquivos de Neuro-Psiquiatria*, 2007;65:610-4.
16. Ogun GO AA, Babatunde TO, Ogun OA, Salami A, Brown BJ, Akang E. Central Nervous System Tumours in Children in Ibadan, Nigeria: A Histo-pathologic Study. *Pan Afr Med J*, 2016;24(34).
17. Ahmed N BY, Sadiq S, Shakoor KA Paediatric Brain Tumours at a Tertiary Care Hospital in Karachi. *Asian Pac J Cancer Prev*, 2007;8:399-404.
18. Eyenga V NJ, Atangana R, Etom E, Ngowe MN, Basong Y, Oyono JE, Sosso M. Central Nervous System Tumours in Cameroon: Histo-pathology and Demography. *Cahiers d'études et de recherches francophones/Santé* 2008;18:39-42.
19. Uche E SM, Malomo AO, Akang EEU, Lagunji I, Amanor-Boadu SD. Pediatric Brain Tumors in Nigeria: Clinical Profile, Management Strategies, and Outcome. *Child Nervous System*, 2013;29(7).
20. Ngulde SI FF, Ramesh A, Moosa S, Purow B, Lopez B, Schiff D, Hussaini IM, Sandabe UK. Improving Brain Tumor Research in Resource-Limited Countries: A Review of the Literature Focusing on West Africa. *Cureus*, 2015;7(11).