

## SCHISTOSOMIASIS PRESENTING AS COLONIC POLYPOID MASSES IN A NIGERIAN PATIENT

A. Akere<sup>1</sup>, A.O. Oluwasola<sup>2</sup>, T.O. Fakoya<sup>1</sup> and A. Lawan<sup>2</sup>

1. Department of Medicine, College of Medicine, University of Ibadan/University College Hospital, Ibadan, Nigeria
2. Department of Pathology, College of Medicine, University of Ibadan/University College Hospital, Ibadan, Nigeria

### Correspondence:

**Dr. A. Akere**

Dept. of Medicine,  
College of Medicine,  
University of Ibadan/  
University College Hospital,  
Ibadan, Nigeria  
P.O. Box 28829, Agodi, Ibadan  
E-mail: adeakere@yahoo.co.uk  
Tel: +2348033257211

### ABSTRACT

Intestinal Schistosomiasis is a serious disease and is commonly produced by *S. mansoni* and *japonicum*. The presence of viable ova of the organism in the colon elicits inflammation, formation of granuloma, ulcers, haemorrhage and colonic fibrosis with subsequent longterm sequelae. *Schistosoma mansoni* is endemic in the Middle East, Africa, Central and South America. This is a case of a Nigerian with colonic polypoid masses which turned out to be Schistosomal mansoni infection.

**Keywords:** Colonic polypoid masses, *Schistosoma mansoni*, Nigerian patient

### INTRODUCTION

There are five species of *Schistosoma* that cause human Schistosomiasis. These are the intestinal species: *Schistosoma mansoni*, *japonicum*, *mekongi* and *intercalatum*, and the urinary species: *Schistosoma haematobium*<sup>1</sup>. Infective cercariae released from infected freshwater snails initiate human infection through penetration of intact skin. Sexually mature worms then migrate to the venous system of the intestine (for the intestinal species) or urinary bladder (for the urinary species) where ova are deposited.<sup>1</sup>

About 200-300 million individuals are thought to be infected in the Caribbean, South America, Middle East, Africa and Southeast Asia. *Schistosoma mansoni* is endemic in the Middle East, Africa, Central and South America, while *S. japonicum* is common in the Philippines, Thailand and China. *Schistosoma intercalatum* is found mostly in Africa.<sup>2</sup>

Schistosomiasis is a serious disease. Intestinal disease is commonly produced by *S. mansoni* and *japonicum*. Viable ova of the organism in the colon produce inflammation, formation of granuloma, ulcers, haemorrhage and colonic fibrosis with subsequent long term sequelae.<sup>3</sup>

A colonic polyp represents a mass of tissue protruding into the colonic lumen. The two major groups of colonic polyps are, the neoplastic (benign and malignant) and the non-neoplastic (hyperplastic, Peutz-Jeghers and inflammatory). Although, majority of patients with colonic polyps are asymptomatic, some

patients may present with occult or overt lower gastrointestinal bleeding, flatulence, diarrhea and constipation.<sup>4</sup>

Severe colitis arising from amoebic or bacterial dysentery, Crohn's disease and ulcerative colitis may produce inflammatory polyps.<sup>5,6</sup> Similar polyps which are made of eggs, adult worms and granulation tissue can also arise as a result of chronic schistosomiasis.<sup>7</sup>

Here, we present a case of a Nigerian with colonic polypoid masses which turned out to be Schistosomal mansoni infection.

### CASE PRESENTATION

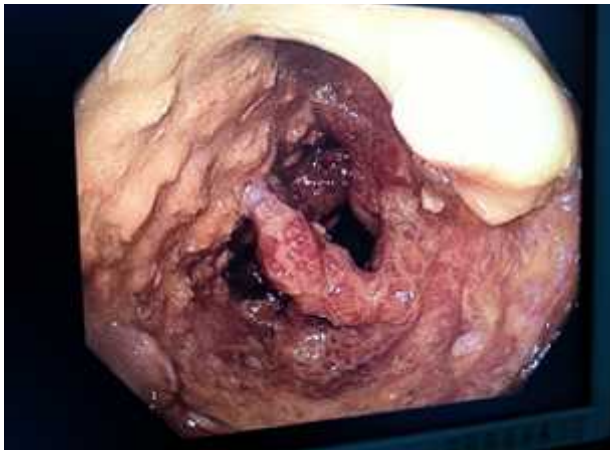The patient is a 29 year-old civil servant who presented with recurrent diarrhoea of 2 years duration. Stool is watery, mucoid but not bloody. The frequency is up to four times per day. There is associated tenesmus. No passage of undigested food particles. There is history of right lower abdominal pain and weight loss. No vomiting, anorexia or fever. Past medical history revealed previous blood transfusion and appendicectomy.

Examination showed a chronically ill-looking man with finger clubbing and mild dehydration. His vital signs were within normal range Examination of the abdomen, chest and cardiovascular system was unremarkable. Digital rectal examination revealed polypoid masses in the rectum.

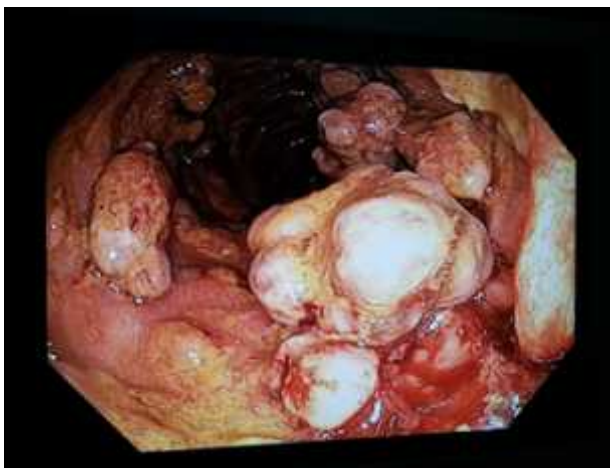The assessment was colonic polyps? type, the differential diagnoses were Inflammatory Bowel Disease and Colonic Polyposis.

*Results of investigations are as follows:*

Electrolytes, Urea and Creatinine: Na<sup>+</sup> – 135 mmol/l, K<sup>+</sup> – 3.9 mmol/l, Cl<sup>-</sup> – 107 mmol/l, HCO<sub>3</sub><sup>-</sup> – 20 mmol/l, Urea – 26 mg/dl, Cr – 1.2 mg/dl. Full Blood Count: Packed Cell Volume - 34%, WBC - 6800/mm<sup>3</sup> (Neutrophil-48%, Eosinophil- 1%, Basophil- 1%, Lymphocyte- 43%, Monocyte- 7%), Platelets - 319,000/mm<sup>3</sup>. ESR - 50 mm in the 1<sup>st</sup> hour (Westergren)



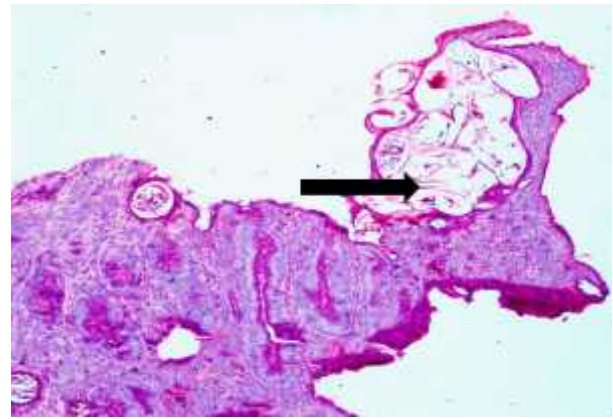
**Figure 1:** Polypoid masses in the rectosigmoid colon



**Figure 2:** Polypoid masses in the rectosigmoid colon

HIV 1&2 – Negative. Colonoscopy – Multiple entangled pedunculated polypoid masses were seen in the rectum and sigmoid colon from which biopsies were taken (Figures 1&2)

Histology revealed mild chronic inflammation of the stroma of the colonic biopsy tissue with several structures reminiscent of sections of integument of a worm within the intestinal wall and a diagnosis of helminth-induced chronic inflammation of the



**Figure 3:** Photomicrograph of biopsy of rectosigmoid mass showing a collection of Schistosoma ova within mucosa (thick long arrow). (Haematoxylin and eosin) x100

rectosigmoid section of the intestine was made. (Figures 3). Stool microscopy revealed ova of schistosoma mansoni with pus and red blood cells. Patient was placed on Praziquantel at a dose of 20 mg/kg every 8 hours for 24 hours. At follow up clinic thereafter, his symptoms had resolved. However, patient was lost to further follow up and so could not have a repeat colonoscopy done to document polyp regression.

## DISCUSSION

Human beings are mainly infected by *S. mansoni* which causes hepatic and intestinal schistosomiasis in South America, the Arabian Peninsula and Africa; *S. japonicum* also causes hepatosplenic and intestinal schistosomiasis in China, Indonesia and the Philippines.<sup>8</sup> Although, *S. mansoni* can infect primates and rodents, human beings remain the main host.<sup>8</sup>

It is known that cercariae penetration of the skin can produce a temporary urticarial rash.<sup>9</sup> This was not reported or observed in our patient. Although, this rash is thought to occur more commonly in tourists and migrants.<sup>9</sup> This might explain its absence in our patient. Another explanation might be because our patient was seen in the chronic phase of the disease during which, the rash if present initially would have disappeared.

Also, features of acute schistosomiasis (Katayama fever) which are fever, fatigue, malaise, non-productive cough, myalgia, eosinophilia were not observed in our patient. These symptoms are known to develop a few weeks to months after infection and subside 2-10 weeks after.<sup>9,10</sup> Again, it is possible that all these symptoms were present in our patient at the onset of the disease, but were attributed to another common infection in

our environment like malaria. It has been reported that, due to under-diagnosis or in-utero sensitization, Katayama fever resulting from *S. haematobium* or *mansoni* is not common in chronically exposed individuals.<sup>11</sup> However, Katayama fever is believed to be common in travelers, tourists and individuals who are accidentally exposed to transmission.<sup>9,12,13</sup>

In chronic and established infection, which was what our patient presented with, the lesions are believed to be as a result of trapped schistosomal eggs in the tissues during migration.<sup>8</sup> This process then provokes microulcerations, bleeding, granulomas and pseudopolyposis.<sup>14,15</sup>

In intestinal schistosomiasis, most of the lesions are found in the rectum and large bowel. This is true of our patient, in whom the lesions were seen in the rectosigmoid region during colonoscopy.

Patient with intestinal schistosomiasis present with chronic abdominal pain and discomfort, and diarrhoea with or without haematochezia.<sup>16,17</sup> The main symptom in our patient was recurrent diarrhoea without haematochezia. This seems to be the most common symptom in patients with intestinal schistosomiasis. In a population study, 3-55% of the infected individuals had diarrhoea, while 11-50% had bloody diarrhea.<sup>16,18,19</sup> In a report of 46 cases of colonic schistosomiasis by Cao *et al*,<sup>20</sup> diarrhoea was found in 67.3% of patients which made it the most common symptom in those patients as was the case in our patient. In another study by Rocha *et al*,<sup>21</sup> diarrhoea was the most common symptom (56%) observed among 34 patients with schistosomiasis mansoni.

However, in a study by Mohammed, *et al*<sup>22</sup> among 216 patients with schistosoma mansoni infection, non-specific abdominal pain was the most common symptom observed (39%), with diarrhoea being the second most common symptom observed in 27% of their patients. It therefore shows that, diarrhoea is one of the major symptoms of colonic schistosomiasis. This should be borne in mind and considered as a possible differential diagnosis especially in endemic areas for schistosomiasis like Africa.

In our patient, the colonoscopic finding of multiple polypoid masses was not suggestive of schistosomiasis until the histology report confirmed it. This emphasizes the importance of good pathology laboratory back up following endoscopic biopsies.

Colonoscopic appearance in colonic schistosomiasis varies depending on the duration and stage of the

disease. Cao J, *et al*<sup>20</sup> observed that acute inflammation which include mucosa oedema with exudates, petechial haemorrhage, mucosa erythema and granularity with ulcers was common in the right colon, while chronic inflammation which include nodular lesions, polyps, intestinal stricture and mucosal pallor is usually seen in the left colon. This is true of our patient who was found to have multiple polypoid lesions in the rectosigmoid colon.

In the study by Mohammed, *et al*,<sup>22</sup> majority of the patients (55%) had normal colonoscopy, 42% had features of acute disease, while only 4% had polyps. It is possible that, majority of these patients presented in the early stage of their disease and so had no features of chronicity on colonoscopy, in contrast to our patient who presented with features of longstanding disease. In the diagnosis of schistosomiasis, the gold standard is microscopic examination of faeces for the eggs.<sup>23</sup> This was the case with our patient in whom stool microscopy, based on the characteristics of the eggs, described the particular specie of the worm seen on histology.

Although, stool examination is described as the gold standard, it is good to note that ova are passed frequently in the stool only in the early stages, but this becomes scanty and infrequent as the disease progresses into chronicity.<sup>24</sup> So, not in all cases will the stool microscopy detect eggs. The resolution of the symptoms in our patient after receiving medical treatment could support the diagnosis of schistosomiasis in this case. Although, documentation of colonic polyp regression would have been more convincing, but, this was not feasible in our patient since he was lost to further follow up.

## CONCLUSION

Colonic schistosomiasis could be considered as one of the differential diagnoses in a patient presenting with chronic diarrhoea and polypoid masses in the rectosigmoid colon, especially if other common causes of colonic polyps have been excluded.

## REFERENCES

1. **Mahmoud AAF.** Schistosomiasis and other Trematode Infections. In: Fauci AS, Braunwald E, Kasper DL, Hauser SL, Longo DL, Jameson JL, Loscalzo J, eds. Harrison's Principles of Internal Medicine, 7<sup>th</sup> edition. New York: Mc Graw Hill Medical. 2008: 1330-1334
2. **Elliot DE.** Intestinal Infections by Parasitic Worms. In: Feldman M, Friedman LS, Sleisenger MH, eds. Sleisenger & Fordtran's Gastrointestinal and Liver Disease, 7<sup>th</sup> edition, volume II. Philadelphia: Saunders. 2002: 1965-1969

3. **El-sebai I.** Advanced bilharzial intestinal manifestations. The relation to cancer. *Kasr-El-Aini J Surg* 1961; 2: 905-933
4. **Itzkowitz SH.** Colonic Polyps and Polyposis Syndromes. In: Feldman M, Friedman LS, Sleisenger MH, editors. *Sleisenger & Fordtran's Gastrointestinal and Liver Disease*, 7<sup>th</sup> Edition, Philadelphia: Saunders; 2002. 2175-2214
5. **Teague RH, Read AE.** Polyposis in ulcerative colitis. *Gut* 1975;16:792-795
6. **Berkowitz D, Bernstein LH.** Colonic pseudopolyps in association with amebic colitis. *Gastroenterology* 1975;68:786-789
7. **Nebel OT, El-Masry NA, Castell DO, et al.** Schistosomal disease of the colon: A reversible form of polyposis. *Gastroenterology* 1974;67: 939-943
8. **Gryseels B, Polman K, Clerinx J, Kestens L.** Human Schistosomiasis. *Lancet* 2006; 368: 1106-1118
9. **Bottieau E, Clerinx J, De Vega MR, et al.** Imported katayama fever: clinical and biological features at presentation and during treatment. *J. Infect* 2006; 52: 339-345
10. **Lambertucci JR.** Acute schistosomiasis: clinical, diagnostic and therapeutic features. *Rev Inst Med Trop Sao Paulo* 1993; 35: 399-404
11. **King CL, Malhotra I, Mungai P, et al.** B cell sensitization to helminthic infection develops in utero in humans. *J Immunol* 1998; 160: 3578-3584
12. **Hatz C.** Schistosomiasis: an underestimated problem in industrialized countries? *J Travel Med.* 2005; 12: 1-2
13. **Jelinek T, Nothdurft HD, Loscher T.** Schistosomiasis in travelers and expatriates. *J. Travel Med.* 1996; 3: 160-164
14. **Cheever AW, Kamel IA, Elwi AM, et al.** Schistosoma mansoni and S. Haematobium infection in Egypt, III: extrahepatic pathology. *Am J Trop Med Hyg.* 1978; 27: 55-75
15. **Cheever AW.** A quantitative post-mortem study of schistosomiasis mansoni in man. *Am J Trop Med Hyg.* 1968; 17: 38-64
16. **Gryseels B.** The relevance of schistosomiasis for public health. *Trop Med Parasitol.* 1989; 40: 134-142
17. **Chen MG, Mott KE.** Progress in assessment of morbidity due to schistosoma mansoni infection: a review of recent literature. *Trop Dis Bull* 1988; 85: R1-56
18. **Guyatt H, Gryseels B, Smith T, Tanner M.** Assessing the public health importance of schistosoma mansoni in different endemic areas: attributable fraction estimates as an approach. *Am J Trop Med Hyg.* 1995; 53: 660-667
19. **Booth M, Guyatt HL, Li Y, Tanner M.** The morbidity attributable to schistosoma japonicum infection in 3 villages in Dongting Lake region, Hunan province, PR China. *Trop Med Int Health* 1996; 1: 646-654
20. **Cao J, Liu W, Xu X, Zou X.** Endoscopic findings and clinicopathologic characteristics of colonic schistosomiasis: A report of 46 cases. *World J Gastroenterol.* 2010; 16(6): 723-727
21. **Rocha MO, Pedrosa ER, Lambertucci JR, et al.** Gastrointestinal manifestations of the initial phase of schistosomiasis mansoni. *Ann Trop Med Parasitol.* 1995; 89(3): 271-278
22. **Mohammed AE, Al Karawi MA, Yasawy MI.** Schistosomal colonic disease. *Gut* 1990; 31: 439-442
23. **Feldmeier H, Poggensee G.** Diagnostic techniques in schistosomiasis control: a review. *Acta Trop.* 1993; 52: 205-220
24. **Turne AJ.** Diagnosis of schistosoma mansoni infection by rectal scraping: a comparison with rectal biopsy and faecal examination. *Am J Trop Med.* 1962; 11: 620-624