

Full Length Research Paper

The potential role of flaxseed oil on lead acetate-induced kidney injure in adult male albino rats

Ahmed E. Abdel-Moneim^{1*}, Mohamed A. Dkhil^{1,2} and Saleh Al-Quraishy²

¹Department of Zoology and Entomology, Faculty of Science, Helwan University, Egypt.

²Department of Zoology, College of Science, King Saud University, Riyadh, Saudi Arabia.

Accepted 18 January, 2011

Lead (Pb⁺²) intoxication may initiate many disorders in humans and animals. This study investigated the role of flaxseed oil in protecting rats against Pb⁺² exposures. The results showed that the administration of flaxseed oil efficiently protected albino rats against the Pb⁺² caused injury, as revealed by some improvement in the histological structure of kidney as well as the restoration of the body weights loss of Pb⁺² treated animals. At the same time, flaxseed oil decreased the levels of serum creatinine, blood urea nitrogen, uric acid, lipid peroxidation and nitric oxide production with concomitant elevation in glutathione, catalase, superoxide dismutase, glutathione reductase, glutathione-S-transferase and glutathione peroxidase activities. Thus, this study suggests the possibility of flaxseed oil usefulness in limiting toxicant induced by environmental heavy metals.

Key words: Lead, flaxseed oil, kidney, albino rat.

INTRODUCTION

Lead (Pb⁺²), a heavy metal, has continued to pose health hazards in animals and humans in many parts of the world (Navarro-Moreno et al., 2009). Many people who are exposed to gasoline, paints and exhaust fumes from automobile through inhalation, oral or dermal route have suffered from lots of health problems (Ademuyiwa et al., 1994).

Lead is a non-threshold multi-targeted toxicant that causes alterations in different organs of the body, including the kidney (Jarrar, 2003; Senapati et al., 2001). The absorbed lead is conjugated in the liver and passed to the kidney, where a small quantity is excreted in urine and the rest accumulates in various body organs and interferes with their function, specially the kidney as a target site for lead toxicity (Jarrar, 2003; Victory et al., 1986).

Several chelating agents have been used to reduce the burden of the toxic effect of lead, but these have also produced a toxic potential themselves. This has necessitated researches into the therapeutic potential of various medicinal plants and herbs (Senapati et al., 2001).

Flaxseed, *Linum usitatissimum* has been the focus of increased interest in the field of diet and disease research due to the potential health benefits (Abdel-Moneim et al., 2010a) associated with some of its biologically active components. It contains 32 to 45% of its mass as oil of which 51 to 55% is alpha-linolenic acid (18:3 n-3 omega-3 fatty acid), a precursor to eicosapentanoic and docosahexanoic acid and it may have beneficial effects on health and in control of chronic diseases (Mantzioris et al., 1994), as well as being a good source of dietary fiber and lignan.

The study aimed to evaluate the influence of Pb⁺² toxicity in renal tissues of albino rat and to estimate the protective role of flaxseed against this induced toxicity.

MATERIALS AND METHODS

Animals and experimental design

Male albino rats weighing 120 to 150 g were obtained from The Holding Company for Biological Products and Vaccines (VACSERA, Cairo, Egypt). Rats were provided with water and balanced diet *ad libitum*. The experiments were approved by the state authorities and followed Egyptian rules on animal protection. Twenty-four adult male albino rats were randomly allocated to four groups of six rats each. The first group served as vehicle control (Con) and received 0.3 ml saline/rat by oral administration. The second group (Pb⁺²)

*Corresponding author. E-mail: aest1977@hotmail.com. Tel: (+2) 0103499114.

received intraperitoneal (i.p.) injection of 100 µl of lead acetate (20 mg/kg) for 5 days (Ito et al., 1985). The third group received 0.3 ml of flaxseed oil (FSO) by gavages (orally) once daily for 5 days at a dose of 1000 mg/kg (Bhatia et al., 2007) and the animals of group four (Pb⁺²+FSO) received 0.3 ml flaxseed oil by gavages once daily for 5 days at a dose of 1000 mg/kg body weight. An hour after the treatment with flaxseed oil, the fourth group was intraperitoneally injected with 100 µl of lead acetate (20 mg/kg) for 5 days.

Kidney index

At the end of the experimental period, each rat was weighted. The left kidney was then removed and weighed. Finally, the kidney index was calculated by dividing left kidney weight by body weight and then multiplying it by 100.

Histological examination

Pieces of kidney were fixed in 10% neutral-buffered formalin, embedded in paraffin, and sectioned. The sections were stained with ordinary haematoxylin and eosin.

Biochemical estimations

After 24 h from the last i.p. injection of lead acetate, the animals of all groups were civically dislocated; blood samples were collected, allowed to stand for half an hour and then centrifuged at 500 g for 15 min at 4 °C to separate serum and stored at -70 °C. Part of kidney was weighed and homogenized immediately to give 50% (w/v) homogenate in ice-cold medium containing 50 mM Tris-HCl and 300 mM sucrose (Tsakiris et al., 2004). The homogenate was centrifuged at 500 g for 10 min at 4 °C. The supernatant (10%) was used for the various biochemical determinations.

Kidney function test

Uric acid (UA), blood nitrogen urea (BNU) and serum creatinine (Cr) were assayed in the serum using kits provided from Biodiagnostic Co. (Giza, Egypt).

Determination of lipid peroxidation and nitrite/nitrate

Malondialdehyde (MDA) and nitrite/nitrate were assayed colorimetrically in kidney tissue homogenate according to the method of Ohkawa et al. (1979) and Berkels et al. (2004), respectively where MDA was determined by using 1 ml of trichloroacetic acid (10%) and 1 ml of thiobarbituric acid (0.67%) which were then heated in a boiling water bath for 30 min. Thiobarbituric acid reactive substances were determined by the absorbance at 535 nm and expressed as the malondialdehyde (MDA) formed. Nitric oxide was determined, where in an acid medium and in the presence of nitrite, the formed nitrous acid diazotise sulphanilamide was coupled with N-(1-naphthyl) ethylenediamine. The resulting azo dye had a bright reddish-purple color which can be measured at 540 nm.

Estimation of reduced glutathione and anti-oxidant enzymes

The renal reduced glutathione (GSH) was determined by the methods of Ellman (1959). The method based on the reduction of Ellman's reagent (5,5'-dithiobis (2-nitrobenzoic acid) "DTNB") with GSH produced a yellow compound. The reduced chromogen

directly proportional to GSH concentration absorbance was measured at 405 nm. In addition, the level of renal antioxidant as catalase (CAT), superoxide dismutase (SOD), glutathione-S-transferase (GST), glutathione peroxidase (GPx) and glutathione reductase (GR) levels were determined by the methods of Aebi (1984), Nishikimi et al. (1972), Habig et al. (1974), Paglia and Valentine (1967) and Factor et al. (1998), respectively.

Statistical analysis

Data were presented as means ± standard errors. One-way ANOVA was carried out, and the statistical comparisons among the groups were performed with Duncan's test using a statistical package program (SPSS version 17.0).

RESULTS

Rats administered lead acetate had a significant increase ($p < 0.05$) in the kidney index where the body weight decreased and this led to a decrease in the kidney weight (Figure 1). Flaxseed oil caused a non-significant reduction in this altered change in kidney index due to lead administration.

Treatment of rats with lead acetate induced marked alterations in renal tissues when compared to the non-treated control group (Figure 2: a1, a2). These changes were in the form of tubular dilatation, vacuolar and cloudy epithelial cells lining, interstitial inflammatory cells and appearance of some cellular debris (Figure 2: b1, b2). The renal tubules contain some apoptotic nuclei (Figure 2: b2). Flaxseed oil which has no histopathological effects in renal tissue of rats (Figure 2: c1, c2) when used for treatment of rats already administered lead acetate, somewhat improved the kidney histology but the renal tubular epithelium was still vacuolated and some glomeruli were shrunken (Figure 2: d1, d2).

The levels of uric acid, blood urea nitrogen and creatinine were significantly elevated in the serum of rats administered Pb⁺² (35.7, 55.6 and 32.0, $p < 0.05$), respectively (Figure 3). On the other hand, rats administered flaxseed oil only showed a non-significant change in uric acid and creatinine, while blood urea nitrogen was significantly decreased by -27.0%. Rats administered lead acetate and treated with flaxseed oil had a significant decreased level of the earlier mentioned parameters.

Administration of Pb⁺² caused a significant elevation in nitrite/nitrate and MDA levels of kidney homogenate (60.7 and 56%, $p < 0.05$, respectively) and blood serum (66.6 and 46.2%, respectively). Rats administered Pb⁺² with flaxseed oil induced a significant decrease of the two parameters (Table 1). Pb⁺² administration led to a significant decrease in the GSH level in the kidney homogenate of rats by -25.6 and -27.9%, respectively (Table 2). However, treatment with flaxseed oil recovered the Pb⁺²-induced serum and kidney GSH depletion.

In addition, the activity of the antioxidant enzymes CAT, SOD, GST, GPx and GR measured in renal homogenate of rats were decreased by -46.6, -29.5, -39.5, -27.4

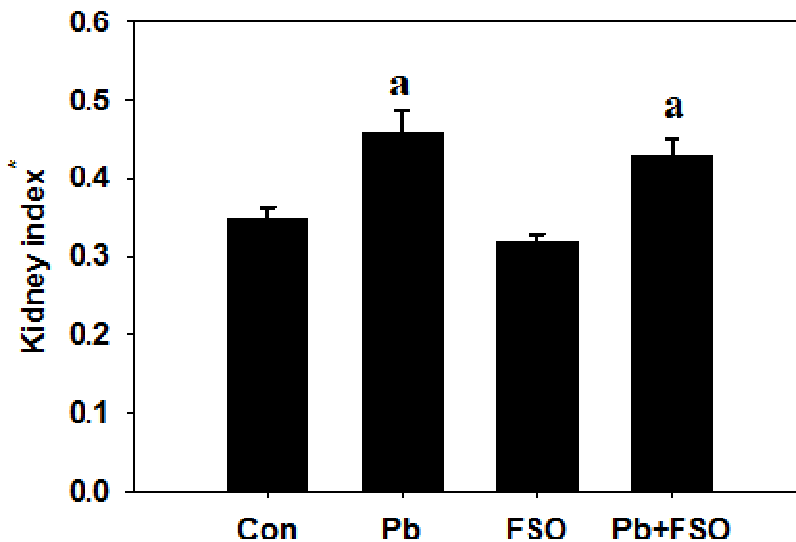


Figure 1. Increase in kidney index of albino rats treated with lead acetate for 5 days. Values are means ± SE (n = 6). a, Significant change at p < 0.05 with respect to the control group. *Ratio of kidney weight in g/rat to body weight in g/rat.

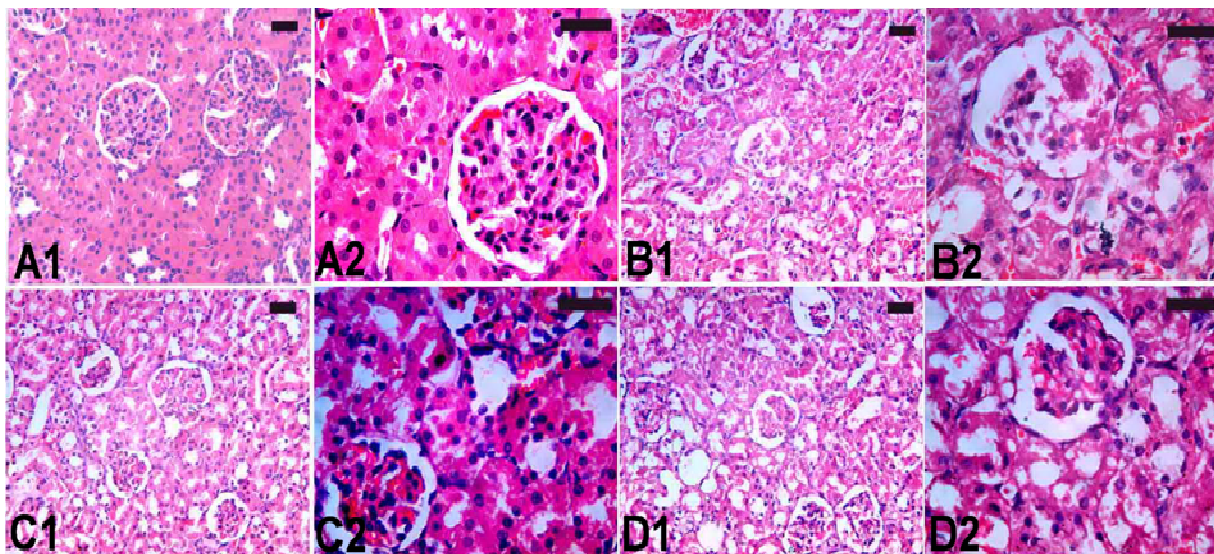


Figure 2. Flaxseed oil improved Pb²⁺renal tissue damage. a1, a2; control kidney sections with normal architecture; b1, b2; rats treated with lead acetate with tubular dilatation, vacuolar and cloudy in epithelial cells lining, interstitial inflammatory cells and appearance of some cellular debris; c1, c2; rats treated with flaxseed oil; d1, d2; rats treated with the lead acetate and flaxseed oil. Sections were stained with hematoxylin and eosin. Bar = 25 µm.

and -36.5%, respectively, on 5 days post-lead acetate treatment. These previous enzymes were significantly elevated upon treatment with flaxseed oil (Table 2).

DISCUSSION

Kidney is a target organ for lead toxicity. The toxic effects

of Pb²⁺ on the kidney appear to be primarily localized in the kidney tubule and are manifested as excessive urinary excretion of amino acids, glucose and phosphate, natriuresis, kaliuresis and intranuclear bodies inclusion (Jadhav et al., 2007). These changes may be related to one or more factors, including increased serum levels or decreased ion reabsorption by alteration in tubular transport mechanisms, as well as structural lesions in the

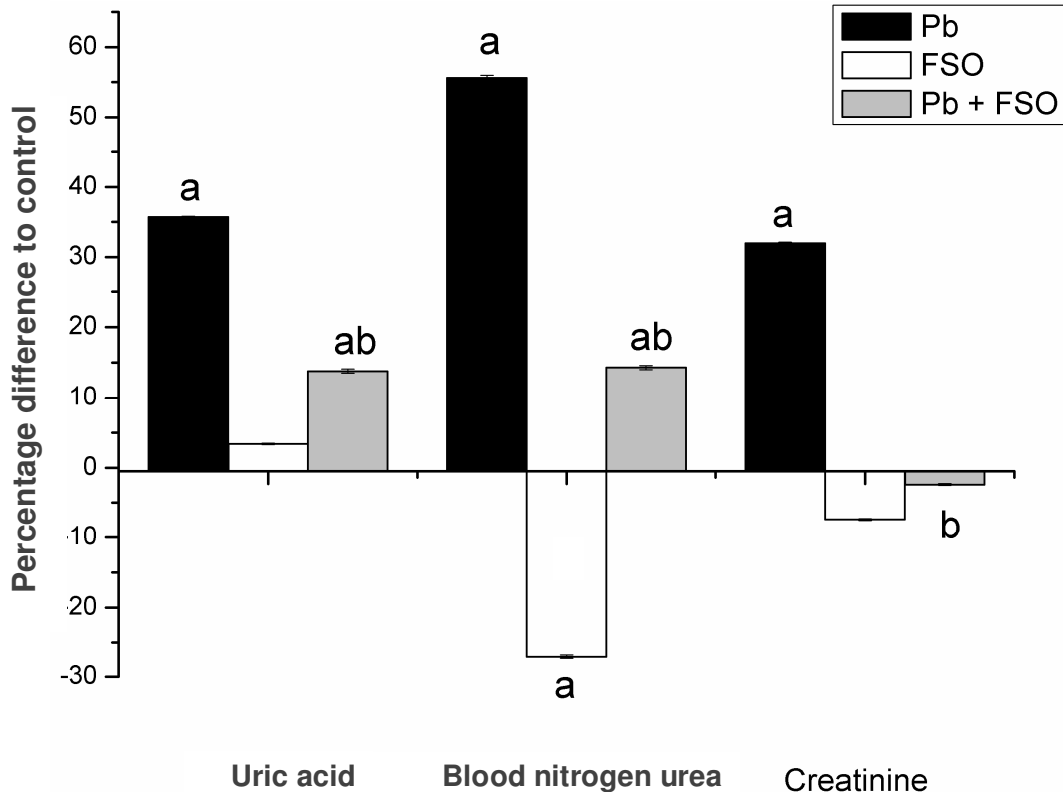


Figure 3. Changes in the levels of uric acid, blood nitrogen urea and creatinine in serum of male albino rats treated with lead acetate and lead acetate + flaxseed oil. Values are means \pm SE (n = 6). a, Significant change at $p < 0.05$ with respect to control group; b, significant change at $p < 0.05$ with respect to Pb^{2+} group.

Table 1. Effect of flaxseed oil on the level of nitrite/nitrate and malondialdehyde in kidney and blood serum of albino rats treated with lead acetate.

Group	Nitrite/nitrate		Malondialdehyde	
	$\mu\text{mol/g kidney}$	$\mu\text{mol/L Blood serum}$	$\mu\text{mol/g kidney}$	$\mu\text{mol/L Blood serum}$
Control	132.89 \pm 12.11	39.16 \pm 1.53	104.46 \pm 5.52	16.88 \pm 0.27
Pb^{2+}	213.53 \pm 9.79 ^a	65.23 \pm 4.98 ^a	162.96 \pm 5.89 ^a	24.68 \pm 1.36 ^a
FSO	37.50 \pm 1.70	95.51 \pm 12.09 ^a	96.15 \pm 2.71	17.19 \pm 1.05
Pb^{2+} +FSO	131.70 \pm 12.96 ^b	53.33 \pm 3.33 ^{ab}	138.37 \pm 7.33 ^{ab}	21.90 \pm 1.09 ^{ab}

Values are means \pm SE (n = 6). a, Significant change at $p < 0.05$ with respect to control group; b, significant change at $p < 0.05$ with respect to Pb^{2+} group; FSO, flaxseed oil.

nephron (Franks et al., 1989). Also, Goyer (1971) observed an increase in kidney wet weight in rats given a high dose of lead for protracted periods of time, while O'Flaherty et al. (1986) observed increases in both kidney wet weight and dry weight in rats given, varying doses of lead. These findings were in agreement with the findings concerning the reduced kidney index of rats due to lead acetate administration. The current results clearly indicated that treatment with flaxseed oil did not induce any harmful effects on the animals. Moreover, it successfully induced an improvement in the body weight.

Histological investigations revealed that Pb^{2+} exposure resulted in progressive glomerular and tubular alterations. These findings are in agreement with the results of previous investigations by Lin et al. (1993) who recorded alterations in renal histopathology due to environmental exposure to Pb^{2+} . Tubular vacuolization, necrosis and dilation found in the present studies due to Pb^{2+} intoxication were reported previously by Karmakar et al. (1986). These tubular alterations due to Pb^{2+} toxicity might be as a result of a hydrolytic change in the renal tissue and this suggests that Pb^{2+} intoxication causes a

Table 2. Changes in the levels of GSH, CAT, SOD, GST, GPx and GR in kidney homogenate of male albino rats treated with lead acetate and lead acetate + flaxseed oil.

Group	GSH (mmol/g tissue)	CAT (U/g tissue)	SOD (U/g tissue)	GST (μ mol/h/ g tissue)	GPx (U/g tissue)	GR (μ mol/ g tissue)
Control	0.86 \pm 0.06	1.89 \pm 0.12	5.62 \pm 0.34	2.05 \pm 0.05	1.35 \pm 0.04	33.92 \pm 0.98
Pb ²⁺	0.62 \pm 0.01 ^a	1.01 \pm 0.08 ^a	3.96 \pm 0.21 ^a	1.24 \pm 0.06 ^a	0.98 \pm 0.02 ^a	21.54 \pm 1.76 ^a
FSO	0.81 \pm 0.01	1.93 \pm 0.1	5.94 \pm 0.36	2.14 \pm 0.06	1.54 \pm 0.06	38.28 \pm 1.36
Pb ²⁺ +FSO	0.68 \pm 0.04 ^a	1.22 \pm 0.08 ^{ab}	4.21 \pm 0.34 ^a	1.32 \pm 0.09 ^a	1.02 \pm 0.07 ^a	20.79 \pm 1.08 ^a

Values are means \pm SE (n = 6). a, Significant change at p < 0.05 with respect to control group; b, significant change at p < 0.05 with respect to Pb²⁺ group; FSO, flaxseed oil.

partial failure in the ion pump transport of tubules cells which in turn produces tubular swelling and causes necrosis and vacuolization of the tubules. Flaxseed oil could improve to some extent, the altered kidney histopathology.

The induced elevation of the uric acid, blood urea nitrogen and creatinine due to lead acetate administration indicated that the kidney function was affected. The results of the study proved that, treatment with flaxseed oil significantly improved the kidney function. Oxidative stress may be as a result of excessive reactive oxygen species generation or failure of the cellular antioxidant system. Lead induced an elevation of oxidative stress indicators as nitrite/nitrate of kidney, where it was explained by Gonick et al. (1997) and the increased inducible nitric oxide synthase (iNOS) in the kidney cortex of lead-treated rats was demonstrated.

Lipid peroxidation is one of the main manifestations of oxidative damage and has been found to play an important role in the toxicity of many xenobiotics, and also it alters physiological and biochemical characteristics of biological systems (Anane and Creppy, 2001). Valverde et al. (2001) found induction of lipid peroxidation and increased reactive oxygen species (ROS) level in tissues of mice after intoxication with lead acetate for 1 h. Their findings are in agreement with the results obtained by Marchlewicz et al. (2007), suggesting the induction of Pb²⁺ cytotoxicity by indirect mechanisms. The investigations in this study showed significantly increased concentration of MDA in serum and kidney homogenate of lead-exposed rats.

Cervello et al. (1992) suggested that GST enzyme catalyzes the reaction via the thiol (-SH) group of glutathione, thereby neutralizing and rendering the products more water-soluble. Taking into account mutual relations between GST and GSH in the redox system, the simultaneous decrease in both GST activity and GSH concentration may suggest that the decrease in renal GSH concentration might result, at least partly, from the decrease in GST activity (Newairy and Abdou, 2009). The decrease in GST activity after exposure to lead could be caused by lead-induced changes in the enzyme structure as well as by the lack or insufficient amount of GSH, being a substrate for this enzyme (Neal et al., 1999).

Glutathione reductase, the enzyme responsible for recycling of glutathione from the oxidized form (glutathione disulfide; GSSG) to the reduced form (reduced glutathione; GSH) was also deactivated by lead (Table 2).

Flaxseeds have received increased attention for their potential role in preventing lipid disorders (Abdel-Moniem et al., 2010b). However, relatively few data are available regarding the impact of flaxseed oil on blood and kidney. The phenolic lignans and other phytoestrogens have antioxidant activity (Kitts et al., 1999). The more striking finding in this study is that the presence of flax lignans with lead acetate alleviated its harmful effects on the levels of GSH and on the activities of GPx, GR, SOD and GST enzymes. The corrected levels of these parameters were observed likely to near normal values of the control group. Flaxseed is the richest source of lignans, which have also been reported to have antioxidant and hypolipidemic effects (Newairy and Abdou, 2009).

In this study, co-treatment of Pb²⁺ and flaxseed oil resulted in a significant improvement in the histological picture of the kidney as well as the kidney function. Therefore, this oil may play a protective role against Pb²⁺ mediated kidney injury.

ACKNOWLEDGEMENT

This work was supported by the Centre of Excellence for Biodiversity Research, College of Science, King Saud University, Riyadh, Saudi Arabia.

REFERENCES

- Abdel-Moneim A, Dkhil M, Al-Quraishy S (2010a). The Redox Status in Rats Treated with Flaxseed Oil and Lead-Induced Hepatotoxicity. *Biological Trace Element Res.* [Epub ahead of print].
- Abdel-Moniem AE, Dkhil MA, Al-Quraishy S (2010b): Protective role of flaxseed oil against lead acetate induced oxidative stress in testes of adult rats. *Afr. J. Biotechnol.* 9(42): 7216-7223.
- Ademuyiwa O, Adesanya O, Ajuwon OR (1994). Vitamin C in CC14 hepatotoxicity-a preliminary report. *Hum. Exp. Toxicol.* 13: 107-109.
- Aebi H (1984). Catalase *in vitro*. *Methods Enzymol.* 105: 121-126.
- Anane R, Creppy EE (2001). Lipid peroxidation as pathway of aluminium cytotoxicity in human skin fibroblast cultures: prevention by superoxide dismutase+catalase and vitamins E and C. *Hum. Exp.*

- Toxicol. 20: 477-481.
- Berkels R, Purol-Schnabel S, Roesen R (2004). Measurement of nitric oxide by reconversion of nitrate/nitrite to NO. *Methods Mol. Biol.* 279: 1-8.
- Bhatia AL, Sharma A, Patni S, Sharma AL (2007). Prophylactic effect of flaxseed oil against radiation-induced hepatotoxicity in mice. *Phytother. Res.* 21: 852-859.
- Cervello I, Lafuente A, Giralt M, Mallol J (1992). Enhanced glutathione S-transferase (GST) activity in pregnant rats treated with benzo(a)pyrene. *Placenta.* 13: 273-280.
- Ellman GL (1959). Tissue sulfhydryl groups. *Arch. Biochem. Biophys.* 82: 70-77.
- Factor VM, Kiss A, Woitach JT, Wirth PJ, Thorgeirsson SS (1998). Disruption of redox homeostasis in the transforming growth factor- α /c-myc transgenic mouse model of accelerated hepatocarcinogenesis. *J. Biol. Chem.* 273: 15846-15853.
- Franks PA, Laughlin NK, Dierschke DJ, Bowman RE, Meller PA (1989). Effects of lead on luteal function in rhesus monkeys. *Biol. Reprod.* 41: 1055-1062.
- Gonick HC, Ding Y, Bondy SC, Ni Z, Vaziri ND (1997). Lead-induced hypertension: interplay of nitric oxide and reactive oxygen species. *Hypertension.* 30: 1487-1492.
- Goyer RA (1971). Lead and the kidney. *Curr. Trop. Pathol.* 55: 147-176.
- Habig WH, Pabst MJ, Jakoby WB (1974). Glutathione S-transferases. The first enzymatic step in mercapturic acid formation. *J. Biol. Chem.* 249: 7130-7139.
- Ito Y, Niiya Y, Kurita H, Shima S, Sarai S (1985). Serum lipid peroxide level and blood superoxide dismutase activity in workers with occupational exposure to lead. *Int. Arch. Occup. Environ. Health.* 56: 119-127.
- Jadhav SH, Sarkar SN, Patil RD, Tripathi HC (2007). Effects of subchronic exposure via drinking water to a mixture of eight water-contaminating metals: a biochemical and histopathological study in male rats. *Arch. Environ. Contamin. Toxicol.* 53: 667-677.
- Jarrar BM (2003). Histological and histochemical alterations in the kidney induced by lead. *Ann. Saudi. Med.* 23: 10-15.
- Karmakar N, Saxena R, Anand S (1986). Histopathological changes induced in rat tissues by oral intake of lead acetate. *Environ. Res.* 41: 23-28.
- Kitts DD, Yuan YV, Wijewickreme AN, Thompson LU (1999). Antioxidant activity of the flaxseed lignan secoisolariciresinol diglycoside and its mammalian lignan metabolites enterodiol and enterolactone. *Mol. Cell Biochem.* 202: 91-100.
- Lin JL, Yeh KH, Tseng HC, Chen WY, Lai HH, Lin YC (1993). Urinary N-acetyl-glucosaminidase excretion and environmental lead exposure. Green Cross Health Service Association Study Group. *Am. J. Nephrol.* 13: 442-447.
- Mantzioris E, James MJ, Gibson RA, Cleland LG (1994). Dietary substitution with an alpha-linolenic acid-rich vegetable oil increases eicosapentaenoic acid concentrations in tissues. *Am. J. Clin. Nutr.* 59: 1304-1309.
- Marchlewicz M, Wiszniewska B, Gonet B, Baranowska-Bosiacka I, Safranow K, Kolasa A, Glabowski W, Kurzawa R, Jakubowska K, Rac ME (2007). Increased lipid peroxidation and ascorbic Acid utilization in testis and epididymis of rats chronically exposed to lead. *Biometals.* 20: 13-19.
- Navarro-Moreno LG, Quintanar-Escorza MA, Gonzalez S, Mondragon R, Cerbon-Solorzano J, Valdes J, Calderon-Salinas JV (2009). Effects of lead intoxication on intercellular junctions and biochemical alterations of the renal proximal tubule cells. *Toxicol. In Vitro.* 23: 1298-1304.
- Neal R, Cooper K, Kellogg G, Gurer H, Ercal N (1999). Effects of some sulfur-containing antioxidants on lead-exposed lenses. *Free Radic. Biol. Med.* 26: 239-243.
- Newairy AS, Abdou HM (2009). Protective role of flax lignans against lead acetate induced oxidative damage and hyperlipidemia in rats. *Food Chem. Toxicol.* 47(4): 813-818.
- Nishikimi M, Appaji N, Yagi K (1972). The occurrence of superoxide anion in the reaction of reduced phenazine methosulfate and molecular oxygen. *Biochem. Biophys. Res. Commun.* 46: 849-854.
- O'Flaherty EJ, Adams WD, Hammond PB, Taylor E (1986). Resistance of the rat to development of lead-induced renal functional deficits. *J. Toxicol. Environ. Health.* 18: 61-75.
- Ohkawa H, Ohishi N, Yagi K (1979). Assay for lipid peroxides in animal tissues by thiobarbituric acid reaction. *Anal. Biochem.* 95: 351-358.
- Paglia DE, Valentine WN (1967). Studies on the quantitative and qualitative characterization of erythrocyte glutathione peroxidase. *J. Lab. Clin. Med.* 70: 158-169.
- Senapati SK, Dey S, Dwivedi SK, Swarup D (2001). Effect of garlic (*Allium sativum* L.) extract on tissue lead level in rats. *J. Ethnopharmacol.* 76: 229-232.
- Tsakiris S, Schulpis KH, Marinou K, Behrakis P (2004). Protective effect of L-cysteine and glutathione on the modulated suckling rat brain Na⁺, K⁺, -ATPase and Mg²⁺ -ATPase activities induced by the *in vitro* galactosaemia. *Pharmacol. Res.* 49: 475-479.
- Valverde M, Trejo C, Rojas E (2001). Is the capacity of lead acetate and cadmium chloride to induce genotoxic damage due to direct DNA-metal interaction? *Mutagenesis.* 16: 265-270.
- Victory W, Miller CR, Goyer RA (1986). Essential trace metal excretion from rats with lead exposure and during chelation therapy. *J. Lab. Clin. Med.* 107: 129-135.