

Original Article

The Effects of Oleuropein and Vitamin C on Diabetic Nephropathy Induced by Streptozotocin (STZ) In Male Rats

Marium Hussein 

Department of Zoology, Faculty of Science, Omar El-Mokhtar University, Albida, Libya

ARTICLE INFO

Corresponding Email. marium.hussein@omu.edu.ly

Received: 12-04-2021 Accepted: 17-06-2021 Published: 28-06-2021

Keywords: Oleuropein, Vitamin C, Diabetes, Oxidative Stress, Kidney Function.

This work is licensed under the Creative Commons Attribution International License (CC BY 4.0).

<http://creativecommons.org/licenses/by/4.0/>

ABSTRACT

Aims. In the present study, we aimed to examine the efficacy of oleuropein and vitamin C in reducing the metabolic abnormalities kidney function accompanied to streptozotocin-induced diabetes in male albino rats. The antioxidants, such as phenolic compound oleuropein and Vitamin C play important roles in improve cell function and protect the affected tissues. **Methods.** The present work was designed to study the effects of oleuropein and vitamin C of diabetic nephropathy in male rats. Diabetes was induced by a single i.p. dose of STZ (40 mg/kg b.w.). Pure oleuropein compound (5 mg/kg b.w.) and vit.C (150 mg/kg b.w.) was orally administered once per a day for 15 days after diabetes induction. **Results.** Oleuropein and Vitamin C have been observed to keep creatinine, urea, uric acid and kidney function near normal levels compared to very high levels in the diabetic group, and improvement total protein globulin and albumin. **Conclusion.** Oleuropein and vitamin C significantly attenuated the oxidative status of diabetic rats. In addition, improved the different changes kidney tissue in diabetic rats treated with oleuropein and vitamin C compared with diabetic rat.

Cite this article: Hussein M. The effect of oleuropein and vitamin c on diabetic nephropathy induced by streptozotocin (STZ) in male rats. *Alq J Med App Sci.* 2021;4(2):104-113. <http://doi.org/10.5281/zenodo.5036469>

INTRODUCTION

Diabetic nephropathy (DN) affects 30% of all diabetics and it is a leading cause of end stage renal disease (ESRD) [1]. Assessment of a renal function may be used for two different purposes. One is to diagnose impaired renal function, and the other is to detect the presence of a progressive loss of renal function. Abnormal renal function is represented by an abnormality in serum creatinine, urea, uric acid, albumin and globulin [2]. DN is evidenced by proteinuria, decline in glomerular function rate (GFR), hypertension, and has a high risk of cardiovascular morbidity and mortality [3]. In DN, bio-markers viz. Serum creatinine, urea and uric acid (kidney function test) are known to be raised with hyperglycemia in uncontrolled diabetes and usually correlate with severity of kidney damage. Measurement of serum urea and creatinine are easily available tests for this purpose which can assist in detection and prevention diabetic kidney disease at an early stage and can limit the progression to ESRD [4]. Furthermore, overproduction of reactive oxygen species (ROS) and oxidative stress in the DN condition led to enzyme inactivation, redox imbalance, cell membrane injury and cell apoptosis [5-6]. Additionally, excessive ROS induces the mitochondria-dependent apoptotic pathway that is implicated in the pathogenesis of DN [7].

Oleuropein (Ole) a natural bioactive phenolic compound from olive leaves [8], have proved effective recovery from health problems such as antihyperglycemic by improving insulin secretion in the cells of the pancreas and increasing the response of cell receptors to insulin, which leads to the regulation of blood sugar levels [9-10]. In addition to many biological activities, of Ole are antioxidant, anti-inflammatory, anticancer, antidiabetic, cardioprotective, hepatoprotective, neuroprotective, obesity [11], treat kidney damage and improvement kidney functions [12]. Ole is able to reduce oxidative stress which cause renal damages in diabetic rats [13]. This ameliorative property was attributed to the antioxidative [14].

Ascorbic acid, also known as Vitamin C (VitC), is an effective water-soluble antioxidant, which has a scavenging effect on excessive free radicals in the body of diabetic patients and a protective effect on tissue damaged by oxidative stress [15]. Some studies have found that ascorbic acid supplementation can improve islet cell function in patients with diabetic type2 (T2DM), which can be used for the early prevention of diabetes and the later treatment of complications [16]. Furthermore, some studies [17,18], have shown that ascorbic acid supplementation can regulate fasting blood glucose (FBG), glycosylated hemoglobin (HbA1c), improve insulin resistance, nervous, cardiovascular, respiratory, gastrointestinal, coagulation and immune systems in preclinical as well as in clinical studies [19,20]. Therefore, this study was designed to evaluate, examine the efficacy of oleuropein and vitamin C in reducing the metabolic abnormality kidney function accompanied to streptozotocin-induced diabetes in male albino rats.

METHODS

Chemicals

Streptozotocin STZ and oleuropein were obtained commercially from Sigma-Aldrich Co. Germany. L-ascorbic acid (Vitamin C) was purchased from Oxford Laboratory.

Experimental Animals

Wister rats (180±20g) were obtained from the Faculty of Medicine, Alexandria University. The animals were acclimated under laboratory conditions (22-25°C, 12h light/dark cycle and relative humidity) for at least two weeks. The local committee approved the design of the experiments and the protocols were carried out according to the guidelines of the National Institutes of Health (NIH).

Study design and setting

Forty rats were randomly divided into four groups (10 rats each): first the control group: Rats were received intraperitoneally (i.p) single dose 0.2 ml/100 g sodium citrate buffer (0.1M; pH: 4.5) according to [21], and orally administered 0.5 ml of distilled water daily for 15 consecutive days. Diabetic group: Rats were received a single dose of streptozotocin STZ i.p. at a dose of 40 mg/kg b.w. dissolved in sodium citrate buffer (0.1M; pH: 4.5) [22]. Diabetic+Oleuropein group: Diabetic rats were received oleuropein (Ole) orally by gavage at a dose 5 mg/kg [23]. Daily for 15 consecutive days after diabetes induction. Diabetic+Vitamin C group: Diabetic rats were received vitamin C (VitC) orally by gavage at a dose 150 mg/kg [24]. Daily for 15 consecutive days after diabetes induction.

Induction of diabetes

The rats were made to fast overnight before the induction of diabetes by a single intraperitoneal injection of 40 mg/kg b.w. STZ freshly prepared with citrate buffer (pH 4.5). Hyperglycemia was confirmed 3 days after injection by measuring the tail vein blood glucose level with an Accu-Check Sensor Comfort glucometer. Only the animals with fasting blood glucose levels >200 mg/dl were selected for this study [25].

Data collection procedure

At the end of the experimental period, the rats were fasted overnight and killed by decapitation after light chloroform anesthesia. From each rat, 5 ml of blood was collected into dry centrifuge tubes, and allowed to clot at room temperature (24°C-26°C). Thereafter, serum was separated from the clot by centrifuging at 3000 xg for 10 min. The serum was collected in clean bottles and stored at -20°C until required.

Biochemical parameters

Determination of creatinine [26] and urea [27]. Were assayed in serum by diagnostic kit method. Where, uric acid was assayed by the method of Fossati et al. [28]. While Total protein concentration in plasma and protein contents in brain regions was assayed by the method of Gornal et al. [29]. The method described by Doumas, et al., [30]. Was employed for the determination of serum albumin concentration, while serum globulin and albumin concentration were carried out using the method described by Buckley et al. [31]. Using the Biuret method.

Determination of oxidative stress markers and antioxidant enzyme activities

The determination of kidney thiobarbituric acid reactive substance (TBARS) [32], reduced glutathione (GSH) [33]. Was assayed by a spectrophotometer. The activity of superoxide dismutase (SOD; EC 1.15.1.1) and catalase (CAT; EC 1.11.1.6) were estimated in the kidney homogenates according to the method of [34, 35] respectively. In glutathione-S-transferase (GST) determination [36], and activity of glutathione peroxidase (Gpx; EC. 1.1.1.9) [37] enzymes in liver were assayed.

Histopathological examination of the kidney

Kidneys were fixed in 10% formalin, then dehydrated, embedded in paraffin, sectioned to 3–5 µm thickness, deparaffinized and rehydrated. Hematoxylin and Eosin (H&E) dyes were used to stain the kidney tissues. The slides were then observed under light microscope [38].

Statistical analysis

All statistical analyses were conducted by using the statistical package SPSS version 22.0 (Chicago, IL). Values were compared by one-way analysis of variance (ANOVA). Post-hoc testing was performed for inter-group comparisons using the least significant difference (LSD) test at $p \leq 0.05$.

RESULTS

Effects of Ole and Vit. C on the creatinine, urea, uric acid, total protein, albumin and globulin in the serum of male rats

Table (1) showed that diabetic rats displayed a significant increase ($P < 0.05$) in creatinine, urea, uric acid while, total protein, albumin and globulin were significantly ($P \leq 0.05$) decreased compared to control group. However, a significant decrease ($p \leq 0.05$) was observed in the respective creatinine, urea, uric acid and an increase in total protein, albumin and globulin of rats orally given Ole and Vit. C compared with the untreated diabetic group.

Table (1): Effects of Ole and Vit. C on the creatinine, urea, uric acid, total protein albumin and globulin in the serum of male rats

Parameter	Control	Diabetic	Diabetic+Ole	Diabetic+Vit.C
Creatinine (mg/dL)	1.11±0.26	3.15±0.61 ^a	1.52±0.06 ^b	1.77±0.03 ^b
Urea (mg/dL)	46.49±4.84	82.13±4.63 ^a	41.99±3.59 ^{bc}	52.28±1.72 ^b
Uric acid (mg/dL)	4.73±0.63	9.04±0.06 ^a	6.39±0.01 ^{bc}	7.69±0.05 ^b
Total protein (g/dl)	7.93±0.21	6.96±0.13 ^a	7.49±0.14 ^b	7.29±0.10 ^b
Albumin (g/dL)	4.04±0.15	2.89±0.10 ^a	3.89±0.12 ^{bc}	3.18±0.06 ^b
Globulin (g/dL)	4.06±0.15	3.89±0.16 ^a	3.60±0.18 ^b	3.48±0.12 ^b

* The values are expressed as mean±SE. (a, b, c): The mean values are significantly different in comparison with control group ($P\leq 0.05$).

Effects of Ole and Vit. C on oxidative stress markers and antioxidant enzymes in the kidney of diabetic male rats

Table (2) showed that the activities of SOD, CAT, GPx, GST and GSH were significantly ($P\leq 0.05$) decreased while, TBARS was significantly ($P\leq 0.05$) increased in the kidney of untreated diabetic group compared to control group. Oral treatment with Ole and Vit. C caused a significant ($P\leq 0.05$) decrease in the TBARS and an increase in antioxidants level compared to the untreated diabetic group.

Table (2): Effects of Ole and Vit. C on oxidative stress markers and antioxidant enzyme activities in the kidney of diabetic male rats

Parameter	Control	Diabetic	Diabetic+Ole	Diabetic+Vit.C
TBARS (nmol/g tissue)	14.27±0.53	148.08±11.5 ^a	61.57±3.18 ^b	61.57±3.18 ^b
GSH (µmol/g tissue)	43.87±0.86	17.48±1.14 ^a	35.41±1.5 ^{bc}	26.03±0.84 ^b
SOD (U/mg protein)	1.51±0.01	1.18±0.04 ^a	1.33±0.01 ^b	1.23±0.01 ^b
CAT (U/mg protein)	31.61±0.46	16.81±0.18 ^a	21.8±0.41 ^{bc}	20.29±0.33 ^b
GPx (U/mg protein)	2.21±0.09	1.31±0.07 ^a	1.42±0.03 ^b	1.36±0.03 ^b
GST (µmol/min/mg protein)	6.80±0.19	4.78±0.13 ^a	6.14±0.25 ^{bc}	5.97±0.09 ^b

The values are expressed as mean±SE. (a, b, c): The mean values are significantly different in comparison with control group ($P\leq 0.05$).

Histological findings

Figure (1) Light micrograph of kidney sections (H and E, ×40). (A) Control groups showed normal glomeruli (g), of Bowman capsule (b) proximal (px) and distal (ds) convoluted tubules. (H&E X 40), (B) STZ group showed retraction of glomerular tuft (g), thickening of Bowman capsule (b), necrosis in more than 25% of the proximal (Px) and distal tubules (ds), (C) STZ+OLE group and (D) STZ+Vit.C showing the glomerulus (g), of Bowman capsule(b), proximal (Px) and distal (ds) convoluted tubules which appear more or less normal. (H&E X 40).

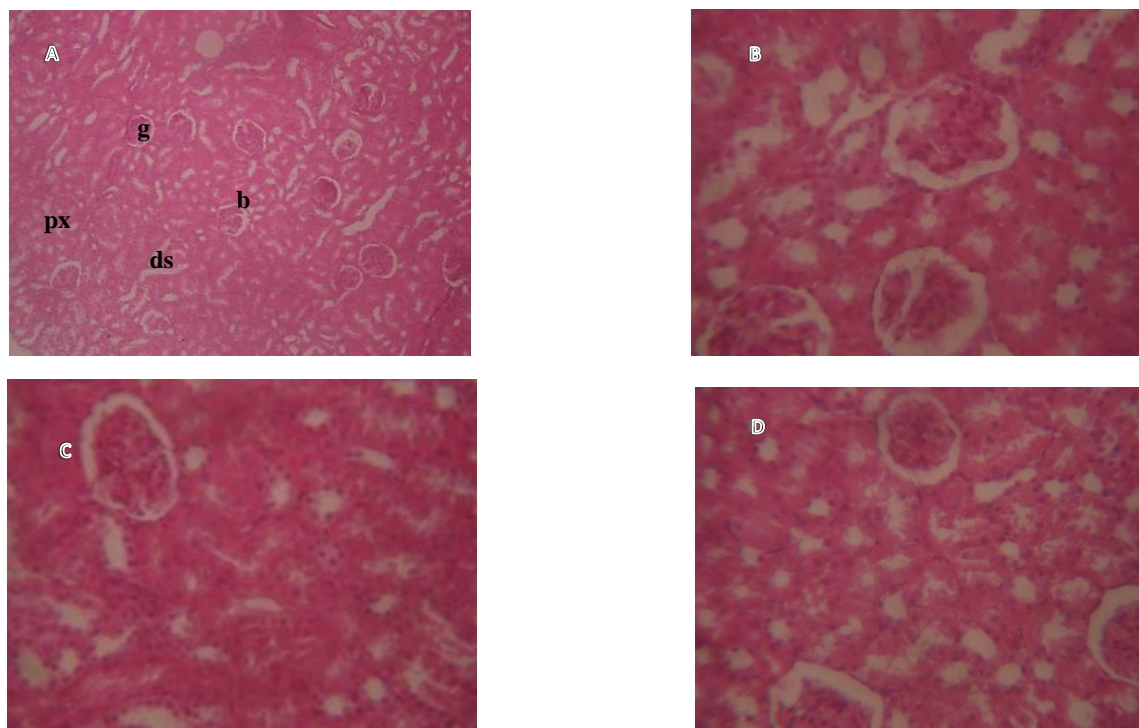


Figure 1. Light micrograph of kidney sections (H and E, ×40). (A) Control groups showed normal glomeruli (g), of Bowman capsule (b) proximal (px) and distal (ds) convoluted tubules. (H&E X 40),

DISCUSSION

In recent years, much attention has been focused on using natural products as an alternative therapy for treatment of many diseases including diabetic nephropathy. In the present study, the increase in creatinine, urea and uric acid concentration in diabetic patients may be related to disturbance of kidney function [39]. The high glucose levels harm millions of nephrons—modest separating units within every kidney. Thus, the kidneys can't keep up the liquid and electrolyte homeostasis and reduces glomerular filtration rate (GFR) [40]. In addition, the high production of urea may result from the increase of protein catabolism in the liver and plasma [41]. Moreover, the increase in uric acid may be related to the decrease in total protein level in diabetic rats, which may have led to muscle wasting and an elevated release of purine, the main source of uric acid [42].

On the other hand, the treated mice subjected to STZ exposure with oleuropein showed reduction in the serum creatinine, urea, and uric acid levels compared to diabetic group. Our results are in agreement with those of Eid et al. [43] may be due to regeneration of kidney glomeruli that improved the kidney filtration process. Thus, this nephroprotective function could be mediated via antioxidant and/or free radical scavenging activities as they possess a high concentration of flavonoids [44].

Antioxidant property of administration of vitamin enhances glomerular filtration rate by an increase in blood flow in the glomeruli [45]. Besides, as a consequence of vitamin C antioxidant action, it may possibly reduce inflammation and body cell damage by free radical [46]. Decreased serum level of uric acid is related to increased amino acid incorporation into tissue, muscle proteins [47].

An overall significant reduction in serum total protein, albumin and globulin in diabetic animals were observed hypoinsulinemia in the present study. This similar to earlier reports recorded by Majekodunmi et al. [48]. Could

be due to massive hepatic necrosis, hepatic dysfunction, intolerance, insulin and glycogen impairment of oxidative phosphorylation, or due to the effect of diabetic kidney failure [49, 50].

In the current study, the elevated levels of serum total proteins, albumin and globulin in diabetic rats treated with oleuropein may be related to the recovery of serum insulin levels. Very close results were obtained by Chandramohan et al. [51].

Ascorbic acid stimulates protein production (total protein, albumin, and globulin) suggesting an important role of the vitamins in the modulation of plasma proteins [52]. Results showed a reduction in SOD, CAT, GPx GST activities, and increase of GSH, leads to increased production of reactive oxygen species (ROS) which are involved in the etiology of several diabetic complications including DN, it changes in cellular structure and function [53] such as renal cell necrosis and mutation in genes that control regulatory proteins of cell proliferation and apoptosis [54]. The results designated a decrease in the antioxidant capacity and an increase in the production of lipid peroxides, which may lead to renal injury [55].

Administration of oleuropein suppresses oxidative stress in the kidney. This fact is proved improvement activities of the antioxidant enzymes CAT, SOD, GST and GPx as well as depletion of lipid peroxidation products (TBARs) [56]. The enhancement of antioxidant statute might be due to the antioxidant power of oleuropein like the majority of bio phenols which offers the ability to reduce the accumulation of free radicals generated during lipid peroxidation protect membranes from lipid oxidation [57, 58].

Vitamin C plays an important role as an antioxidant, efficiently contributes to defense against lipid peroxidation, and scavenges peroxy radicals [59, 60]. Vitamin C scavenges free radicals through the formation of ascorbyl radical and thereby prevents damage to macromolecules such as lipids or the DNA [61].

The structural changes in kidneys could be attributed to altered metabolism in diabetes and the subsequent effects on the increased renal threshold for hyperglycemia [62]. Previous studies on the long-term effects of diabetes in experimental animals show glomerular nephropathy along with tubular and interstitial abnormalities Massive inflammatory infiltrates in the interstitial tissue as well as vacuolar degeneration of tubular epithelial cells and renal glomeruli [63].

Oleuropein that make kidney work normally [64]. Showed less inflammatory reaction in the renal tissues that might be attributed to oleuropein anti-inflammatory effects [65]. In addition, improvement of histological changes and kidney cell dysfunction induced by streptozotocin [66].

Vitamin C plays a central role in the antioxidant protective system and reduce the complications of diabetes, shielding all lipids undergoing oxidation and diminishing the number of apoptotic cells and improved the glomerular functions but did not have any effect on the tubular functions [67].

CONCLUSION

The oleuropein and vitamin C has an effective effect on streptozotocin -induced diabetes male mice by reducing the biochemical and histological parameters in the kidney function due to the action of the antioxidants

Disclaimer

The article has not been previously presented or published, and is not part of a thesis project.

Conflict of Interest

There are no financial, personal, or professional conflicts of interest to declare.

REFERENCES

1. International Diabetes Federation. IDF Diabetes Atlas. 6th ed. Brussels, Belgium: International Diabetes Federation; 2013.
2. Alicic RZ, Rooney MT, Tuttle KR. Diabetic kidney disease. *Clinical Journal of the American Society of Nephrology* 2017; 12(12):2032-2045.
3. DeFronzo RA. From the triumvirate to the "ominous octet": a new paradigm for the treatment of type 2 diabetes mellitus. *Clinical Diabetology*. 2009; 10 (3): 101-128.
4. Seuring T, Archangelidi O, Suhrcke M. The economic costs of type 2 diabetes: a global systematic review. *PharmacoEconomics* 2015; 33(8): 811-831.
5. Peluso I, Raguzzini A. Salivary and urinary total antioxidant capacity as biomarkers of oxidative stress in humans. *Pathology Research International* 2016; 5480214-5480267.
6. Vikram A, Tripathi DN, Kumar A, Singh S. Oxidative stress and inflammation in diabetic complications. *International Journal of Endocrinology* 2014; 679754.
7. Shi JX, Huang Q. Glucagonlike peptide1 protects mouse podocytes against high glucose-induced apoptosis, and suppresses reactive oxygen species production and proinflammatory cytokine secretion, through sirtuin 1 activation in vitro. *Molecular Medicine Reports* 2018; 18(2):1789-1797.
8. Abd El-Rahman HSM. The effect of olive leaf extract and A-Tocopherol on nephroprotective activity in rats. *Nutrition and Food Science* 2016; 6(2): 479.
9. Nan JN, Ververis K, Bollu S, Rodd AL, Swarup O, et al. Biological effects of the olive polyphenol, hydroxytyrosol: An extra view from genomewide transcriptome analysis. *Hellenic Journal of Nuclear Medicine* 2014; 17(1): 62-69.
10. Liu YN, Jung JH, Park H, Kim H. Olive leaf extract suppresses messenger RNA expression of proinflammatory cytokines and enhances insulin receptor substrate 1 expression in the rats with streptozotocin and highfat diet-induced diabetes. *Nutrition Research* 2014; 34(5): 450-457.
11. Sarbishegi M, Gorgich EA, Khajavi O. Olive leaves extract improved sperm quality and antioxidant status in the testis of rat exposed to rotenone. *Nephrourol Mon* 2017; 9(3): 1-7.
12. Mahmoudi A, Ghorbel H, Bouallegui Z, Marrekchi R, Isoda I, Sayadi S. Oleuropein and hydroxytyrosol protect from bisphenol A effects in livers and kidneys of lactating mother rats and their pups'. *Experimental and Toxicologic Pathology* 2015; 67(7-8): 413-425.
13. Kem OK, Dahae L, Nguyen TH, Ji HS, Hae-Jeung L, Dongho L Ki SK. Protective Effect of Phenolic Compounds Isolated from Mugwort (*Artemisia argyi*) against Contrast-Induced Apoptosis in Kidney Epithelium Cell Line LLC-PK1. *Molecules* 2019; 24(12): 195.
14. Maalej A, Bouallegui Z, Hadrich F, Isoda H, Sayadi S. Assessment of *Olea europaea* L. fruit extracts: phytochemical characterization and anticancer pathway investigation. *Biomed Pharmacother*. 2018;90(7): 179-186.
15. Tamari Y, Nawata H, Inoue E, Yoshimura A, Protective roles of ascorbic acid in oxidative stress induced by depletion of superoxide dismutase in vertebrate cells. *Free Radical Research* 2013; 47(1):1-7.
16. Chambial S, Dwivedi S, Shukla KK, John P J, Sharma P. Vitamin C in disease prevention and cure: an overview. *Indian Journal of Clinical Biochemistry* 2013; 28(4):314-328.
17. Gillani SW, Sulaiman SAS, Abdul MIM, Baig MR. Combined effect of metformin with ascorbic acid versus acetyl salicylic acid on diabetes-related cardiovascular complication; a 12-month single blind multicentre randomized control trial. *Cardiovasc Diabetol* 2017; 16(1):103.
18. Ashor AW, Werner AD, Lara J, Willis ND, Mathers JC, Siervo M. Effects of vitamin C supplementation on glycaemic control: a systematic review and meta-analysis of randomised controlled trials. *European Journal of Clinical Nutrition* 2017; 71(12):1371-1380.
19. Hill, A, Wendt S, Benstoem C, Neubauer C, Meybohm P, Langlois P, Adhikari NK, Heyland DK, Stoppe C. Vitamin C to Improve Organ Dysfunction in Cardiac Surgery Patients—Review and Pragmatic Approach. *Nutrients* 2018; 10(8): 974.
20. Man AM, Elbers PWG, Straaten HMO. Making Sense of Early High-dose Intravenous Vitamin C in Ischemia/Reperfusion Injury. *Critical Care* 2018; 22(1):70.

21. Zafar M, Naqvi SH. Effects of STZ-induced diabetes on the relative weights of kidney, liver and pancreas in albino rats: A comparative study. *International Journal of Morphology* 2010; 28(1):135-142.
22. Mohamed TA, Abouel-Nour MF, Eldemerdash R, Ibrahim Elgalady DI. Therapeutic Effects of Bone Marrow Stem Cells in Diabetic Rats. *Journal of Computer Science and Systems Biology* 2016; 9(2):58-68.
23. Sibghatullah MA, Sangi MI, Sulaiman MF, Abd El-wahab EA, Soad SA. Antihyperglycemic effect of thymoquinone and oleuropein, on streptozotocin-induced diabetes mellitus in experimental animals. *Pharmacognosy Magazine* 2015; 11(2):251-257.
24. Naziroğlu M. Enhanced testicular antioxidant capacity in streptozotocin-induced diabetic rats. Protective role of vitamins C and E and selenium. *Biological Trace Element Research* 2003; 94(1): 61-71.
25. Etim OE, Bassey UE, Charles GE, Sambo EE, Akpan, EJ. Toxicological evaluation of some artemisinin combination therapies (ACTs) on kidney and liver of albino Wistar rats. *International Journal of Biochemistry Research* 2016; 9(3):1-5.
26. Murray RL. (1984) Creatinine In: Kaplan, L.A., Pesce, A.J. (Eds.) *Clinical chemistry; theory, analysis and correlation*. CV Mosby Co., St. Louis. 1247-1253.
27. Fawcett JK, Scott J. A rapid and precise method for the determination of urea. *Journal of Clinical Pathology* 1960; 13(2): 156-159.
28. Fossati P, Prencipe L, Berti G. Use of 3,5-dichloro-2-hydroxy- benzenesulfonic acid/4-aminophenazone chromogenic system in direct enzymic assay of uric acid in serum and urine. *Clinical Chemistry* 1980; 26(2):227-231.
29. Gornal AC, Bardawill CJ, David MM. Determination of serum proteins by means of the biuret reaction. *Journal of Biological Chemistry* 1949; 177(2): 751-766.
30. Doumas BT, Watson WA, Biggs HG. Albumin Standards and Measurement of serum albumin with bromocresol green. *Clinica Chimica Acta* 1971; 31(1):87-92.
31. Buckley JA, Whitmore CM, Matsuda RL. Changes in blood chemistry and blood cell morphology in Coho salmon, *Oncorhynchus kisutch* following exposure to sublethal levels of total residual chlorine in municipal wastewater. *Journal of fish Research Board Canada* 1976; 33(4):776-782.
32. Tappel AL, Zalkin H. Lipid peroxidation in isolated mitochondria. *Archives of Biochemistry and Biophysics* 1959; 80:326-332.
33. Richardson M, Mwepey H. Effect of GSH depletion on tissue deposition of methyl mercury in rats. *Toxicology and Applied Pharmacology* 1975; 31(3):505-519.
34. Marklund S, Marklund G. Involvement of the superoxide anion radical in the autooxidation of pyrogallol and a convenient assay for superoxide dismutase. *European Journal of Biochemistry* 1974; 47(3): 469-474.
35. Aebi H, Bergmeyer HU, Gawehn K, Williamson DH, Lund P. Catalase (2nd ed.). In "Method of Enzymatic Analysis", (Eds.). Academic Press. New York London 1974; 673-684.
36. Habig WH, Pabst MJ, Jakoby WB, Glutathione S-transferases. The first enzymatic step in mercapturic acid formation. *Journal of Biological Chemistry* 1974; 249(22):7130-7139.
37. Paglia DE, Valentine WN. Studies on the quantitative and qualitative characterization of erythrocyte glutathione peroxidase. *American Journal of Translational Research* 1967; 70(1):158-169.
38. Palipoch S, Punsawad C. Biochemical and histological study of rat liver and kidney injury induced by Cisplatin. *Journal of Toxicologic Pathology*. 2013; 26(3):293-299.
39. Wanner MD, Silvio E, Inzucchi MD, John M, Lachin SD, David Fitchett MD, Maximilian von Eynatten MD, Michaela Mattheus DI, Biomath O, Erik Johansen MD, Hans J, Woerle MD, Uli C, Broedl MD, Bernard Zinman MD. Empagliflozin and progression of kidney disease in type 2 diabetes. *New England Journal of Medicine* 2016; 375(18):323-334.
40. Majid A, Sarah A, Hattf Bazool Farhood S. Study of some biochemical parameters for patients with Type II Diabetes Mellitus in Thi-Qar Governorate, Iraq. *Journal of Pharmaceutical Sciences and Research* 2018;10 (11): 2938-2941.

41. Kumar G, Banu G, Ganesan Murugesu A, Rajasekara Pandian M. Effect of *Helicteres isora* bark extract on protein metabolism and marker enzymes in streptozotocin-induced diabetic rats. *Iranian Journal of Pharmaceutical Research* 2010; 6(2):147-149.
42. Laaboudi WA, Ghanam JA, Ghomari OU, Sounni FA, Merzouki, MO, Benlemlih MO. Hypoglycemic and hypolipidemic effects of phenolic olive tree extract in streptozotocin diabetic rats. *International Journal of Pharmaceutical Sciences and Research* 2016; 8(12): 287-291.
43. Eid FA, Shoman HH, Abu Elnaga NA, Abed El-Halim H. Effect of olive leaf extract on the kidney of pregnant diabetic rats and their fetuses. *International Journal of Advanced Research* 2014; 2(11):740-776.
44. Helal EG, El-Wahab SM, El Refaey HA, Mohammad AA. Antidiabetic and antihyperlipidemic effect of *Balanites aegyptiaca* seeds (aqueous extract) on diabetic rats. *Egyptian Journal of Hospital Medicine* 2013; 52(1); 725-739.
45. Biniiaz V, Tayebi A, Ebadi A, Sadeghi Shermeh M, Einollahi B. Effect of vitamin C supplementation on serum uric acid in patients undergoing hemodialysis: a randomized controlled trial. *Iranian Journal of Kidney* 2014; 8(5): 401-407.
46. Juraschek SP, Miller ER, Gelber AC. Effect of oral vitamin C supplementation on serum uric acid: A meta-analysis of randomized controlled trials. *Arthritis Care and Research* 2011; 63(9):1295-1306.
47. Donsbough AL, Powell S, Waguespack A, Bidner TD, Southern LL. Uric acid, urea, and ammonia concentrations in serum and uric acid concentration in excreta as indicators of amino acid utilization in diets for broilers. *Poultry Science* 2010; 89(2):287-294.
48. Majekodunmi SO, Oyagbemi AA, Odeku OA. (Ameliorative Effects of the Ethanolic Seed Extract of *Mucuna pruriens* in Alloxan-induced Biochemical Alteration in Male Wistar Rats. *Pharmacologia* 2014; 5 (5):177-183.
49. Malawadi BN, Adiga U. "Plasma proteins in type 2 diabetes mellitus," *Journal of Biotechnology & Biochemistry* 2016;2(5): 1-3.
50. Hasan HR, Abdulsattar A. Influence of diabetes disease on concentration of total protein, albumin and globulins in saliva and serum: A comparative study. *Iraqi National Journal of Chemistry* 2015; 15 (1):1-11.
51. Chandramohan G, Al-Numair KS, Pugalendi KV. Effect of 3-hydroxymethyl xylitol on hepatic and renal functional markers and protein levels in alloxan-diabetic rats. *African Journal of biochemical* 2009; 3(5): 198-204
52. Kabir A. Blood chemistry analyses of Japanese quail (*Coturnix coturnix Japonica*). *Scholarly Journal of Agricultural Science* 2013; 3(4):132-136.
53. Nita M, Grzybowski A. The role of the reactive oxygen species and oxidative stress in the pathomechanism of the age-related ocular diseases and other pathologies of the anterior and posterior eye segments in adults. *Oxidative Medicine and Cellular Longevity* 2016; (12):1-23
54. Ahmed O, Ali MT, Mohamed AG, Ahmed AE. Effects of enalapril and paricalcitol treatment on diabetic nephropathy and renal expressions of TNF- α , P53, Caspase-3 and Bcl-2 in STZ-induced diabetic rats. *Plos One* 2019; 14(9): 17.
55. Jia Q, Yang R, Liu XF, Ma SF, Wang L. Genistein attenuates renal fibrosis in streptozotocin-induced diabetic rats. *Molecular medicine reports* 2019; 19(1):423-431.
56. Lins PG, Pugine SM, Scatolini AM, De-Melo MP. In vitro antioxidant activity of olive leaf extract (*Olea europaea* L.) and its protective effect on oxidative damage in human erythrocytes. *Heliyon* 2018; 4 (9): 22.
57. Annunziata G, Maisto M, Schisano C, Barrea L, Ciampaglia R, Novellino E. Oleuropein as a novel anti-diabetic nutraceutical. *Nutrients* 2018; 3 (1): 54.
58. Borowska S, Brzoska MM, Tomczyk M, Complexation of bioelements and toxic metals by polyphenolic compounds -implications for health. *Current Drug Targets* 2018; 19: 1612.
59. Carr AC, Maggini S. Vitamin C and immune function. *Nutrients* 2017; 9(11):3.
60. Smirnoff N. Ascorbic acid metabolism and functions: A comparison of plants and mammals. *Free Radical Biology and Medicine* 2018; 122: 116-129.
61. Berger MM, Oudemans-van Straaten HM. Vitamin C supplementation in the critically ill patient. *Current Opinion in Clinical Nutrition and Metabolic Care* 2015; 18(2):193-201.

62. Mir SH, Baqui A, Bhagat R, Darzi M, Shah AW. Biochemical and histomorphological study of streptozotocin-induced diabetes mellitus in rabbits. *Pakistan Journal of Nutrition* 2008; 7(2):359-364.
63. Sricharoenvej S, Tongpob Y, Lanlua P, Piyawinijwong S, Roongruangchai J, Phoungpetchara I. Renal microvascular changes in streptozotocin-induced, longterm diabetic rat. *Journal of the Medical Association of Thailand*. 2007; 90(12):2677-2682.
64. Nekooeian A, Dehghani G, Mostafavi H, Khalili A. "The effect of hydroalcoholic extract of olive leaves on blood pressure in a model of two-kidney, one-clip goldblatt hypertension". *Iranian Cardiovascular Research Journal* 2011; 5(1):1-6.
65. Morgana A M, El-Ballalb SS, El-Bialyc, BE, El-Boraic NB. "Studies on the potential protective effect of cinnamon against bisphenol A- and octylphenol-induced oxidative stress in male albino rats". *Toxicology Reports* 2014; 1: 92-101.
66. Mehanna SM, Abdel Aal SF, Abdel Maksod AD, Taha KM. "Histological and immuno-histochemical study on the possible protective effect of olive leaves extract on mitochondrial changes of the proximal convoluted tubule in diabetic male albino rats". *The American Journal of The Medical Sciences* 2016; 6(3): 98-116.
67. Harding AH, Wareham NJ, Bingham SA, Khaw K, Luben R, Welch A, Forouhi NG. Plasma vitamin C level, fruit and vegetable consumption and the risk of new-onset type 2 diabetes mellitus: The European prospective investigation of Cancer - Norfolk prospective study. *Archives of internal medicine* 2008; 168: 1485-1486.