



## African Journal of Urology

Official journal of the Pan African Urological Surgeon's Association  
web page of the journal

[www.ees.elsevier.com/afju](http://www.ees.elsevier.com/afju)  
[www.sciencedirect.com](http://www.sciencedirect.com)



### Andrology

#### Case report

# An 80 year old hermaphroditic with Hugh Brenner Tumour: a Rare Case Report and Review

G.N. Ayane<sup>a,\*</sup>, M.J. Motsumi<sup>a</sup>, P. Motlaleselelo<sup>b</sup>, K. Kadimo<sup>c</sup>

<sup>a</sup> Department of Surgery, Faculty of Medicine, University of Botswana, Botswana

<sup>b</sup> Surgical Department, Princess Marina Hospital, Botswana

<sup>c</sup> Department of Library Services, University of Botswana, Botswana

Received 9 November 2017; received in revised form 6 March 2018; accepted 9 March 2018; Available online 11 April 2018

#### KEYWORDS

Hermaphroditism;  
Brenner tumour (BT);  
Müllerian duct;  
Phenotype;  
Genotype;  
Pathology;  
Clitoromegaly

#### Abstract

**Introduction:** Hermaphroditism is a general term used to describe a sexual development disorder usually diagnosed at an early stage in sexual development. However, this is a report of an 80 year old sexual ambiguity patient with right adnexal Brenner Tumour.

**Observation:** In 2017 an 80 year old phenotypically true hermaphroditic patient referred from a district hospital presented with a history of abdominal pain, abdominal mass and vomiting for three months. A genitourinary examination revealed a small penis without intra scrotal testes, vagina pouch and atrophic clitoris. After abdominal CT scan confirmation of pelvic mass, the patient was taken for exploratory laparotomy. A right adnexectomy was performed, and the histopathological analysis confirmed a benign Brenner tumour.

**Conclusion:** The morphological expression of a true hermaphroditism is an “ovotestis” which can be classified into three different categories and require a tissue biopsy for confirmation. The association of a Brenner tumour in a hermaphroditic patient makes this report a significant contribution to human sexual differentiation literature.

© 2018 Pan African Urological Surgeons Association. Production and hosting by Elsevier B.V. This is an open access article under the CC BY-NC-ND license (<http://creativecommons.org/licenses/by-nc-nd/4.0/>).

\* Corresponding author.

E-mail addresses: [Gezahen.ayane@mopipi.ub.bw](mailto:Gezahen.ayane@mopipi.ub.bw), [medpeter2003@yahoo.fr](mailto:medpeter2003@yahoo.fr) (G.N. Ayane), [Mpapho.motsumi@mopipi.ub.bw](mailto:Mpapho.motsumi@mopipi.ub.bw) (M.J. Motsumi), [pakomot123@yahoo.com](mailto:pakomot123@yahoo.com) (P. Motlaleselelo), [Khutsafalo.kadimo@mopipi.ub.bw](mailto:Khutsafalo.kadimo@mopipi.ub.bw) (K. Kadimo).

Peer review under responsibility of Pan African Urological Surgeons' Association

<https://doi.org/10.1016/j.afju.2018.03.002>

1110-5704/© 2018 Pan African Urological Surgeons Association. Production and hosting by Elsevier B.V. This is an open access article under the CC BY-NC-ND license (<http://creativecommons.org/licenses/by-nc-nd/4.0/>).

## Introduction

The incidence of male sexual development abnormalities can be estimated at 1 in 20,000 male live births, affecting approximately 85,000 children per year in the European community [1]. Testosterone, dihydrotestosterone, and the anti-Müllerian hormone (AMH) play a fundamental role in human sexual differentiation [1]. In human genitourinary embryology, testis-induce male differentiation by testosterone stimulation of the Wolfian duct and anti-Müllerian hormone (AMH) cause Müllerian duct regression, which is a different process in female sexual differentiation.

Hermaphroditism in individuals bearing a Y chromosome and/or testicular tissue is due to two main processes — sex determination and genital differentiation. Sex determination leads to testicular dysgenesis with or without chromosome abnormalities or to true hermaphroditism, while genital differentiation, on the other hand, is due to abnormal production or sensitivity to a single testicular hormone or defects of AMH synthesis or action [1].

Disorders of sex development (DSD) or hermaphroditism is a complex entity of heterogeneous ethology that affects different dimensions (genetic, gonadal, phenotypic, and behavioural) of sex development. Most often dysgenetic gonads are at risk of developing tumours, which are subdivided into the germ cells derived, namely mixed germ cell and sex cord element-derived tumours. The most common dysgenetic gonad tumours are gonadoblastoma and dysgerminoma. First described by Brenner in 1907 as an oophoroma folliculare [2], Brenner tumours (BTs) account for 1–2% of benign ovarian tumours and has a predilection to affect postmenopausal woman [3]. There is strong evidence shown by some authors of a Brenner tumour originating from a testis, paratesticular tissue and from mesonephric structures. However, a Brenner tumour is believed to arise from a transitional cell metaplasia of the germinal epithelium.

Morphologically, Brenner tumours are composed of nests of epithelial cells resembling urothelium, which are surrounded by dense fibromatous stroma [4]. In recent years, some researchers identified a “hot spot”, which is the junction between the epithelium of fimbria and mesothelial serosa of the tube with high risk for carcinogenesis.

Many classification systems have attempted to offer a comprehensive clinicopathological overview. However, most modern authors accepted the World Health Organization’s (WHO) classification of Brenner tumours into three categories: benign, borderline (proliferative) and malignant [4]. Borderline Brenner tumours, usually associated with a benign Brenner tumour, are characterised by papillary structures with a fibrovascular core covered by a transitional epithelium. In 30% of cases, a Brenner tumour is associated with mucinous tumour or a cystadenoma.

After an extensive literature review regarding the occurrences of a Brenner tumour in hermaphroditism, no articles were found describing this occurrence, and hence, this is the first report of such an occurrence.

## Case report

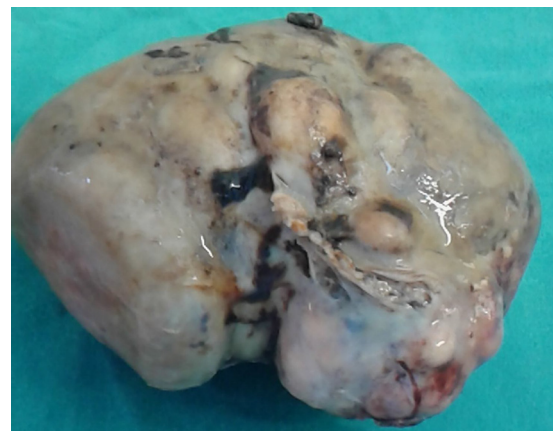
An 80-year-old phenotypically “true hermaphroditic” (sexual ambiguous) patient with a history of mild abdominal pain for three

months and intermittent vomiting, was referred to our tertiary hospital by a general practitioner. During medical history taking, the patient preferred to be addressed as male. The patient was never married or sexually involved and has no child. At the time of examination the patient’s vitals were normal, a palpable abdominal mass was found arising from the hypogastrium and extending into the mesogastric area. It measured about 12 cm × 13 cm in diameter, was mobile, painless, and not expansible, had an irregular surface and was firm in consistency. The digital rectal examination revealed an irregular mass felt through the anterior wall of the rectum, and it was very difficult to determine whether it was the prostate.

The patient had bilateral well-developed breast tissue. A genitourinary examination revealed a small penis without scrotum and no testes, a vaginal pouch with external meatus below the atrophic clitoris. Some blood investigation was done, including a full blood count, electrolyte, renal function test, liver function test, prostatic-specific antigen (PSA), and hormone profile (oestrogen, progesterone, testosterone, dihydrotestosterone, prolactin, and anti-Müllerian hormone). All basic blood investigation reports including PSA (0.09 ng/ml) were normal. The blood sample for the hormone profile was sent overseas and we never received the report. The findings of the abdominopelvic CT scans, pre- and post-contrast, showed two large central hyperdense abdominopelvic masses. It was a large mid-suprapubic homogeneous mass (7.35 × 12.91 × 13.47 cm), with scattered calcifications (density 387 HU), showing enhancement. A smaller pelvic prerectal retrovisical nodular mass with central hypodensities (7.58 × 7.66 × 7.95 cm) was also described.

The patient was prepared for diagnostic video-laparoscopy and biopsy, but after commencing the procedure we had to convert to an open laparotomy. Intra-operatively, a multilobulated solid right adnexal tumour was found. The uterus and both the Fallopian tubes were normal. The left adnexal looked atrophic. A right adnexectomy was performed with proper haemostasis.

The gross description is of an oval, encapsulated (kidney-shaped), partly nodular lump measuring 13 × 10 × 7 cm. Sections of the mass showed solid haemorrhagic mass with multifocal cystic cavities. There was a focal grey-white solid area peripherally. There was also focal calcification measuring 5 × 3 cm (×8) RP (see Fig. 1). The



**Figure 1** Showing a multilobulated solid right-ovarian tumour (Brenner tumour).

histopathological examination showed nests of polygonal epithelial cells with a pale cytoplasm and round to ovoid nuclei with some grooved nucleus. The tumour showed areas of haemorrhage and necrosis, but there was no cellular atypia and no mitosis. All the above features were indicative of a benign Brenner tumour of the ovary. The postoperative period was uneventful and the patient was discharged with medical advice and planned, regular follow-up.

## Discussion

Hermaphroditism is a more general term used to describe the discrepancy between the phenotype and the genotype of sex development than the term, sexual ambiguity, which refers mainly to anomalies of the external genitalia. From a pathogenetical perspective it is divided into:

- (a) Sexual differentiation defects due to a hormonal abnormalities, such as androgen insensitivity, steroid 5 alpha-reductase 2 deficiency, defect of testosterone synthesis, and persistent Müllerian duct syndrome;
- (b) Sexual determination abnormalities leading to a Turner-like syndrome, XX male, pure gonadal dysgenesis, and true hermaphroditism; and
- (c) Tumours of dysgenetic gonads, which include gonadoblastoma, dysgerminoma, and sex cord tumours (Sertoli cell adenoma and Leydig cell hyperplasia) [1].

Ovotestis is the classical morphologic expression of true hermaphroditism [5]. True hermaphrodite can be categorised into: lateral, in which one gonad (usually the left) is an ovary and the contralateral gonad is a testis; bilateral, in which both gonads are ovotestis; and unilateral, in which one gonad (usually the right) is an ovotestis, and the contralateral gonad is normal (ovary or testis). More than 50% of all cases fall into the last category [5]. Our case could fall into either “unilateral or lateral categories” depending on the contra-lateral adnexal histology confirmation because there was “A right ovarian Brenner tumour” (confirmed histologically), and an atrophic adnexal which was not discerned macroscopically.

Brenner tumours are composed of urothelial/transitional-type epithelium and are morphologically similar to a Walthard nest and tubal/mesothelial metaplasia. Recently, research has confirmed other sites of Brenner tumours origin such as Walthard nests, Fallopian tubes, testes, and paratesticular tissue [2]. Some researchers have demonstrated mesonephric structures as origin because the epithelium of the Brenner tumours has a great similarity to the transitional epithelium of the urinary tract as well as to testes and paratesticular tissue [2].

A Brenner tumour of the ovary or “ovotestis” is a solid tumour that is generally asymptomatic. Among symptomatic patients, common symptoms include abdominal pain, unspecific gastrointestinal symptoms, vaginal bleeding and a palpable pelvic mass [3]. Most of the time it is found to be unilateral. Bilateral tumours are seen in only 5–7% [3] of patients.

Lack of cellular atypia, mitosis and stromal invasion are the criteria that differentiate the benign entity from the malignant [6]. Immunohistochemistry and molecular analysis is helpful in diagnosis and

confirmation of Brenner tumours; but considering its high cost and that it does not add much clinical value, it is not routinely done [4]. It is difficult to diagnose Brenner tumours with imaging studies — both USG and computed tomography techniques are limited in specificity because of the tumour’s nonspecific appearance and similarity to those of other solid ovarian masses such as fibroma, fibrothecoma, and pedunculated leiomyoma [3].

Surgery is the primary therapeutic modality for Brenner tumours. The chemotherapy protocol specifically for malignant Brenner tumours have not been established yet and the efficacy of post-operative adjuvant chemotherapy and/or radiotherapy still remains unclear [3]. In this particular case the right ovarian mass showed microscopic features of a benign Brenner tumour associated with the hermaphroditism. A right adnexectomy was done and the post-operative period was uneventful, with the patient fully discharged after one follow-up.

## Authors’ contributions

i. G. N. Ayane

Attended the patient and wrote the case report.

ii. M. J. Motsumi

Attended the patient and reviewed the case report.

iii. P. Motlaleselelo

Attended the patient and reviewed the case report.

iv. K. Kadimo

Reviewed relevant articles, reviewed the case report and responded to comments.

## Consent from the patient

Written consent from the patient was obtained.

## Conflict of interest

The authors declare that they have no conflict of interest.

## Source of funding

Not applicable.

## References

- [1] Teinturier Â, Morel Y, Nicolino M, Mowszowicz Â, Fellous M, Chaussain J-L, et al. Aetiological diagnosis of male sex ambiguity: a collaborative study. *Eur J Pediatr* 2002;161:49–59, <http://dx.doi.org/10.1007/s00431-001-0854-z>.
- [2] Kuhn E, Ayhan A, Shih IM, Seidman JD, Kurman RJ. Ovarian Brenner tumour: a morphologic and immunohistochemical analysis suggesting an origin from fallopian tube epithelium. *Eur J Cancer* 2013;49:3839–49, <http://dx.doi.org/10.1016/j.ejca.2013.08.011>.

- [3] Borah T, Mahanta RK, Bora BD, Saikia S. Brenner tumor of ovary: an incidental finding. *J Midlife Health* 2011;2:40–1, <http://dx.doi.org/10.4103/0976-7800.83273>.
- [4] Katke RD, Acharya S. Huge Brenner' s tumour of ovary (6.2 kg) in a postmenopausal female — a rare case report and review of literature. *JGWH* 2017;2:1–3, <http://dx.doi.org/10.19080/JGWH.2017.02.555583>.
- [5] Schwartz SI, Cohen JC, Deligdisch L. Dysgerminoma of the ovary associated with true hermaphroditism. *Obstet Gynecol* 1980;56:102–6.
- [6] Baratz M, Gitstein SZ, David MP, Avni a. Proliferating Brenner tumour. *Postgrad Med J* 1979;55:826–9, <http://dx.doi.org/10.1136/pgmj.55.649.826>.