

Endometrial Osseous Metaplasia: Case Report with Literature Review

Patil SB, Narchal S, Paricharak DG, More SS

Department of Pathology, D.Y. Patil Medical College, Kasaba Bavda, Kolhapur, Maharashtra, India

Address for correspondence:

Dr. Sunita B Patil,
Department of Pathology,
D. Y. Patil Medical College, Kasaba
Bavda, Kolhapur - 416 006,
Maharashtra, India.
E-mail: drsunitapatil@gmail.com

Abstract

Endometrial osseous metaplasia is a rare pathological condition with mature bone in the endometrium and can be a cause for menorrhagia and infertility as bone in the endometrium acts like intrauterine contraceptive device. We report one such case with brief review of literature in a 28-year-old woman presenting with history of menorrhagia.

Keywords: Chronic inflammation, Endometrial stromal metaplasia, Heterotopia

Introduction

Endometrial osseous metaplasia is a rare entity^[1] and Nearly 80 cases have been reported in the world literature including, nine from India^[2] and it is the presence of mature or immature bone in the endometrium.^[1] Osseous metaplasia of the endometrium has also been incorrectly named as endometrial ossification, ectopic intrauterine bone, and heterotopic intrauterine bone formation.^[1,3] It varies from reactive, degenerative lesions to those able to associate with malignancy or those having a pre-neoplastic potential^[4] and it can be a rare cause of secondary infertility.^[5]

Case Report

A 28-year-old woman presented with history of menorrhagia. She was married for 4 years and she gave a history of one full-term vaginal delivery and a miscarriage subsequent to which she underwent dilatation and curettage at 13 weeks gestation 6 months ago. Menstrual history was normal before the event. Her general examination and bimanual exploration were normal. Her routine haematological parameters were normal and no abnormality was detected.

Histopathological evaluation of endometrial curettage material was carried out. On gross examination, multiple irregular, tiny,

hemorrhagic tissue bits altogether weighing 25 g. Microscopic examination of H and E, stained sections showed mature bony trabeculae with non-hematopoietic bone marrow [Figure 1], [Figure 2]. The surrounding endometrial tissue revealed tubular endometrial glands with scanty stroma and the mild stroma infiltration by chronic inflammatory cells. There is no evidence of granulomas and the metaplastic nature of this condition is proved morphologically by its continuity with stromal cells.

The patient had no signs or laboratory findings suggesting a calcium metabolism disorder.

A histopathological diagnosis of endometrial osseous metaplasia was given.

Discussion

Endometrial stromal metaplasias includes, formation within endometrial stroma, islands of smooth muscle, cartilage, and bone.^[6] The newer World Health Organization (WHO) classification divides them into those with epithelial and non-epithelial changes.^[7]

WHO classification of endometrial metaplasias and related changes:^[7]

1. Epithelial metaplasias and related changes
2. Non-epithelial metaplastic and related changes.
 - Smooth muscle metaplasia
 - Osseous metaplasia
 - Cartilaginous metaplasia
 - Fatty change
 - Glial tissue
 - Foam cell change.

Clinically, the symptoms range from a casual finding in an otherwise asymptomatic woman to menstrual irregularities.^[1,2]

Access this article online

Quick Response Code:	Website: www.amhsr.org
	DOI: *****

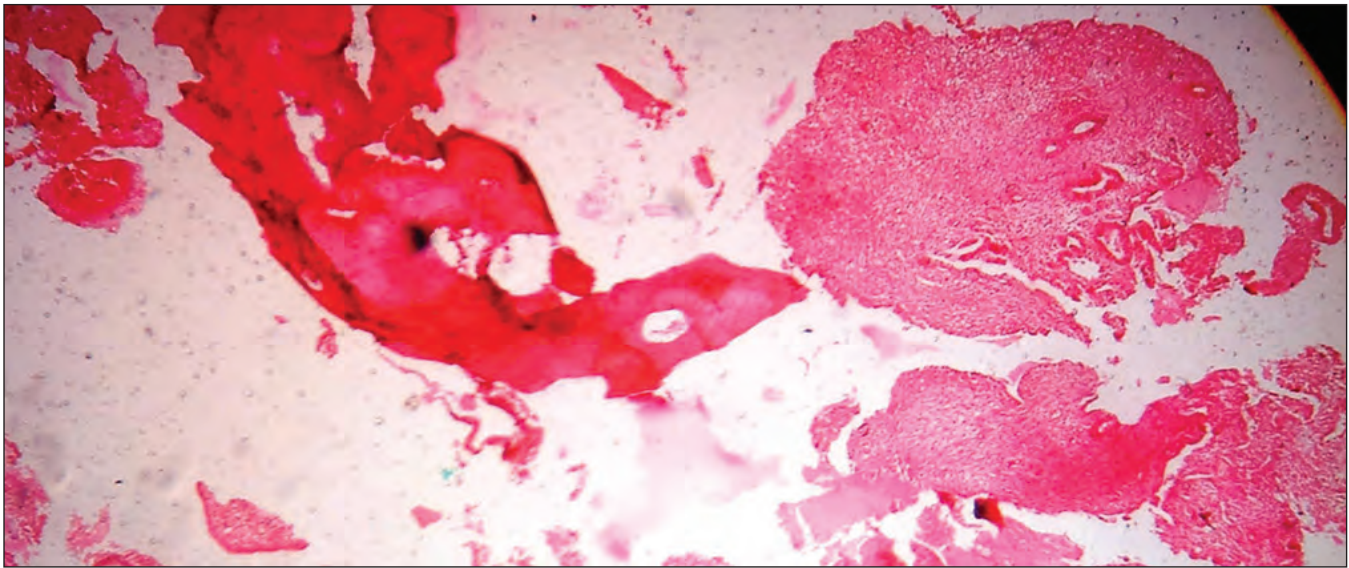


Figure 1: Photomicrograph showing bone trabeculae and endometrial tissue (H and E, ×5)

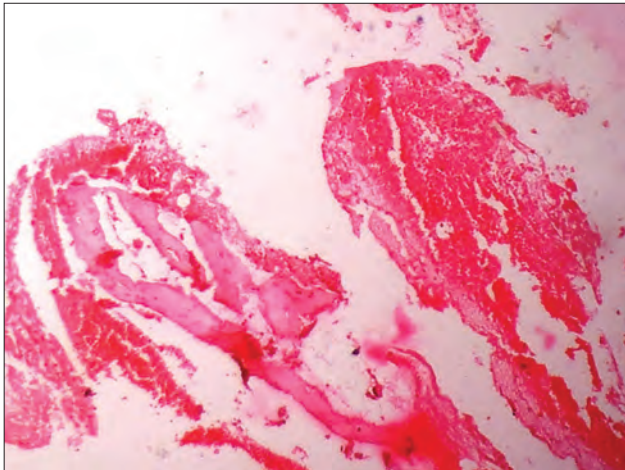


Figure 2: Photomicrograph showing bone trabeculae in hemorrhagic endometrial stromal tissue (H and E, ×10)

It is an endogenous non-neoplastic pathological condition as no tissue reaction is found in the endometrial tissue and the endometrium shows normal regular cyclical changes^[1] as noticed in our case. It characteristically appears in women in their reproductive years, although, it has been reported in the menopausal years as well. A history of previous pregnancy is reported in > 80% of the cases.^[2] Hormonal or exogenous stimuli (intrauterine contraceptive device) are the main inducing, factors of endometrial stromal metaplasias; although, some metaplasias have a mutational origin.^[4]

There are several theories that explain the presence of this tissue: metaplastic transformation of the endometrial stromal cell into osteoblastic cells that produce mature bone and implantation of fetal tissue after abortion and instrumentation with fetal tissue persisting and growing as a homograft.^[1,3] The

time interval between antecedent abortion and the detection of endometrial ossification varies from 8 weeks to 15 years in the reproductive age group.^[3]

The scientific literature proposes several different explanations based in a very frequent (although, not always co-existent) with a previous abortion. From this fact, many hypotheses are constructed, that can be summarized in two big groups:^[2]

1. Persistence of embryonic bones that keep developing after curettage or the appearance of bone tissue that is a result of persistent inflammation derived from remaining no bony necrotized embryonic tissue.
 - This hypothesis can be attributed to our case.
2. Induction of a process of osteogenesis by ones own embryonal cells, provoking the osseous differentiation of hypothetic pluripotential endometrial cells.

Genital tuberculosis, unspecific chronic endometritis, or pyometra are other sources of chronic inflammation occurring from retained embryonic tissue after first trimester abortion. This inflammation acts as a promoter of secondary osteogenesis from non-osseous embryonic tissue.^[3] In India, endometrial tuberculosis should be ruled out as it can cause infertility as well as calcification and subsequent ossification.^[1]

Chronic endometritis also stimulates the proliferation of mesenchymal cells that have inherent property of metaplasia and can differentiate into chondroblasts or osteoblasts.^[1]

Heterotopia, dystrophic calcifications, ossification of post-abortion endometritis, metastatic calcification, metaplasia in healing tissue, and prolonged estrogenic therapy after abortion and retained fetal bone are the common proposed theories.^[1]

It is also probable that the concept of a superoxide radical-superoxide dismutase system, which plays an important role in endometrial differentiation may be functional in osseous metaplasia.^[8] Bahçeci and Demirel suggested that post-abortive chronic endometritis stimulates the release of superoxide radicals and tumor necrosis factor from the inflammatory cells. Long-term exposure of superoxide radicals and tumor necrosis factor on multi-potent stromal cells in-patients with deficient superoxide dismutase activity in the endometrium leads to metaplasia of the stromal cells into osteoblastic cells.^[1]

Adamson linked endometrial ossification to hypervitaminosis in one of his two patients reported to have ossification after therapeutic abortions.^[8]

Roth and Taylor (1966) demonstrated the presence of acid mucopolysaccharides, thereby supporting the capability of mature endometrial stromal cells to undergo cartilaginous metaplasia in response to chronic inflammation or trauma. The cartilage in the biopsy specimens of these patients is a part of the osteoblastic process.^[8]

Conclusion

Endometrial stromal (osseous) metaplasias are conditions frequently overlooked and misdiagnosed and it is important to recognize the non-neoplastic nature of this condition to avoid misinterpretation as malignant mixed mullerian tumor of the uterus. Osseous metaplasia can be deeply embedded in the uterine mucosa and may present the same contraceptive effect as an intrauterine contraceptive device thereby causing secondary infertility.

References

1. Umashankar T, Patted S, Handigund R. Endometrial osseous metaplasia: Clinicopathological study of a case and literature review. *J Hum Reprod Sci* 2010;3:102-4.
2. Singh P, Kapur K, Singla S, Naz N. Endometrial osseous metaplasia and mature bone formation with extramedullary hematopoiesis. *J Hum Reprod Sci* 2011;4:56-7.
3. Cayuela E, Perez-Medina T, Vilanova J, Alejo M, Canadas P. True osseous metaplasia of the endometrium: the bone is not from a fetus. *Fertil Steril* 2009;91:1293.1.e1-4.
4. Nicolae A, Preda O, Nogales FF. Endometrial metaplasias and reactive changes: A spectrum of altered differentiation. *J Clin Pathol* 2011;64:97-106.
5. Kramer HM, Rhemrev JP. Secondary infertility caused by the retention of fetal bones after an abortion: A case report. *J Med Case Rep* 2008;2:208.
6. Rosai J. Uterus-corporis. In: Rosai J, editor *Rosai and Ackerman's surgical pathology*. Vol. 2. 9th ed. India: Elsevier; 2009. p. 1577.
7. Silverberg SG, Tabbara SO. The uterine corpus. In: Silverberg SG, editor. *Principles and practices of surgical pathology and cytopathology*. 3rd ed. USA: Churchill livingstone; p. 2470-72.
8. Bahçeci M, Demirel LC. Osseous metaplasia of the endometrium: A rare cause of infertility and its hysteroscopic management. *Hum Reprod* 1996;11:2537-9.

How to cite this article: ????

Source of Support: Nil. **Conflict of Interest:** None declared.