

# Perineal trauma in children: a standardized management approach

Amel A. Hashish

**Background/purpose** The management of perineal trauma in children is very challenging in the absence of a well-defined institutional management protocol. The purpose of this study was to evaluate the result of implementing a standardized therapeutic approach to perineal trauma in children in our institution.

**Patients and methods** This is a prospective study on the management of perineal trauma in children, according to a predefined protocol. Thirty-four patients with perineal trauma were treated at the Tanta University Hospital and affiliated hospitals during the period May 2003–July 2010. Two patients died of associated head trauma and other concomitant injuries. After initial assessment, resuscitation, and treatment of any existing life threatening condition, the patients were treated either by primary repair of all perineal soft tissue injuries without colostomy (group 1,  $n=16$ ), primary perineal repair with covering colostomy (group 2,  $n=11$ ), or fecal diversion and wound drainage with delayed sphincter repair if needed (group 3,  $n=5$ ). Each patient was assigned to a particular management depending on the presence or absence of full-thickness anorectal injuries, anorectal lacerations, degree of wound contamination, and/or significant skin loss. All patients were evaluated with regard to the type of trauma, physical findings, management, postoperative wound infection or disruption, postoperative functional outcome, and cosmetic results.

**Results** The ages ranged from 2 to 14 years. Significant wound infection occurred in three patients (one in each

group), moderate-to-mild wound infection occurred in another four patients, partial wound disruption occurred in two patients in group 1. Urethral stricture occurred in two patients, who were treated by repeated dilatation. Vaginal stenosis developed in one patient. Anorectal continence was noted in 25 (80.6%) of 31 patients who were older than 3 years during the last follow-up visit.

**Conclusion** (i) The proposed simple algorithm for the management of perineal trauma in children has facilitated decision making in the emergency room. (ii) Primary repair of the anorectal sphincter and other injured soft tissue with or without covering colostomy is recommended. (iii) Fecal diversion without sphincter repair should be reserved to cases with significant anorectal lacerations associated with gross contamination. *Ann Pediatr Surg* 7:55–60 © 2011 Annals of Pediatric Surgery

*Annals of Pediatric Surgery* 2011, 7:55–60

**Keywords:** children, colostomy, perineal trauma, primary repair

Department of Pediatric Surgery, Tanta University, Tanta, Egypt

Correspondence to Amel A. Hashish, MD, Associate Professor of Pediatric Surgery, Department of Pediatric Surgery, Tanta University Hospital, Tanta, 31111, Egypt  
Tel: +20 12 331 5309; fax: +20 40 340 7734; e-mail: amelhashish@gmail.com

Received 12 January 2011 Accepted 20 February 2011

## Introduction

Perineal trauma in children is uncommon. It may cause a wide spectrum of injuries ranging from minor perineal skin laceration or erosion to severe injury to the genitourinary tract, anal sphincters, or pelvic compartment. The perineal injuries are usually attributed to blunt trauma, impalement injury, or sexual abuse.

Blunt trauma to the perineum accounts for approximately 8–10% of perineal trauma [1,2] and may cause severe injury due to compression of the soft tissue against the bony pelvis [3]. Impalement injuries are relatively uncommon. It is usually caused by accidental falls on an offending object [4,5] or due to sexual assault, which is infrequent in our community. Sometimes, it is difficult to evaluate the magnitude of the perineal injury in children in cases of blunt trauma or impalement injuries, which does not reflect the severity of injury of the internal structures [6,7].

There are many controversies regarding the proper management of perineal trauma in children. In many cases, especially in emergency department, it is difficult

to decide whether to perform primary or delayed sphincter repair or whether coverage colostomy is needed or not.

The aim of this study was to evaluate the outcome of management of patients with perineal trauma according to a predefined protocol at our institution.

## Patients and methods

Thirty-four patients with perineal trauma were treated at the Tanta University Hospital and affiliated hospitals during the period May 2003–July 2010. Two patients died shortly after admission due to associated head trauma, pelvic fractures, and other concomitant injuries (Fig. 1).

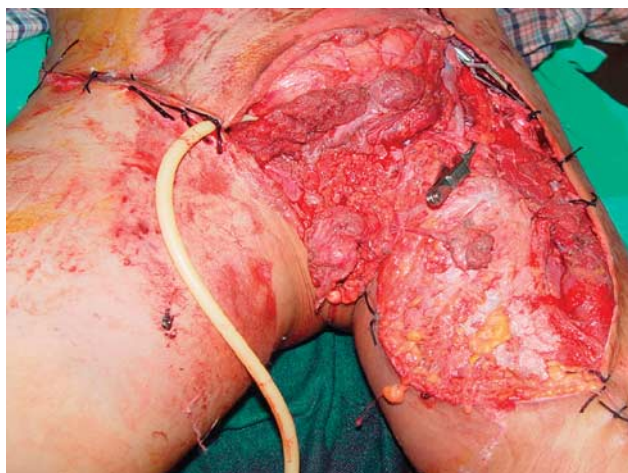Hemodynamic stabilization and treatment of existing life-threatening conditions were started immediately. Meticulous wound care, irrigation, and debridement of wound and antibiotic therapy was started. Perineal examination was conducted under general anesthesia in most cases to exclude rectal perforation and to achieve proper evaluation of the anorectal sphincter, vagina, and or urethra.

All patients were treated according to a well-defined protocol (Fig. 2). Treatment strategy was based mainly on the general condition of the patient, severity and extension of anorectal lacerations, degree of wound contamination, and degree of skin loss. The patients

were classified into three groups. Group 1 included 16 patients, who had primary repair of perineal soft tissue injuries without colostomy. Group 2 included 11 patients, who had primary repair of soft tissue injuries with covering colostomy. Group 3 included five patients, who had fecal diversion and wound drainage due to presence of severe anorectal lacerations associated with massive contamination and significant skin loss. Other surgical disciplines were called if indicated.

All results, with regard to the type of trauma, findings of physical examination, type of management, postoperative wound infection or disruption, and functional (anorectal continence) and cosmetic results, were tabulated and analyzed.

Fig. 1



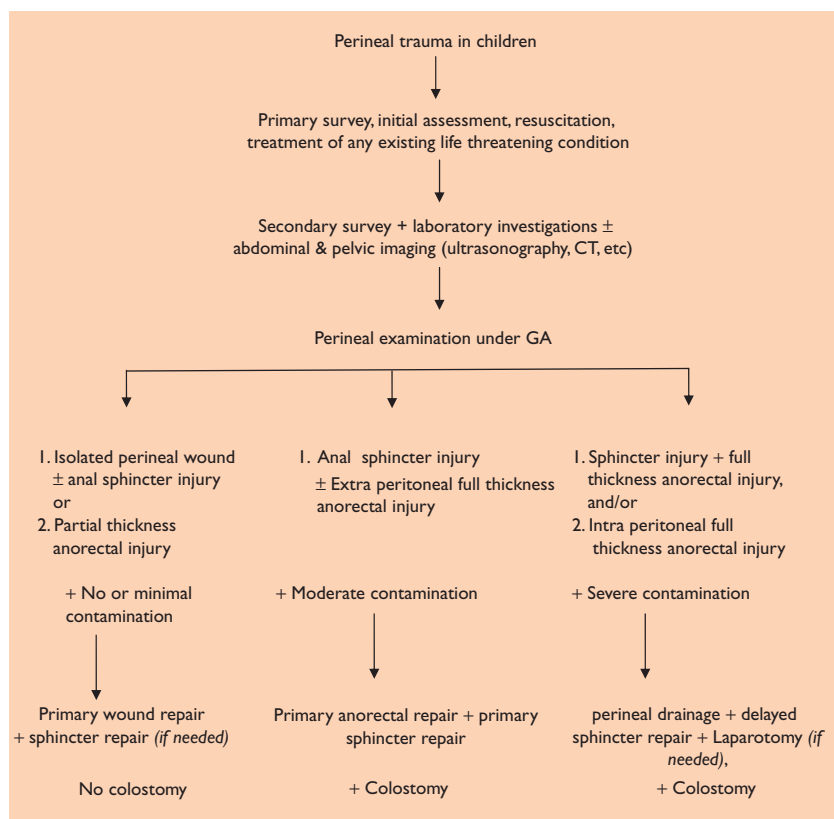
Severe perineal trauma, pelvic fracture, urethral, bladder, external genital, and anorectal injury. The patient died shortly after arrival to the emergency room due to associated severe head trauma.

### Results

This study included 11 girls and 21 boys; the two children with polytrauma, who died shortly after arrival were not included in this study. The ages ranged from 2 to 14 years (median: 8 years). The mechanism of trauma was motor vehicular accident injury ( $n = 16$ ), sport injuries ( $n = 5$ ), fall from height ( $n = 4$ ), impalement injury ( $n = 6$ ), and accidental gunshot ( $n = 1$ ).

The extent of injuries and management of the three groups are shown in Table 1.

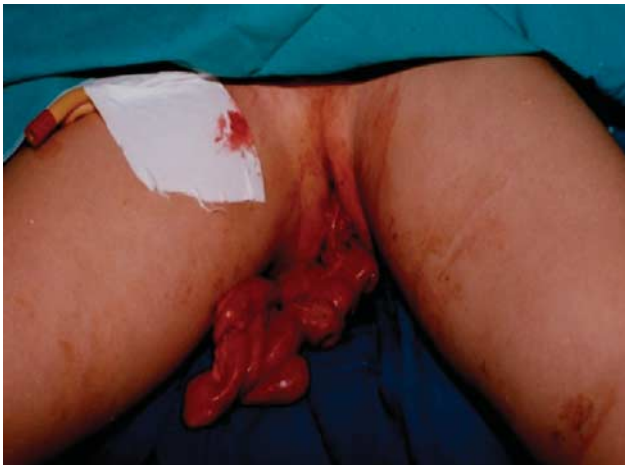Fig. 2



Protocol for management of perineal trauma in children.

**Table 1** Extent of injury and management protocol

Group	Lesion and number (n)	Management protocol
Group 1 (n=16)	Perineal wound (n=8)	Primary repair of the sphincter and/or all soft tissue injuries without colostomy
	Perineal wound and sphincter injury (n=5)	
	Extraperitoneal partial thickness anorectal injury, sphincter injury, minimal contamination (n=3)	
Group 2 (n=11)	Combined full thickness anorectal and sphincter injury (n=7)	Primary repair of the sphincter, vagina, urethra, and soft tissue injuries with colostomy
	Combined anorectal and vaginal injury (n=3)	
	Combined anorectal and urethral injury (n=1)	
Group 3 (n=5)	Combined anorectal and sphincter injury (n=2)	Fecal diversion, urinary diversion, wound drainage without repair
	Combined anorectal and urethral injury (n=2)	
	Combined anorectal and vaginal injury (n=1)	

**Fig. 3**

Perineal evisceration of the small bowel after blunt abdominal and perineal trauma.

A nine-year-old female patient presented with evisceration of the small bowel through the perineum after blunt abdominal and perineal trauma caused by a car accident (Fig. 3). Both the colon and rectum were intact. Laparotomy, reduction of the eviscerated bowel, and perineal repair without colostomy were performed.

Sigmoid colostomy was performed in 16 patients (groups 2 and 3). Abdominal exploration was needed in four of these 16 patients due to the presence of intraperitoneal hemorrhage and/or contamination. One patient in group 2 had intraperitoneal injury to the rectum, tear in the mesentery and tear in the small intestine, repair of the rectal tear and resection of a segment of small bowel and anastomosis in addition to colostomy was done. The other three patients underwent repair of intraperitoneal tear of the rectum and colostomy.

Perineal wounds in either group 1 or 2 were repaired using absorbable sutures after thorough wound cleaning with warm saline and meticulous debridement, under the umbrella of broad-spectrum antibiotics.

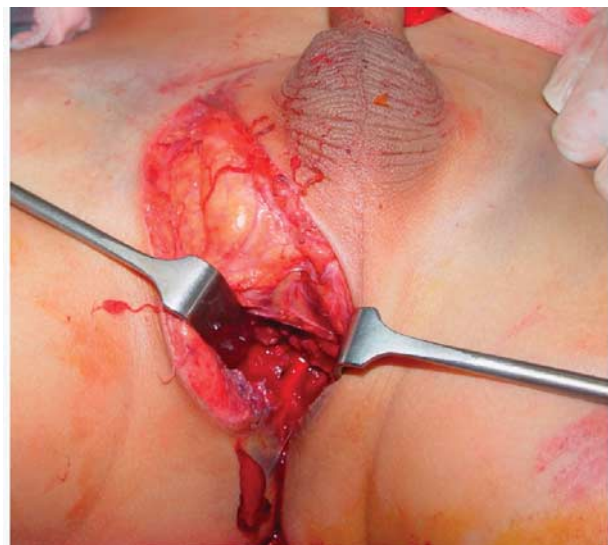
Primary repair of the rectal injuries and anorectal sphincter with or without coverage colostomy was performed in 19 patients (eight patients in group 1 and 11 patients in group 2). Repair of the anorectal injuries and/or anorectal sphincters using 3/0 or 4/0 Vicryl sutures (Ethicon, Johnson & Johnson, Somerville, New Jersey, USA) after meticulous cleaning of any existing contamination and debridement of nonhealthy tissue was performed (Figs 4 and 5). Primary repair of the associated vaginal injuries in three patients in group 2 was performed at the same time.

Two patients, one in group 1 and the other in group 2, continued to suffer from anorectal incontinence after primary repair of the injured anorectal sphincters. Redo sphincter repair was attempted successfully 6 and 8 months later (Figs 6 and 7).

Fecal diversion, urinary diversion, and wound drainage without repair were performed in five patients in group 3 with severely contaminated trauma with injury to the rectum and/or to the vagina or urethra. Four patients in this group underwent delayed sphincteroplasty 3–8 months later. Fecal continence was achieved in two of them. The last patient underwent multiple skin grafting sessions, and no repair of the significantly damaged anorectal sphincter was attempted (Fig. 8).

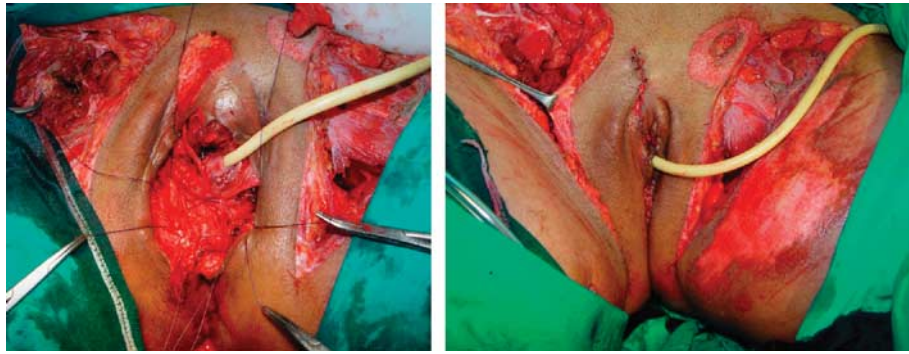
All patients received postoperative antibiotics (metronidazol and third-generation cephalosporin). Insufficiency of the anal sphincters was verified by inquiry about continence, rectal digital examination, and/or endoanal ultrasound, 3-weeks after surgery. Closure of colostomy was performed 3–10 months after initial operation (average 5 months).

Significant wound infection occurred in seven patients (21.9%). The infection was severe and necessitated wound drainage in three patients. Moderate-to-mild infection that responded to conservative treatment was noticed in another four patients, and wound disruption in three patients (9.4%). Anorectal incontinence was noted

**Fig. 4**

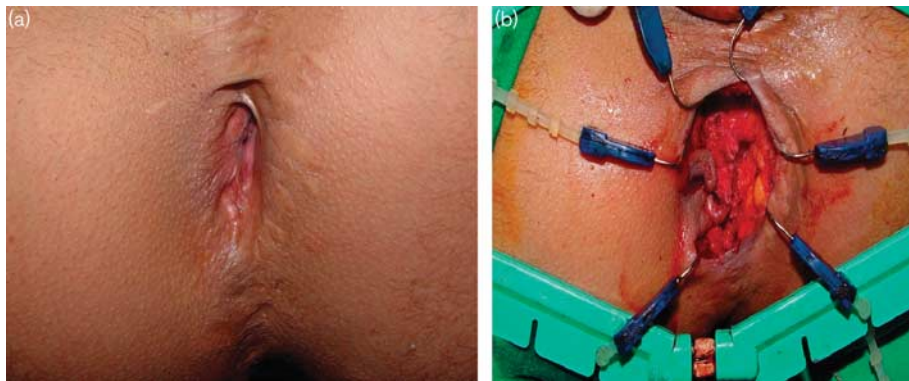
Perineal trauma and partial-thickness anorectal injury treated by primary repair of the sphincter, wound closure, without colostomy.

Fig. 5



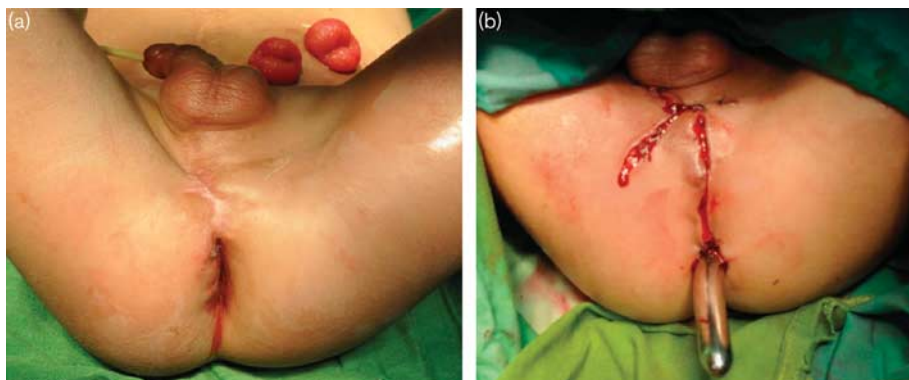
Perineal trauma, sphincteric injury, vaginal injury, pelvic fracture, partial-thickness anorectal injury treated by primary repair of the sphincter, vagina, perineum wound closure, without colostomy.

Fig. 6



(a) Perineal scarring and anorectal incontinence after perineal trauma treated initially by perineal repair, sphincteroplasty without colostomy. (b) Redo repair of the anorectal sphincter.

Fig. 7



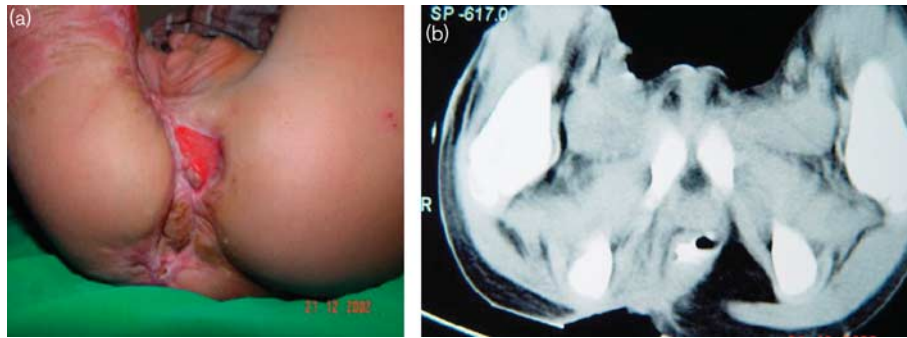
(a) Perineal scarring and anorectal incontinence after perineal trauma treated initially by perineal repair, fecal diversion, and urinary diversion. (b) Redo repair of the anorectal sphincter.

in five of 31 (16%) patients, who were older than 3 years during the last follow-up visit. Urethral stricture occurred in two patients, who were treated by repeated dilation. Vaginal stenosis developed in one patient (Table 2).

### Discussion

Perineal trauma in children can be a life-threatening and surgically challenging condition in the absence of a standardized therapeutic approach. Little data with

Fig. 8



(a) Severe perineal scarring, chronic ulcer, and anorectal incontinence after perineal trauma treated initially by perineal repair, fecal diversion, and urinary diversion, wound drainage. (b) Computerized tomography showing significant damage of the anorectal sphincter.

Table 2 Postoperative complications

	Group 1 (n=16)	Group 2 (n=11)	Group 3 (n=5)
Wound infection	3	3	1
Wound disruption	1	2	1 <sup>a</sup>
Urethral stricture	0	1	1
Vaginal stricture	0	1	
Fecal incontinence	1	1	3

<sup>a</sup>Wound disruption occurred after delayed repair.

regard to perineal trauma in children were published in pediatric surgical literature and limited experience among junior pediatric surgeons who are usually involved in managing these cases in emergency rooms resulted in many controversies regarding the management strategy of these cases.

The cause of perineal trauma in children is quite variable in different countries. Direct perineal trauma due to road traffic accident, accidental fall from height, and implement injury blunt trauma were the main causes in this study. Sexual abuse is extremely rare in our locality, and it seems to be the case in most of the developing countries [8]. In contrast, sexual abuse and fire arm were reported in the majority of cases in the developed countries [2,7], whereas road traffic accident was reported in approximately 10% of cases only [2].

Perineal trauma tends to be more common in boys than girls as reported by many researchers [2,8]. This is attributed to aggressive play and more strenuous activities carried out by boys. A similar finding was noted in this series, in which boys were affected twice more than girls.

Evaluation of perineal trauma in children needs to be meticulous, especially in cases of impalement injuries. Lack of external findings in many of these cases does not preclude rectal perforation or vaginal or urinary bladder injury. The severity of anorectal wounds after implement injury is difficult to estimate. Thorough preoperative evaluation is of utmost importance to exclude any concomitant lesion.

Examination under general anesthesia is recommended to avoid underestimation of the severity of injury. Adoption

of this rule has enabled us to properly assign all injured patients to the proper management protocol. Preoperative proctoscopy, vaginoscopy, or cystoscopy is performed in suspected cases to rule out bowel perforation or other concomitant lesions as urethral or rectal bleeding. In addition, a large battery of investigations may be needed for proper evaluation of the patient including plain abdominal radiography to identify any fracture of the pelvic bones or free peritoneal air [8]. Leaphart *et al.* [2] recommended computed tomographic scan of the abdomen and pelvis for hemodynamically stable patients including the use of triple contrast (intravenous, oral, and rectal), and anorectal examination under anesthesia to minimize the possibilities of missing any overlooked injuries.

In this study, we performed proctoscopy in three patients. We found that it is important to perform proctoscopy in polytraumatized patients, especially in those who have a fractured pelvis. The possibility of urethral rupture could be up to 70% in cases of fractured pelvis [9]. However, urethral lesions are reported by others without pelvic fractures [3].

There is no standard management for perineal trauma in children. The current management options for children presented with perineal trauma is similar to that of adults that entails either wound drainage, fecal diversion, and delayed sphincter reconstruction or primary sphincter reconstruction after exclusion of anorectal injury or primary wound closure and delayed sphincter reconstruction even after exclusion of anorectal injury [7,8].

In this study, we proposed a management protocol to define the best option for each individual case of perineal trauma in children. The protocol helps the junior pediatric surgeons working in emergency rooms to decide the management plan. Black *et al.* [7] classified anorectal injuries into five grades. They recommended primary repair in cases of partial-thickness injury to the anal canal and/or rectal mucosa, and primary repair with colostomy in cases of full-thickness injury below the internal and external anal sphincters and in cases of full-thickness injury above the internal anal sphincter without peritoneal involvement. They also recommended laparotomy,

colostomy, and repair of the intraperitoneal rectum in cases of full-thickness injury above the internal anal sphincter with peritoneal involvement. The current protocol is more simplified than that of Black *et al.* [7].

In cases of anorectal injuries, therapy is similar to those in adults including fecal diversion and closure of the wound after debridement with or without presacral drainage [10,11]. Haut *et al.* [12] reported safe primary repair in 62% of their cases with penetrating colorectal injuries. They performed colostomy in 38% of cases of colorectal injury who have shock, required multiple blood transfusion, having multiple other injuries, extensive contamination, and history of injury by high-velocity weapon. Primary closure was performed in all patients in this study with perineal trauma without anorectal injury and nonsignificant soiling.

Thomas *et al.* [13] reported primary repair of small isolated injuries without colostomy. Other studies emphasized that repair is not appropriate for all patients; controversies exist about those criteria by many authorities [14,15]. On the basis of the outcome of patients enrolled in this study, we believe that colostomy should be performed in cases of severe contamination or in cases of combined penetrating urinary and rectal injuries.

All cases of either partial or complete rupture of the urethra require suprapubic cystostomy with primary repair or tenting of the urethra [11]. Many literatures support the use of transurethral catheter decompression in cases of bladder injury followed by cystogram and removal of the catheter after 10–14 days of bladder drainage [16,17].

Coverage colostomy has an important rule to minimize the frequency of perineal wound infection after perineal trauma. The presence of full-thickness anorectal injuries and/or wound contamination will dictate whether there is need for colostomy. Significant wound infection occurred in seven of our 32 patients in this study; three of them had perineal repair without colostomy. Wound infection after primary closure was reported in one of seven patients in Beiler *et al.*'s. [6] series.

Endoanal ultrasound and computerized tomography are import tools for proper anatomical evaluation of anorectal sphincter after perineal trauma especially before considering delayed repair of the anal sphincter [6]. Kim *et al.* [18] reported that anal incontinence could occur temporarily due to sphincter weakness and could be

treated by biofeedback training. Beiler *et al.* reported two patients with temporary sphincter insufficiency that was treated without surgery by biofeedback.

## Conclusion

The management of perineal injuries should be individualized according to the severity of injury. Management decisions should be based on precise anatomic characterization of the injury. In the absence of shock, associated injuries, or gross fecal soiling, primary sphincteroplasty could be considered. Colostomy remains an important decision in the presence of rectal injury and/or gross soiling. The proposed simple algorithm for management of perineal trauma in children proved to be safe and effective in our series.

## References

- Scheidler MG, Schultz BL, Schall L, Ford HR. Mechanisms of blunt perineal injury in female pediatric patients. *J Pediatr Surg* 2000; **35**:1317–1319.
- Leaphart CL, Danko M, Cassidy L, Gaines B, Hackam DJ. An analysis of proctoscopy vs. computed tomography scanning in the diagnosis of rectal injuries in children: which is better? *J Pediatr Surg* 2006; **41**:700–703. discussion 700–703.
- Reinberg O, Yazbeck S. Major perineal trauma in children. *J Pediatr Surg* 1989; **24**:982–984.
- Grisoni ER, Hahn E, Marsh E, Volsko T, Dudgeon D. Pediatric perineal impalement injuries. *J Pediatr Surg* 2000; **35**:702–704.
- Bronkhorst MW, Wilde JCH, Hamming JF, Heij HA. Anorectal impalement in a pediatric patient with transanal evisceration of small bowel. *J Pediatr Surg* 2007; **42**:e23–e25.
- Beiler HA, Zachariou Z, Daum R. Impalement and anorectal injuries in childhood: a retrospective study of 12 cases. *J Pediatr Surg* 1998; **33**:1287–1291.
- Black CT, Pokorny WJ, McGill CW, Harberg FJ. Anorectal trauma in children. *J Pediatr Surg* 1982; **17**:501–504.
- Ameh EA. Anorectal injuries in children. *Pediatr Surg Int* 2000; **16**:388–391.
- Lascombes P, Prevot J. Fractures of the pelvis and associated bladder-urethral rupture. *Chir Pediatr* 1988; **29**:114–119.
- Ivatury RR, Licata J, Gunduz Y, Rao P, Stahl WM. Management options in penetrating rectal injuries. *Am Surg* 1991; **57**:50–55.
- Renz BM, Feliciano DV, Sherman R. Same Admission Colostomy Closure (SACC). A new approach to rectal wounds: a prospective study. *Ann Surg* 1993; **218**:279–292. discussion 292–293.
- Haut ER, Nance ML, Keller MS, Groner JI, Ford HR, Kuhn A, *et al.* Management of penetrating colon and rectal injuries in the pediatric patient. *Dis Colon Rectum* 2004; **47**:1526–1532.
- Thomas DD, Levison MA, Dykstra BJ, Bender JS. Management of rectal injuries. Dogma versus practice. *Am Surg* 1990; **56**:507–510.
- Sasaki LS, Allaben RD, Golwala R, Mittal VK. Primary repair of colon injuries: a prospective randomized study. *J Trauma* 1995; **39**:895–901.
- Chappuis CW, Frey DJ, Dietzen CD, Panetta TP, Buechter KJ, Cohn JJ. Management of penetrating colon injuries. A prospective randomized trial. *Ann Surg* 1991; **213**:492–497. discussion 497–498.
- Corriere JN Jr, Sandler CM. Management of the ruptured bladder: seven years of experience with 111 cases. *J Trauma* 1986; **26**:830–833.
- Margolin DJ, Gonzalez RP. Retrospective analysis of traumatic bladder injury: does suprapubic catheterization alter outcome of healing? *Am Surg* 2004; **70**:1057–1060.
- Kim S, Linden B, Cendron M, Puder M. Pediatric anorectal impalement with bladder rupture: case report and review of the literature. *J Pediatr Surg* 2006; **41**:E1–E3.