

Neonatal adrenal hemorrhage presenting as acute scrotum

Hossam Elshafei^a, Jai Kumar Mahajan^b, Thanaa Elhanafy^a, Dalal K. Bubshait^a and Mohamed Al Ghamdi^a

Neonatal adrenal hemorrhage may rarely present as acute scrotum, mimicking the conditions that require an immediate operative intervention. The authors report one such case and discuss the importance of clinical examination and ultrasonography to avoid an unnecessary surgical exploration. *Ann Pediatr Surg* 9:155–156 © 2013 Annals of Pediatric Surgery.

Annals of Pediatric Surgery 2013, 9:155–156

Keywords: neonatal acute scrotum, neonatal adrenal hemorrhage, scrotal hematoma, testicular torsion

Introduction

In newborns, adrenal hemorrhage is not an uncommon event. The large size of the adrenal cortex contributes to an increased vulnerability to trauma during a difficult delivery [1]. However, the neonatal adrenal hemorrhage may rarely present as inguinoscrotal swelling [2,3]. This condition can simulate torsion of the testis or strangulated inguinal hernia requiring an immediate surgical exploration [3]. A careful evaluation of the clinical features in a neonate along with ultrasonographic (US) examination can help to avoid an unnecessary surgery. We report one such neonate who was successfully managed conservatively.

Case report

A 3.765 kg male baby, born to a multigravida mother, presented on the second day of life with a left inguinoscrotal swelling and bluish discoloration over it. The baby was delivered at full term through a difficult vaginal delivery after a prolonged second stage of labor and had an Apgar score of 9 and 10 at 1 and 5 min, respectively. The baby required only routine resuscitative efforts and was transferred to the nursery for observation. There was no history of vomiting, refusal to feed, excessive crying, abdominal distension, and the patient was passing urine and stool normally. On examination, the baby was comfortable, active, and crying well, with intact primitive reflexes. There was no jaundice and the baby was hemodynamically stable. However, a few small bluish patches of discoloration were seen over the back, scalp, and the left axillary region. There was a nontender, inguinoscrotal swelling with bluish discoloration over the left inguinal area. The right scrotum was also enlarged but the overlying skin was not edematous. Neither of the testes could be palpated separately. Hematological investigations including the coagulation profile were normal. US examination of the inguinoscrotal area was carried out to rule out the presence of testicular torsion and inguinal hernia, and it showed turbid fluid with internal echoes suggestive of hematoceles. There was no evidence of bowel loops in the swelling. Both the testes had normal echogenicity and texture. US of the abdomen showed a 37 × 41 mm

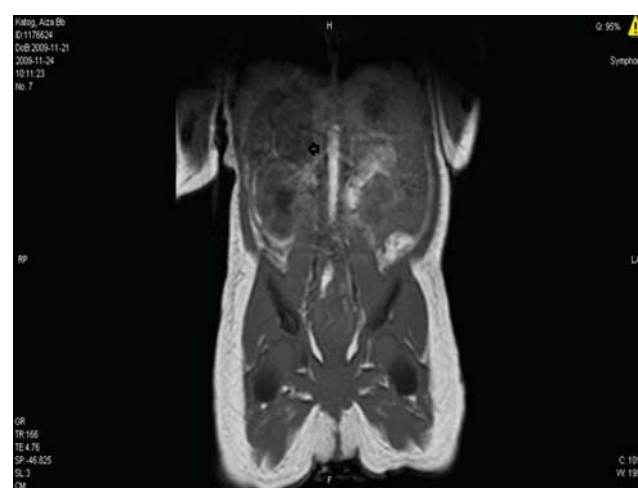
^aDivision of Pediatric Surgery, Departments of Surgery and Neonatology Unit, Departments Pediatrics, King Fahad Hospital, University of Dammam, Alkhobar, Kingdom of Saudi Arabia and ^bDepartment of Pediatric Surgery, Postgraduate Institute of Medical Education and Research, Chandigarh, India

Correspondence to Hossam Elshafei, MBBCh, MSc, MD Surg, Department of Surgery, Division of Pediatric Surgery, King Fahad Hospital, University of Dammam, PO Box 40178, Alkhobar 31952, Kingdom of Saudi Arabia
Tel: +966 55 1091028/ +20 100 6088853; fax: +966 13 8966745; e-mail: hossamshafei@yahoo.com

Received 10 May 2012 accepted 27 August 2013

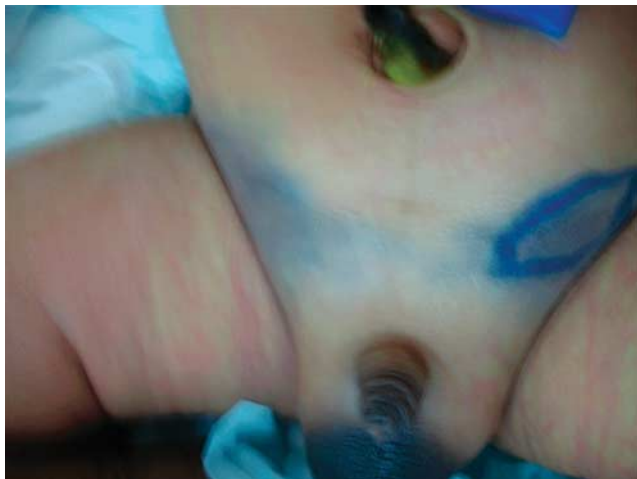right suprarenal hematoma. An MRI scan showed a right suprarenal heterogeneous mass with an intermediate to low signal intensity centrally and an enhanced intensity peripherally, indicative of hemorrhage (Fig. 1). Adrenocorticotropic hormone (9.43 pg/ml, range 0–46 pg/ml), cortisol [2.4 µg/dl; range (morning: 4.2–38.4 µg/dl, evening: 1.7–16.62 µg/dl)], and vanillylmandelic acid levels (0.3 mg/24 h) were normal. The bluish discoloration also appeared on the other side; however, the patient was stable and feeding well (Fig. 2). In view of the good general condition and the US findings, the baby was managed conservatively. The discoloration started to fade away by the fifth day and the scrotal size decreased. Repeat MRI scan showed a decrease in the size of hematoma and the baby was discharged on the 10th day. During the follow-up period, he was doing well at 3 months and the adrenal gland had healed without calcification.

Fig. 1



A T1-weighted MRI scan showing right adrenal hemorrhage.

Fig. 2



A clinical image showing discoloration of the inguinoscrotal area.

Discussion

Adrenal hemorrhage is the second most common cause of hemoperitoneum in the neonates and its incidence has been estimated to be 2/1000 births [1]. The causes of the adrenal hemorrhage can be traumatic delivery, asphyxia, maternal hypotension, large birth weight, and hemorrhagic disorders [1–3]. It is more common in males and the right adrenal gland is affected more often than the left, 10% of the cases being bilateral [4]. The presentation is variable and depends on the amount of blood loss. Adrenal hemorrhage can present as persistent anemia, jaundice, abdominal mass, hypotension, and shock besides the inguinoscrotal hematoma [1,5]. The hemorrhage is typically contained within the capsule of the adrenal gland and a breach in the capsule may lead to spread of the blood in the retroperitoneum or, less frequently, it may enter into the peritoneal cavity [6].

Acute scrotum in the neonates and infants can be because of a variety of reasons such as testicular torsion, epididymo-orchitis, acute hematoma, meconium peritonitis, scrotal edema, and testicular trauma [7,8]. Hematocele is an uncommon cause of neonatal acute scrotum and it is usually associated with an intra-abdominal

pathology [2]. Hematocele caused by the adrenal hemorrhage can be confused with any of the aforementioned conditions. Adorasio *et al.* [3] reviewed 22 cases of the scrotal hematoma caused by the neonatal adrenal hemorrhage and an unnecessary surgical exploration for the testicular torsion was performed in nine cases (41%). In our case, testicular torsion and irreducible inguinal hernia with strangulation were considered in the differential diagnosis during clinical examination but the baby was too well for these conditions and the US settled the issue. Scrotal hematocele as a clinical manifestation of neuroblastoma has also been reported once [7]. US is the first diagnostic step to exclude retroperitoneal origin of bleeding. An MRI will help to differentiate from the neonatal cystic neuroblastoma [7]. Adrenal hematoma will heal with or without calcification, whereas a tumor will persist on follow-up scans.

Acute scrotal swelling resulting from a remote intra-abdominal pathology, such as neonatal adrenal hemorrhage, is a rare entity. A high index of suspicion is required and knowledge of this clinical association is important to avoid an unnecessary surgery.

Acknowledgements

Conflicts of interest

There are no conflicts of interest.

References

- Demirel N, Baş AY, Zenciroğlu A, Taşçı-Yıldız Y. Adrenal bleeding in neonates: report of 37 cases. *Turk J Pediatr* 2011; **53**:43–47.
- Noviello C, Cobellis G, Muzzi G, Pieroni G, Amici G, Martino A. Neonatal adrenal hemorrhage presenting as contralateral scrotal hematoma. *Minerva Pediatr* 2007; **59**:157–159.
- Adorasio O, Mattei R, Ciardini E, Centonze N, Noccioli B. Neonatal adrenal hemorrhage mimicking an acute scrotum. *J Perinatol* 2007; **27**:130–132.
- Avolio L, Fusillo M, Ferrari G, Chiara A, Bragheri R. Neonatal adrenal hemorrhage manifesting as acute scrotum: timely diagnosis prevents unnecessary surgery. *Urology* 2002; **59**:601.
- Miele V, Galluzzo M, Patti G, Mazzoni G, Calisti A, Valenti M. Scrotal hematoma due to neonatal adrenal hemorrhage: the value of ultrasonography in avoiding unnecessary surgery. *Pediatr Radiol* 1997; **27**:672–674.
- Abdu AT, Kriss VM, Bada HS, Reynolds EW. Adrenal haemorrhage in a newborn. *Am J Perinatol* 2009; **26**:553–557.
- Kreeftenberg HG Jr, Zeebregts CJ, Tamminga RY, de Langen ZJ, Zijlstra RJ. Scrotal hematoma, anemia, and jaundice as manifestations of adrenal neuroblastoma in a newborn. *J Pediatr Surg* 1999; **34**:1856–1857.
- Sencan A, Karaca I, Bostanci Sencan A, Mir E. Inguinoscrotal hematocele of the newborn. *Turk J Pediatr* 2000; **42**:84–86.