

# Endometrial carcinoma with co-existing granulosa cell tumour in a post-menopausal woman: a case report

Nwadiokwu JI<sup>1</sup>[ID](#), Solaja TO<sup>1</sup>[ID](#), Okebalama VC<sup>1</sup>[ID](#), Ikechukwu UI<sup>2</sup>[ID](#), Ehioghae O<sup>3</sup>[ID](#), Awosusi BL<sup>4</sup>[ID](#), Akudinobi OK<sup>5</sup>[ID](#), Obinna-Chinatu N<sup>6</sup>[ID](#), Mbon I<sup>3</sup>[ID](#), Ayeni A<sup>3</sup>[ID](#)

<sup>1</sup>Department of Anatomic Pathology and Forensic Medicine, Babcock University Teaching Hospital, Ilishan-Remo, Ogun State, Nigeria

<sup>2</sup>Department of Medicine, Kuje General Hospital, Abuja, Nigeria

<sup>3</sup>Department of Surgery, Babcock University Teaching Hospital, Ilishan-Remo, Ogun State, Nigeria

<sup>4</sup>Department of Pathology, University College Hospital, Ibadan, Oyo State, Nigeria

<sup>5</sup>ENT Unit, Department of Surgery, Federal Medical Centre Birnin Kebbi, Kebbi State, Nigeria

<sup>6</sup>Federal Medical Centre, Umuahia, Abia State, Nigeria

Submitted: 13<sup>th</sup> September 2023

Accepted: 6<sup>th</sup> December 2023

Published: 31<sup>st</sup> December 2023

[ID](#): Orcid ID

## Abstract

**Background:** Granulosa cell tumors (GCT) of the ovary are extremely infrequent tumors accounting for about 3% of the entire ovarian malignancies with a very high rate of recurrence. Due to its ability to secrete estrogen unopposed, it can give rise to endometrial cancer thus leading to the coexistence of the two tumors on rare occasions.

**Case presentation:** We present here, the case of a 58-year-old post-menopausal Nigerian woman with GCT coexisting with endometrial carcinoma. She presented with abdominal pain, weakness, and post-menopausal vaginal bleeding. Examination revealed an irregular 30-week size abdominopelvic mass while an abdominopelvic ultrasonography showed a right ovarian mass and multiple uterine fibroids. However, the diagnosis of GCT coexisting with endometrial carcinoma was histologically confirmed. She has been clinically stable for ten months post-surgical intervention and completion of adjuvant chemotherapy (Cisplatin [75mg/m<sup>2</sup>] and Docetaxel [75mg/m<sup>2</sup>]).

**Conclusion:** Although rare, GCT can exist synchronously with endometrial carcinoma. This should form an important differential diagnosis in a post-menopausal woman with bleeding per vaginum as this is its most important clinical presentation. Total abdominal hysterectomy with bilateral adnexectomy should be done in older patients with GCT. Additionally, adjuvant chemotherapy may be of tremendous benefit to diagnosed patients.

**Keywords:** Endometrial carcinoma, Granulosa cell tumour, Postmenopausal vaginal bleeding, Recurrent tumour, Nigerian woman

## Introduction

Ovarian granulosa cell tumours (GCTs) arise from non-germ cell elements of the ovarian sex-cord

stroma. They are extremely rare, constituting about 2-5% of all ovarian cancers (1). Two histologic variants exist namely Juvenile and Adult (2). They

Correspondence:

Okebalama, Victor C

Department of Anatomic Pathology and Forensic Medicine,

Babcock University Teaching Hospital, Ilishan-Remo,

Ogun State, Nigeria

+2348062995816, [okebalsvictor@gmail.com](mailto:okebalsvictor@gmail.com)

occur more in menopausal and post-menopausal women with an associated elaboration of oestradiol, and less than 5% of these instances show a GCT relationship with endometrial cancer. (3, 4). We herein discuss a rare case of an ovarian GCT coexisting with a high-grade endometrial adenocarcinoma of the endometrioid variant in a 58-year-old Nigerian widow.

### Case presentation

#### *Clinical Presentation*

A 58-year-old post-menopausal Nigerian woman presented to our Gynaecology clinic on account of increasing lower abdominal mass, weight loss, generalized weakness, abdominal pain, and post-menopausal vaginal bleeding.

#### *Examination findings*

Examination revealed an obese, chronically ill patient with moderate pallor. There was an irregular abdominopelvic mass of 30 weeks' size on abdominal examination.

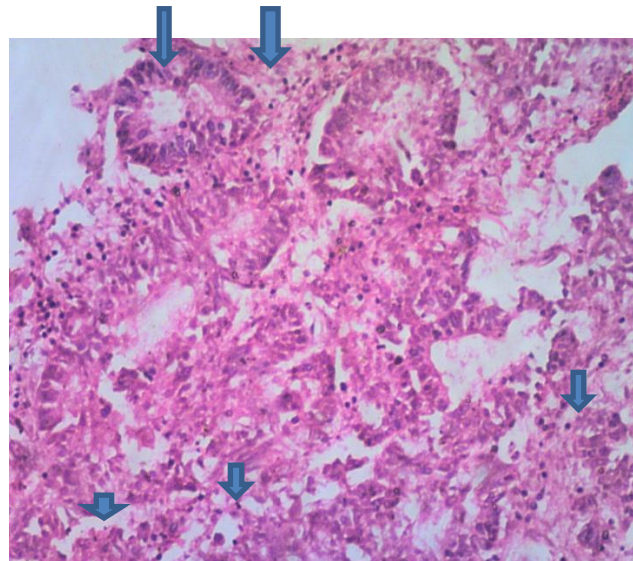
#### *Investigations*

An abdominopelvic ultrasound scan revealed a right ovarian mass and multiple uterine fibroids. Her Packed Cell Volume was 29%.

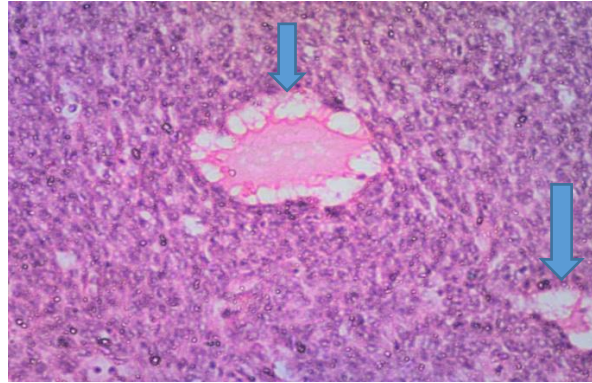
Macroscopic examination of the uterus following surgery revealed a firm uterus, weighing 400g and measuring 12.5x9.0x8.0cm. The cut surface showed an endometrial cavity containing greyish-white friable masses. Macroscopy of the right and left fallopian tubes, and ovaries were unremarkable.

Microscopically, sections of the endometrial masses showed a malignant epithelial neoplasm composed of malignant glands lined by markedly pleomorphic cells having hyperchromatic to vesicular nuclei, prominent nucleoli, and moderate eosinophilic cytoplasm (Figure 1). Multifocal solid areas were constituting more than 50% of the tumour. Areas of extensive necrosis and marked infiltration by chronic inflammatory cells were also seen. Sections of the cervix, right and left fallopian tubes, and the left ovary were unremarkable.

The histology of the right ovarian mass revealed a cellular lesion composed of tumour cells disposed of in sheets, insular and microfollicular patterns forming Call-Exner bodies in areas (Figure 2). The component cells had oval to round grooved nuclei, inconspicuous nucleoli, and moderate eosinophilic cytoplasm. Areas of stromal hyalinization, necrosis, haemorrhage, and thick-walled vascular channels were also seen. Furthermore, Sections of the myometrium showed foci of tumour invasion.



**Figure 1: (Haematoxylin and Eosin, E x 100 magnification); Section of the endometrial masses showing malignant endometrial glands (arrows) with focal areas of solid tumour nests (arrowheads)**



**Figure 2: (Haematoxylin & Eosin stain, X 100 magnification); Section of the ovarian mass showing solid sheets of granulosa cells with focal areas of Call-Exner bodies (arrows) in keeping with adult granulosa cell tumour**

#### *Treatment and Clinical Outcomes*

She had a unit of blood transfused and subsequently had an exploratory laparotomy. Intraoperative findings included moderate ascites, a huge multicystic right ovary with a grossly normal left ovary, general peritoneal hyperemia, normal-looking fallopian tubes, and a bulky uterus with multiple fibroids.

She had an uneventful post-operative period and declined adjuvant chemotherapy. She however represented four months later with advanced, metastatic tumour and ascites warranting adjuvant chemotherapy with Cisplatin (75mg/m<sup>2</sup>) and Docetaxel (75mg/m<sup>2</sup>). The chemotherapies were administered 3-weekly for six cycles, with five-day prophylactic dexamethasone (8mg; twice daily). Although she has been clinically stable for 10 months following the completion of her treatment (surgery and adjuvant chemotherapy), the overall prognosis is poor. This is because although she has made significant clinical improvement after the completion of chemotherapy, she has had recurrent anaemia with no evidence of bleeding per vaginum. A follow-up abdominal CT scan showed diffused liver lesions suspected to be ovarian liver metastasis. She has since been referred to the haematology and gastroenterology specialists for further management.

#### **Discussion**

GCTs are extremely rare, constituting about 2-5% of all ovarian cancers (1). The adult GCT represents its more common variant and it is more often seen in post-menopausal women (2). Prolonged exposure to high levels of oestrogen, especially unopposed predisposes to initial endometrial hyperplasia, paving the way for further dysplastic changes that may eventually culminate in malignant transformation. A major presenting

complaint of the adult GCT with co-existing endometrial hyperplasia or carcinoma is post-menopausal vaginal bleeding which was present in our patient. Established risk factors for endometrial carcinoma include obesity, nulliparity, early menarche, late menopause, type 2 diabetes mellitus, previous breast or ovarian malignancy, family history of endometrial or colorectal cancer, history of endometrial hyperplasia, and pelvic radiotherapy, with obesity being the major risk factor. This is due to the accentuated aromatization of androstenedione to estrone occurring in peripheral fat (5). Our patient had a significant risk factor – obesity. Generally, two groups of endometrial carcinomas exist; the first type which is highly associated with prolonged exposure to unopposed oestrogen (endogenous or exogenous) occurs more commonly in peri-menopausal women. This accounts for 65% of cases (6) and has a favourable prognosis. Histologically, it is also a low-grade carcinoma, with concomitant endometrial hyperplasia and minimal myometrial invasion. The second type usually has no identifiable predisposing factors (6), is not associated with hyperestrogenic states, and has no concomitant endometrial hyperplasia. They are high-grade, and aggressive, and occur in post-menopausal women, usually of Asian or African-American descent (7). Endometrioid carcinoma, the most common histologic subtype accounts for 75-80% of cases (8). High-grade tumours typically show an increased amount of nuclear atypia, demonstrated by pleomorphism, irregular chromatin clumping, prominent nucleoli, and significant solid components (9) as seen in our patient's histological evaluation. (Fig 1) Myometrial invasion remains an independent prognostic factor in management, with poorer outcomes observed in greater degrees of myometrial invasion. Zaino et.

al. in a study on endometrioid carcinoma observed 5-year survival rates of 94% with tumours confined to the endometrium, 91% with tumours involving the inner third of the myometrium, 84% with tumours extending to the middle third of the myometrium, and 59% with tumours infiltrating to the outer third of the myometrium respectively (10). Our patient showed histological evidence of tumour infiltration into the outer third of the myometrium. Surgery remains the cornerstone of treatment. In younger patients (< 40 years) who have not completed their family size, and have relatively normal endometrial biopsy findings, unilateral adnexectomy, and close follow-up can be done, as adult cell GCTs in young patients are often confined to one ovary (3). However, in older patients, like ours, a total abdominal hysterectomy with bilateral adnexectomy should be done (4). The role of adjuvant radiotherapy is controversial with some studies showing improved survival rates in newly-diagnosed patients and recurrent diseases. Other studies have however failed to demonstrate this benefit (1). Cisplatin, vinblastine, bleomycin or bleomycin, etoposide, and cisplatin regimens are sometimes employed as adjuvant chemotherapy with major indications being an early-stage disease with large tumours having high mitotic index or ruptured capsule (4). Although she earlier deferred chemotherapy treatment options, our patient later had late adjuvant chemotherapy after re-presenting with features suggestive of metastatic disease.

### Conclusion

Although rare, the occurrence of endometrial carcinoma with GCT should be suspected, especially in postmenopausal women presenting with bleeding per vaginum. The mainstay of treatment remains a total abdominal hysterectomy with bilateral adnexectomy, which was done in our index patient.

### List of Abbreviations

GCT: Granulosa cell tumors

### Declarations

*Ethics approval and consent to participate*

Noy applicable

### *Consent for publication*

All the authors gave consent for the publication of the work under the Creative Commons Attribution-Non-Commercial 4.0 license.

Availability of data and materials

The essential data supporting the findings of this study are available within the article. Additional data are available on request from the corresponding author due to confidential reasons.

### *Competing interests*

Authors declare no conflict of interest

### *Funding*

The authors declare that they had no funding source or financial support.

### *Author contributions*

All the authors were involved in the management of the patients and conceptualizing the report. OVC, EO, AA, IUI, MI, and ON wrote the first manuscript. OVC, AOK, ABL, STO, and NJI, corrected the manuscript. All the authors agreed on the final manuscript. The manuscript has been read and approved by all the authors

### *Acknowledgements*

None.

### References

1. Evans AT 3rd, Gaffey TA, Malkasian GD Jr, Annegers JF. Clinicopathologic review of 118 granulosa and 82 theca cell tumors. *Obstet Gynecol.* 1980;55(2):231-238
2. Young RH, Scully RE. Sex CordStromal, Steroid Cell, and Other Ovarian Tumors with Endocrine, Paraendocrine, and Paraneoplastic Manifestations. In: Kurman RJ, ed. *Blaustein's Pathology of the Female Genital Tract.* Springer New York; 1994:783-847. [https://doi.org/10.1007/978-1-4757-3889-6\\_19](https://doi.org/10.1007/978-1-4757-3889-6_19)
3. Ahya R, Ahya K, Patel U, Anand R, Leuva B, Chaudhary S. A rare case of granulosa cell tumor with coexistent endometrioid adenocarcinoma in a young woman. *International Journal of Students' Research; Vol 1, No 2 (2011): Taking Research Forward; 6163.* 2011;1. <https://doi.org/10.5549/IJSR.1.2.61-63>
4. Pectasides D, Pectasides E, Psyrris A. Granulosa cell tumor of the ovary. *Cancer Treat Rev.* 2008;34(1):1-12. <https://doi.org/10.1016/j.ctrv.2007.08.007>
5. Sidawy MK, Silverberg SG. Endometrial carcinoma. Pathologic factors of therapeutic and prognostic significance. *Pathol Annu.* 1992;27 Pt 2:153-185.
6. Smith M, McCartney AJ. Occult, high-risk endometrial cancer. *Gynecol Oncol.* 1985;22(2):154-161. [https://doi.org/10.1016/0090-8258\(85\)90021-6](https://doi.org/10.1016/0090-8258(85)90021-6)

7. Christopherson WM, Alberhasky RC, Connelly PJ. Carcinoma of the endometrium: I. A clinicopathologic study of clear-cell carcinoma and secretory carcinoma. *Cancer*. 1982;49(8):1511-1523.  
[https://doi.org/10.1002/1097-0142\(19820415\)49:8%3C1511::AID-CNCR2820490802%3E3.0.CO;2-6](https://doi.org/10.1002/1097-0142(19820415)49:8%3C1511::AID-CNCR2820490802%3E3.0.CO;2-6)
8. Hernandez E. Pathological findings and prognosis from uterine malignancy. *Curr Opin Obstet Gynecol*. 1993;5(4):480-485.  
<https://doi.org/10.1097/00001703-199308000-00009>
9. Lee AW, Templeman C, Stram DA, Beesley J, Tyrer J, Berchuck A, Pharoah PP, Chenevix-Trench G, Pearce CL, Ness RB, Dansonka-Mieszkowska A. Evidence of a genetic link between endometriosis and ovarian cancer. *Fertility and sterility*. 2016 Jan 1;105(1):35-43.  
<https://doi.org/10.1016/j.fertnstert.2015.09.023>
10. Zaino RJ, Kurman R, Herbold D, Gliedman J, Bundy BN, Voet R, Advani H. The significance of squamous differentiation in endometrial carcinoma. Data from a Gynecologic Oncology Group study. *Cancer*. 1991 Nov 15;68(10):2293-302.  
[https://doi.org/10.1002/1097-0142\(19911115\)68:10%3C2293::AID-CNCR2820681032%3E3.0.CO;2-V](https://doi.org/10.1002/1097-0142(19911115)68:10%3C2293::AID-CNCR2820681032%3E3.0.CO;2-V)