Morgan *et. al.,* Babcock Univ. Med. J.2026 9(3):266-271
https://doi.org/10.38029/babcockuniv.med.j..v9i3.1126

eISSN: 2756-4657

CASE REPORT OPEN ACCESS

Intracranial tuberculoma: A narrative review of clinical features, diagnosis, and management in resource-constrained settings

Morgan E[1], Nwadiokwu JI[2], Obinna A[3], Okechukwu B[3]

[1]*Department of Surgery, Babcock University and Teaching Hospital, Ilishan-Remo, Ogun State, Nigeria*
[2]*Department of Anatomic Pathology and Forensic Medicine, Babcock University Teaching Hospital, Ilishan-Remo, Ogun State, Nigeria*
[3]*Department of Orthopaedic and Traumatology, Lagos University Teaching Hospital, Lagos, Nigeria*

Submitted: 18th August 2025
Accepted: 24th April 2026
Published: 30th September 2026
ID: Orcid ID

Abstract
Background: Intracranial tuberculoma is a rare, non-neoplastic central nervous system condition, typically presenting as a ring-enhancing lesion on imaging. Its clinical manifestations are varied and nonspecific, often mimicking tumours or other infections, making diagnosis challenging. Management primarily involves prolonged anti-tuberculous therapy, supported by interventions based on the location and severity of the lesion. This paper reports the clinical presentations, diagnostic methods, and management of intracranial tuberculoma, showing key challenges in resource-constrained settings.
Case presentation: Case 1: A 25-year-old man presented with progressive gait instability, left-sided weakness, numbness, strabismus, dysarthria, and facial nerve palsy. Examination revealed a Glasgow Coma Score (GCS) of 15 and mild visual impairment. MRI showed a solitary, ring-enhancing brainstem lesion. Anti-tuberculous therapy (ATT) led to complete symptom resolution, with follow-up imaging at 12 months confirming full radiological recovery.
Case 2: A 36-year-old woman presented with worsening gait, facial asymmetry, visual decline, and altered consciousness. Her GCS was 11, and a positive Mantoux test supported a tuberculous aetiology. CT imaging revealed a ring-enhancing lesion in the left cerebellopontine angle, extending into the brainstem with obstructive hydrocephalus. CSF diversion was performed, and CSF analysis was consistent with tuberculosis. ATT was initiated, with clinical improvement noted. However, the patient was lost to follow-up after four months, despite initial symptom resolution.
Conclusion: Intracranial tuberculomas may present without systemic signs and require high clinical suspicion for diagnosis, particularly in endemic areas. In low-resource settings, barriers such as limited imaging access and socioeconomic factors can hinder diagnosis, adherence to therapy, and follow-up.

Keywords: Anti-tuberculous therapy, Intracranial, Resource-limited settings, Ring-enhancing lesion, Tuberculoma

Introduction

Intracranial tuberculoma represents a rare, non-neoplastic granulomatous lesion that often mimics intracranial neoplasms, presenting with nonspecific signs such as persistent headache, gait ataxia, visual disturbances, or complications from obstructive hydrocephalus (1, 2, 3). Central nervous system (CNS) involvement is documented in approximately 1–2% of all tuberculosis cases and 5–10% of extrapulmonary TB, with tuberculomas comprising a notable subset (4, 5). Brain imaging via MRI or CT is essential for diagnosis, yet no radiologic signature definitively differentiates tuberculomas from other ring-enhancing intracranial lesions (6, 7). Consequently,

Correspondence:
Morgan, Eghosa
Department of Surgery,
Babcock University, Ilishan-Remo,
Ogun State, Nigeria
+2348035724104, morganeghosa@gmail.com

© BUMJ. 2026 Open Access This article is distributed under the terms of the Creative Commons Attribution 4.0 International License (http://creativecommons.org/licenses/by/4.0/), which permits unrestricted use, distribution, and reproduction in any medium, provided you give appropriate credit to the original author(s) and the source, provide a link to the Creative Commons license, and indicate if changes were made. The Creative Commons Public Domain Dedication waiver (http://creativecommons.org/publicdomain/zero/1.0/) applies to the data made available in this article, unless otherwise stated.

diagnosis requires a high index of suspicion, particularly in patients without overt pulmonary disease or tuberculous meningitis (8). While the treatment cornerstone remains medical—typically comprising isoniazid, rifampicin, pyrazinamide, and ethambutol—surgical intervention may be warranted in cases of diagnostic uncertainty, neurological deterioration, or failure of medical therapy (3, 8, 9). Clinical and radiological surveillance, complemented by laboratory markers, is crucial to monitor treatment response (7, 8, 9). We present two patients with varied clinical presentations, diagnostic techniques, and management of' intracranial tuberculoma, ' emphasising key challenges in a resource-constrained setting.

Case Series

We report two cases of intracranial tuberculoma involving the posterior fossa in adults from tuberculosis-endemic regions of Nigeria.

Case 1

A 25-year-old man from Lagos, Nigeria, presented with a two-month history of progressive gait instability, left hemibody weakness, numbness, strabismus, visual decline, dysarthria, and facial weakness. Neurological examination revealed a Glasgow Coma Score (GCS) of 15 and intact higher mental functions. Visual acuity was 6/18 in the right eye and 6/12 in the left. Cranial nerve assessment showed left-sided ptosis with complete third cranial nerve palsy, upper motor neuron-type facial weakness (House–Brackmann Grade II), and upper motor neuron signs on the left side.

Systemic evaluation was unremarkable: chest radiography was normal, while the erythrocyte sedimentation rate (ESR) was elevated at 45 mm/hour. Contrast-enhanced T2-weighted brain magnetic resonance imaging (MRI) demonstrated a solitary, thick-walled, ring-enhancing lesion within the brainstem (Figure 1).

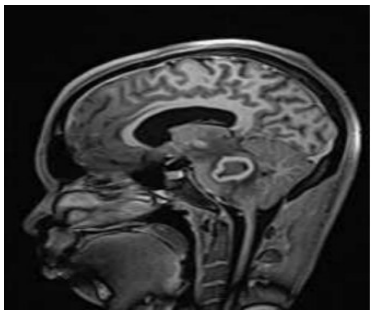

Figure 1: Contrast-enhanced brain MRI scan revealed a solitary thick-walled wall ring-enhancing lesion in the brainstem

A provisional diagnosis of brainstem space-occupying lesion—likely tuberculoma—was made. Given the unavailability of stereotactic biopsy, a therapeutic trial of anti-tuberculous therapy (ATT) was initiated while awaiting interferon-gamma release assay (IGRA) results (TB Quantiferon), which subsequently returned positive for *Mycobacterium tuberculosis*.

The patient received a standard 12-month ATT regimen: isoniazid, rifampicin, ethambutol, and pyrazinamide for the initial two months, followed by isoniazid and rifampicin for the remaining ten months. Clinical recovery was rapid, with resolution of neurological deficits. Repeat MRI at 12 months demonstrated complete disappearance of the brainstem lesion (Figure 2), correlating with full symptomatic resolution.

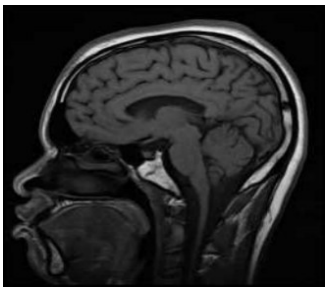

Figure 2: Repeat brain MRI scan showing no brainstem lesion after 12 months of anti-TB medications, which was in tandem with clinical resolution of symptoms

Case 2

A 36-year-old primary school teacher from Edo State, Nigeria, presented with a progressive history of gait instability, facial deviation, visual deterioration, and altered consciousness. She reported no systemic symptoms suggestive of tuberculosis. On admission, neurological examination revealed a Glasgow Coma Score (GCS) of 11 (E3V3M5). Both pupils were sluggishly reactive to light. Additional findings included left-sided ptosis, lower motor neuron-type facial weakness, and right hemiparesis.

The Mantoux test was positive, with an induration of 15 mm. Chest radiography was normal, while the erythrocyte sedimentation rate (ESR) was elevated at 78 mm/hour. Contrast-enhanced computed tomography (CT) of the brain demonstrated a solitary, thick-walled, ring-enhancing lesion in the left cerebellopontine angle, extending into the brainstem and associated with obstructive hydrocephalus (Figure 3).

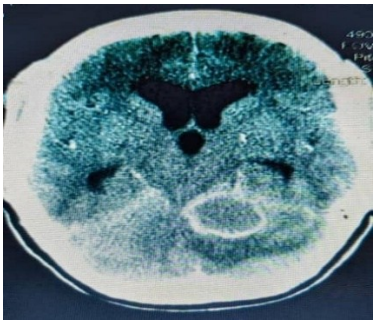

Figure 3: Contrast-enhanced brain CT scan revealed a solitary thick-wall ring-enhancing lesion in the left cerebellopontine angle with extension to the brainstem area

A provisional diagnosis of cerebellopontine angle space-occupying lesion with obstructive hydrocephalus—likely tuberculoma—was made. The patient underwent emergency cerebrospinal fluid (CSF) diversion. CSF analysis was suggestive of tuberculosis, and anti-tuberculous therapy (ATT) was initiated while awaiting confirmatory results, which later returned positive for *Mycobacterium tuberculosis*.

The patient was commenced on a 12-month ATT regimen: isoniazid, rifampicin, ethambutol, and pyrazinamide for the first two months, followed by isoniazid and rifampicin for the remaining ten months. She demonstrated marked clinical improvement within the first four months of therapy; however, she defaulted subsequent follow-up despite multiple attempts to re-establish contact. At her last clinical review, all presenting symptoms and neurological signs had resolved.

Review of Literature and Discussion

Intracranial tuberculoma is a rare manifestation of central nervous system (CNS) tuberculosis attributable to *Mycobacterium tuberculosis*. It predominantly affects paediatric and immunocompromised populations, particularly within resource-limited regions (10, 11, 12, 13, 14, 15). Although precise incidence figures for intracranial tuberculoma in Nigeria are lacking, patterns reported from India—where endemic-area rates reach 20–30%—indicate that the burden is likely far higher than in high-income countries such as the UK, where documented frequencies are only 0.15–0.18% (16, 17).

This condition typically develops via hematogenous dissemination from pulmonary or other systemic foci, occasionally through direct contiguous spread. The initial seeding is followed by caseous necrosis, granuloma formation, and lesion maturation within the brain parenchyma (14). Common anatomical sites include the frontoparietal lobes, basal ganglia, corpus callosum, cerebellopontine angle, and ventricular regions.

Clinical presentation lacks specificity. Clinical features may include persistent headache, gait ataxia, cranial nerve palsies, visual or auditory deficits, vomiting due to raised intracranial pressure, or, in paediatric cases, developmental delays (10, 18, 19). In rare instances, midbrain involvement can manifest as Weber's syndrome, characterised by ipsilateral ocular motor deficits with contralateral hemiplegia (19). Both of our cases featured such nonspecific neurological manifestations, mirroring patterns described in the literature.

Neuroimaging is indispensable yet not definitively diagnostic. On brain MRI and CT scan, tuberculomas frequently appear as thick-walled, ring-enhancing lesions with variable degrees of perilesional oedema, mass effect, midline shift, and possible meningeal enhancement (20, 21, 22). On brain MRI, caseating granulomas often exhibit central T2 hypointensity with a surrounding hyperintense

rim and vasogenic oedema, sometimes accompanied by lipid-lactate peaks on spectroscopy (14, 23, 24). These imaging characteristics can closely mimic high-grade gliomas, radiation necrosis, abscesses, metastases, or neurocysticercosis (21, 23). However, the conglomerate ring-like enhancement, along with characteristic signal intensities on T1/T2 sequences, may support a presumptive diagnosis of intracranial tuberculoma (18, 25).

Medical management remains the cornerstone of treatment, typically involving first-line anti-tuberculous therapy (ATT): isoniazid, rifampicin, pyrazinamide, and ethambutol for two months, followed by isoniazid and rifampicin for 10–12 months (26). Surgical intervention may be indicated for obstructive hydrocephalus, mass effect, diagnostic uncertainty, or treatment failure. Histopathological examination, when available, characteristically reveals central caseation surrounded by granulomatous inflammation; however, the absence of bacilli on staining does not exclude the diagnosis (27).

Close monitoring of treatment response through clinical evaluation, laboratory markers such as erythrocyte sedimentation rate (ESR) and lymphocyte counts, and serial neuroimaging is critical (26, 28). In our case series, one patient achieved complete resolution on MRI after 12 months of ATT, while the second was lost to follow-up after four months, reflecting the real-world challenges in compliance with the treatment protocol within resource-constrained settings.

Socioeconomic factors significantly impact outcomes. In Nigeria—recently referred to as the "poverty capital of the world"—many individuals subsist on less than US$1 per day. A recent study by Varrella et al., for instance, revealed an estimated average monthly individual income of approximately NGN 43,200 (US$111) and family income at NGN 137,600 (US$354) (29). These financial limitations likely contributed to the second patient's discontinuation of follow-up, despite earlier symptomatic improvement. This could be catastrophic with the likelihood of multi-drug resistance and complications during the course of treatment.

Conclusion

Intracranial tuberculomas are a rarity in neurosurgical practice, it requires a high index of clinical suspicion for diagnosis, particularly in endemic areas. In low-resource settings such as Nigeria, several barriers, such as late presentations, limited brain imaging access, poor clinical follow-up, and dwindling resources, can hinder making a diagnosis, initiation and adherence to anti-tuberculous therapy, and clinical follow-up.

List of Abbreviations

CSF: Cerebrospinal fluid
CT: Computed tomography
ESR: Erythrocyte sedimentation rate
GCS: Glasgow coma score
MRI: Magnetic resonance imaging
TB: Tuberculosis

Declarations

Ethics Approval and Consent to Participate
Consent to participate was obtained from the patients

Consent for publication
Not applicable

Availability of data and material
Not applicable

Competing interest
The authors declare that they have no competing interests in this section.

Funding
Not applicable

Authors Contributions
EM: Conceptualisation, Writing- editing and Discussion
NJI, OA and OB: Editing and discussion

Acknowledgement
Not applicable

Reference

1. Mishra R, Shrivastava A, Raj S, Chouksey P. Intracranial tuberculomas and tubercular abscess-overcoming challenges. Neurology India. 2021;69:2-10. https://doi.org/10.4269/ajtmh.23-0183
2. Lazarte-Rantes C, Sinti-Ycochea M, Guillen-Pinto D. Intracranial manifestations of central nervous system tuberculosis in children. Pediatric Radiology. 2025 Jan;55(1):88-103. https://doi.org/10.1007/s00247-024-06057-6
3. Wasay M, Kheleani BA, Moolani MK, Zaheer J, Pui M, Hasan S, Muzaffar S, Bakshi R, Sarawari AR. Brain CT and MRI findings in 100 consecutive patients with intracranial tuberculoma. Journal of Neuroimaging. 2003 Jul;13(3):240-7. https://doi.org/10.1111/j.1552-6569.2003.tb00185.x
4. Wasay M, Younis S. Central Nervous System Tuberculosis. World Neurology. 2024 Sep 10.
5. Lee RD, Atencio A. CNS tuberculomas. Journal of General Internal Medicine. 2023

Aug;38(11):2621-. https://doi.org/10.1007/s11606-023-08264-7
6. Muljadi R, Sutanto R, Fransiska SR, Takaliuang D, Erico A. Intracranial tuberculomas: review of MRI findings and clinical features. Clinical Radiology. 2024 May 1;79(5):354-62. https://doi.org/10.1016/j.crad.2023.12.020
7. Thwaites G, Fisher M, Hemingway C, Scott G, Solomon T, Innes J. British Infection Society guidelines for the diagnosis and treatment of tuberculosis of the central nervous system in adults and children. Journal of Infection. 2009 Sep 1;59(3):167-87. https://doi.org/10.1016/j.jinf.2009.06.011
8. Mahomed N, Kilborn T, Smit EJ, Chu WC, Young CY, Koranteng N, Kasznia-Brown J, Winant AJ, Lee EY, Sodhi KS. Tuberculosis revisted: classic imaging findings in childhood. Pediatric Radiology. 2023 Aug;53(9):1799-828. https://doi.org/10.1007/s00247-023-05648-z
9. Saifon W, Karaketklang K, Jitmuang A. Distinguishing clinical characteristics of central nervous system tuberculosis in immunodeficient and non-immunodeficient individuals: a 12-year retrospective study. Annals of Clinical Microbiology and Antimicrobials. 2023 Aug 7;22(1):69. https://doi.org/10.1186/s12941-023-00615-w
10. Oo N, Agrawal DK. Epidemiology, pathogenesis, clinical manifestations, and management strategies of tuberculous meningitis. Archives of Internal Medicine Research. 2025 Feb 10;8(1):48. https://doi.org/10.26502/aimr.0195
11. Wasay M, Moolani MK, Zaheer J, Khealani BA, Smego RA, Sarwari AR. Prognostic indicators in patients with intracranial tuberculoma: a review of 102 cases. Journal of Pakistan Medical Association. 2004;54(2).
12. Dastur DK. Neurosurgically relevant aspects of pathology and pathogenesis of intracranial and intraspinal tuberculosis. Neurosurgical Review. 1983 Sep;6(3):103-10. https://doi.org/10.1007/BF01742761
13. Ravenscroft A, Schoeman JF, Donald PR. Tuberculous granulomas in childhood tuberculous meningitis: radiological features and course. Journal of Tropical Pediatrics. 2001 Feb 1;47(1):5-12. https://doi.org/10.1093/tropej/47.1.5
14. Anderson JM, Macmillan JJ. Intracranial tuberculoma--an increasing problem in Britain. Journal of Neurology, Neurosurgery & Psychiatry. 1975 Feb 1;38(2):194-201.M https://doi.org/10.1136/jnnp.38.2.194
15. Sonmez G, Ozturk E, Sildiroglu HO, Mutlu H, Cuce F, Senol MG, Kutlu A, Basekim CC, Kizilkaya E. MRI findings of intracranial tuberculomas. Clinical Imaging. 2008 Mar 1;32(2):88-92. https://doi.org/10.1016/j.clinimag.2007.08.024
16. Radiopaedia contributors. Epidemiology of intracranial tuberculomas. Radiopaedia.org. Updated May 21 2025. Accessed 16 Dec 2025. Available from: https://radiopaedia.org/articles/epidemiology-of-intracranial-tuberculomas
17. Ibrahim IG, Osman AA, Shikhow MG, Celik C, Mutlu E, Tahtabaşı M. Magnetic resonance imaging findings of intracranial tuberculoma patients in a tertiary hospital in Mogadishu, Somalia: a retrospective study. Annals of Medicine and Surgery. 2022 Jun 1;78:103812. https://doi.org/10.1016/j.amsu.2022.103812
18. Maheswari EU, Bhoopathy RM, Bhanu K, Anandan H. Clinical spectrum of central nervous system tuberculosis and the efficacy of revised national tuberculosis control program in its management. Journal of Neurosciences in Rural Practice. 2019 Jan;10(1):71. https://doi.org/10.4103/jnrp.jnrp_163_18
19. Marais S, Roos I, Mitha A, Patel V, Kalincik T, Bhigjee AI. Presentation and outcome of patients with intracranial tuberculoma in a high HIV prevalence setting. Int J Tuberc Lung Dis. 2020 Feb 1;24(2):224-32. https://doi.org/10.5588/ijtld.19.0386
20. Baloji A, Ghasi RG. MRI in intracranial tuberculosis: Have we seen it all?. Clinical Imaging. 2020 Dec 1;68:263-77. https://doi.org/10.1016/j.clinimag.2020.08.028
21. Swamy SB, Jaikumar V, Nagaraj NM, Khandelwal S. Intracranial giant tuberculoma: A 7-year institutional experience and literature review. Clinical Neurology and Neurosurgery. 2023 Feb 1;225:107593. https://doi.org/10.1016/j.clineuro.2023.107593
22. Bargallo N, Berenguer J, Tomas X, Nicolau C, Cardenal C, Mercader JM. Intracranial tuberculoma: CT and MRI. European Radiology. 1993 Apr;3(2):123-8. https://doi.org/10.1007/BF00169784
23. Kim TK, Chang KH, Kim CJ, Goo JM, Kook MC, Han MH. Intracranial tuberculoma: comparison of MR with pathologic findings. American Journal of Neuroradiology. 1995 Oct 1;16(9):1903-8.
24. Zaleskis R, Mariani AW, Inzirillo F, Vasilyeva I. The role of surgery in tuberculosis management: indications and contraindications. Cham: Springer International Publishing. InEssential Tuberculosis 2021 Jul 27 (pp. 141-148).

https://doi.org/10.1007/978-3-030-66703-0_15
25. World Health Organization, Stop TB Initiative (World Health Organization). Treatment of tuberculosis: guidelines. World Health Organization; 2010 July 15.
26. Stadelman AM, Ellis J, Samuels TH, Mutengesa E, Dobbin J, Ssebambulidde K, Rutakingirwa MK, Tugume L, Boulware DR, Grint D, Cresswell FV. Treatment outcomes in adult tuberculous meningitis: a systematic review and meta-analysis. US: Oxford University Press. InOpen Forum Infectious Diseases 2020 Aug (Vol. 7, No. 8, p. ofaa257). https://doi.org/10.1093/ofid/ofaa257
27. Rohlwink UK, Mauff K, Wilkinson KA, Enslin N, Wegoye E, Wilkinson RJ, Figaji AA. Biomarkers of cerebral injury and inflammation in pediatric tuberculous meningitis. Clinical Infectious Diseases. 2017 Oct 15;65(8):1298-307. https://doi.org/10.1093/cid/cix540
28. Yao XP, Hong JC, Jiang ZJ, Pan YY, Liu XF, Wang JM, Fan RJ, Yang BH, Zhang WQ, Fan QC, Li LX. Systemic and cerebrospinal fluid biomarkers for tuberculous meningitis identification and treatment monitoring. Microbiology Spectrum. 2024 Jan 11;12(1):e02246-23. https://doi.org/10.1128/spectrum.02246-23
29. Onwujekwe O, Hanson K, Uzochukwu B. Examining inequities in incidence of catastrophic health expenditures on different healthcare services and health facilities in Nigeria. PloS One. 2012 Jul 16;7(7):e40811. https://doi.org/10.1371/journal.pone.0040811