

*East African Medical Journal Vol. 86 No. 10 October 2009*

#### HEREDITARY GINGIVAL FIBROMATOSIS: REPORT OF FAMILY CASE SERIES

E. G. Wagaiyu, BDS, MSc (Lond.) Senior Lecturer, Department of Periodontology / Community and Preventive Dentistry, School of Dental Sciences, University of Nairobi, P.O. Box 19676-00202, Nairobi, Kenya, R. N. Ng'ang'a, BDS (Nrb), MDS (Nrb), Principal Lecturer, Department of Community Oral Health, Kenya Medical Training College, P.O. Box 30195, Nairobi, Kenya and A. M. Kemoli, BDS (Nrb) MSc (A'dam), Lecturer, Department of Paediatric Dentistry / Orthodontics School of Dental Sciences, University of Nairobi, P.O. Box 34848-00100, Nairobi, Kenya

Request for reprints to: Dr. E. G. Wagaiyu, P.O. Box 54197-00200, Nairobi, Kenya

## HEREDITARY GINGIVAL FIBROMATOSIS: REPORT OF FAMILY CASE SERIES

E. G. WAGAIYU, R. N. NG'ANG'A and A. M. KEMOLI

### SUMMARY

Hereditary gingival hyperplasia (HGF) is a rare condition characterised by hyperplastic, dense fibrous connective tissue with acanthotic gingival epithelium. A family presented at the School of Dental Sciences, University of Nairobi with a complaint that some of the children developed swollen gums very early in life and that this got worse with eruption of the permanent teeth. The first born, a 23-year-old male, had had the swellings for over ten years. Other siblings aged 5, 9 and 12 years were also affected. The swellings had affected the appearance, speech and the psychosocial wellbeing of the children. The parents were unaffected with apparently negative family histories. Following oral examination and appropriate investigations, conventional gingivectomy was performed of the maxillary and the mandibular gingivae for the siblings: the 23-year-old and the nine-year olds. The fourth affected child, a five-year-old, was still in primary dentition and had just started showing mild signs of gingival hyperplasia. The histopathological examination of the specimens from the present cases confirmed features consistent with those of HGF. This article highlights a familial presentation of HGF.

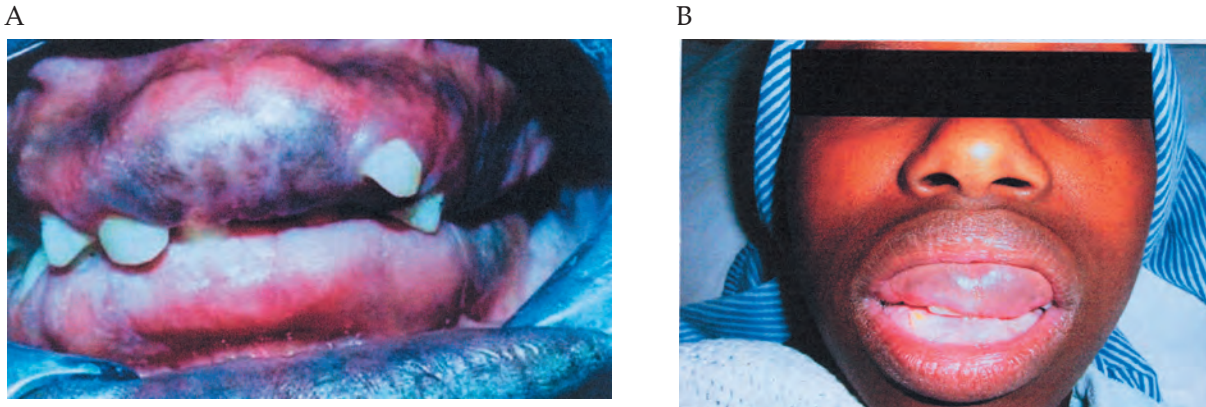
### INTRODUCTION

Hereditary gingival fibromatosis (HGF) is a rare disease occurring at the rate of 1 in 750,000 and; is reported to be autosomal dominant although autosomal recessive inheritance has been published (1-3). Gene mapping of HGF has placed the loci on chromosome 2p22-p21 and 5q13-q22 (4). Thus two separate genetic loci are responsible for the autosomal dominance. It has no sex prevalence and is characterised by a slow progressive enlargement of both maxillary and mandibular gingivae. HGF is mainly associated with the permanent dentition although the primary dentition may also be involved. It can also occur as an isolated case with only the gingival involved or form part of a syndrome (5). When involved with other features

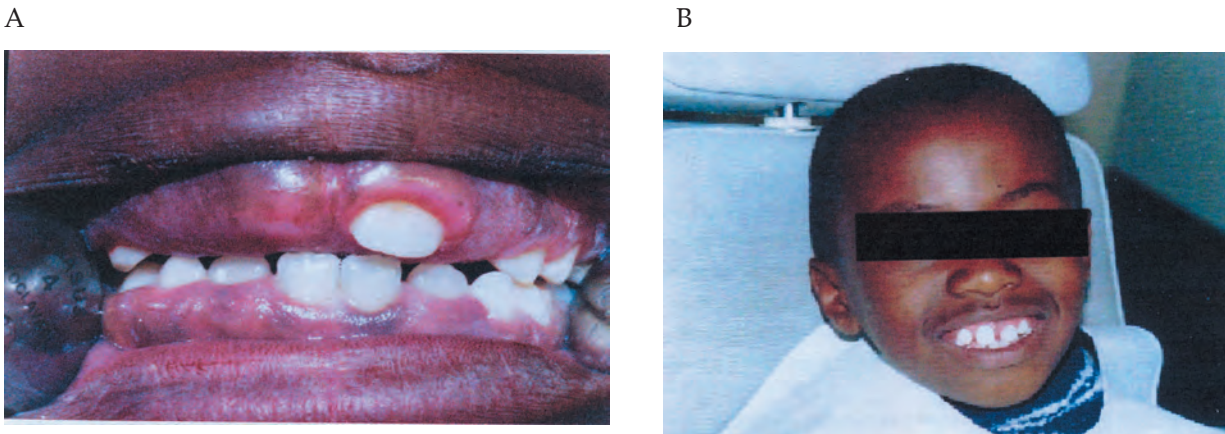
HGF has been associated in many reports with hypertrichosis and /or mental retardation and epilepsy.

The association of gingival fibromatosis (GF) and corneal dystrophy is recognised as an autosomal dominant trait known as the Rutherford syndrome (6). The Cross syndrome is, almost certainly, an autosomal recessive disorder characterised by GF, microphthalmia, mental retardation and pigmentary defects (6). The Ramon syndrome is another, probably autosomal recessive condition involving GF as well as hypertrichosis, mental retardation, delayed development, epilepsy and cherubism (7). The Laband syndrome has features of GF, syndactily, nose and ear abnormalities and hypoplasia of the nails and terminal phalanges (5). We report three familial non-syndromic cases of HGF.

**Figure 1A and B**  
*Clinical presentation of gingival fibromatosis*



**Figure 2A and B**  
*Early presentation of gingival fibromatosis (A) and the appearance after gingivectomy (B)*



#### CASE REPORT

A family presented at the University of Nairobi Dental Hospital seeking treatment for the swollen gums of some of their children. The swellings tended to get worse with the eruption of permanent teeth. A family history revealed that four out of the eight children aged between 5 and 23 years had experienced swelling of the gingivae.

After oral examination and appropriate records with study casts and radiographs, conventional gingivectomy was performed for three of the siblings: the 23-, 12- and 9 year-olds. Maxillary and mandibular vestibular and palatal gingivectomy using the reverse bevel incision was done to remove as much of the excess tissue as possible. The displaced teeth were exposed and post-operative periodontal dressing was placed, antibiotic cover and chlorhexidine mouthwash/ given. No post-operative complications were encountered. The excised gingival tissues on histopathological examination revealed hyperplastic parakeratinized stratified squamous epithelium covering a corium containing bands of maturing fibrous connective tissue held in chronically inflamed stroma suggestive of HGF.

#### DISCUSSION

Hereditary gingival hyperplasia is a rare condition and has been reported to be autosomal dominant. Bozzo *et al.* (1) reported this condition in a four-generation pedigree with 50 of the 105 family members at risk developing GF. Autosomal recessive inheritance has also been reported (2,8). This condition can occur in isolation or as part of a syndrome. Some of the associated features are hypertrichosis, mental retardation, epilepsy, progressive hearing loss and abnormality of the extremities. The present cases however, did not present with any of the preceding features and had no medical problems.

HGF often manifests during the mixed dentition stage in most cases. It is a gradual process of deposition of fibrous connective tissue which displaces erupting permanent teeth with individuals giving a history of exfoliation of the primary dentition without the full eruption of the secondary dentition or completely absent secondary dentition. On clinical examination, the enlarged gingivae appear normal in colour, feel firm and nodular in texture and excessive stippling is seen. Histologically, the appearance is that of a hyperplastic epithelium with elongated rete ridges

extending deeply into the underlying connective tissue. Coarse and fine dense bundles of collagen oriented in all directions and a few fibroblasts make up the connective tissue layer. It has been shown in the literature that the enlargement is due to the thickening of collagen bundles in the connective tissue stroma as well as an excessive production of extracellular matrix (9).

The enlarging gingivae delays eruption and displaces the erupted teeth resulting in mal-alignment of the dentition. The primary dentition is not usually affected but when this happens, the teeth are also displaced (5). Timely surgical and orthodontic intervention may result in a reasonably good occlusion. A good oral hygiene should be maintained to avoid recurrence of the gingival hyperplasia. It is, therefore, important for health personnel to be aware of this condition and the fact that treatment is available. Gingivectomy is recommended during the late mixed dentition to avoid gross displacement of the erupting permanent dentition and later at the age of 18-20 years because in most cases recurrence occurs. Recurrence is common until the age of 18 years when the continued growth slows down. The psychological benefits resulting from the cosmetic improvement far-outweigh the risk of recurrence. Regular follow-up and long-term orthodontic treatment is recommended to avoid inflammation and control of displacement of the teeth.

#### ACKNOWLEDGEMENTS

To the Dean of the School of Dental Sciences University of Nairobi for permission to publish this case series report. We would also wish to thank the family involved for agreeing to the publication of the work.

#### REFERENCES

1. Bozzo, L, de Almedia, O. P., Scully, C. and Aldred M. J. Hereditary gingival fibromatosis. Report of an extensive four-generation pedigree. *Oral. Surg. Oral. Med. Oral. Pathol.* 1994; **78**: 452-454.
2. Bozzo, L., Machado, M. A. N., Lopes, M. A., et al. Hereditary gingival fibromatosis; report of three cases. *J. Clin. Pediatr. Dent.* 2000; **25**: 41-46.
3. Kelekis-Cholakakis, A., Wiltshire, W. A. and Birek, C. Treatment and long term follow up of a patient with hereditary gingival fibromatosis: A case report. *J. Can. Dent. Ass.* 2002; **68**: 290-294.
4. Mangino, M., Pizzuti, A., Dallapiccola, B., et al. Hereditary gingival fibromatosis (HGF) with hypertrichosis is unlinked to the HGF1 and HGF2 loci. (Letter) *Am. J. Med. Genet.* 2003; **116A**: 312-314.
5. Bittencourt, L. P., Campos, V., Moliterno, L. F. M., et al. Hereditary gingival fibromatosis: Review of the literature and a case report. *Quintessence Intern.* 2000; **31**: 415-418.
6. Aldred, M. J. and Bartold, P.M. Genetic disorders of the gingivae and periodontium. *J. Periodontol.* 2000; **18**: 7-20.
7. Pina-Neto, J. M., Moreno, A. F., Silva, L. R. et al. Cherubism, gingival fibromatosis, epilepsy, and mental deficiency (Ramon syndrome) with juvenile rheumatoid arthritis. *Am. J. Med. Gen.* 1986; **25**: 433-441. [Medline]
8. Gorlin, R. J., Cohen, M. M. and Levin, L. S. Syndromes of the head and neck. 3rd ed. New York: *Oxford University Press.* 1990: pp 666-673.
9. Araujo, C. S. A., Graner, E., Almeida, O.P. et al. Histomorphometric characteristics and expression of epidermal growth factor and its receptor by epithelial cells of normal gingiva and hereditary gingival fibromatosis. *J. Periodont. Res.* 2003; **38**: 237-241.