

East African Medical Journal Vol. 79 No. 4 April 2002

MULTIPLE SUPERNUMERARY TEETH IN ASSOCIATION WITH MALOCCLUSION - REPORT OF TWO CASES

P.M. Ng'ang'a, BDS., D.Ortho, MSD., PhD. Senior Lecturer, Department of Paediatric Dentistry and Orthodontics, S.W. Guthua, BDS., MMEDSC., COMS., FIAOMS, Associate Professor, Department of Oral and Maxillofacial Surgery, Faculty of Dental Sciences, University of Nairobi, P.O. Box 19676, Nairobi, Kenya and R.N. Ng'ang'a, BDS. Lecturer, Department of Community Oral Health, Kenya Medical Training College, P.O. Box 30195, Nairobi, Kenya.

Request for reprints to: Dr. P. M. Ng'ang'a, Department of Paediatric Dentistry and Orthodontics, Faculty of Dental Sciences, University of Nairobi, P.O. Box 19676, Nairobi, Kenya.

MULTIPLE SUPERNUMERARY TEETH IN ASSOCIATION WITH MALOCCLUSION: REPORT OF TWO CASES

P.M. NG'ANG'A, S. W. GUTHUA and R.N. NG'ANG'A

SUMMARY

Although multiple supernumerary teeth without any associated syndromes are rare, their occurrence can create a variety of clinical problems such as derangement of the occlusion, prevention of eruption of permanent teeth, damage to adjacent teeth, cystic degeneration and root resorption. Hence, clinical and radiographic evaluation of patients should always be thorough in order to detect their presence. Furthermore, because the clinical management of multiple supernumerary teeth poses a great challenge to clinicians, timely, appropriate consultation and interdisciplinary approach to treatment is extremely important. We report two cases, a 14 year-old boy with eight and a 13-year-old girl with seven supernumerary teeth not associated with syndromes. In the boy, the teeth were bilaterally distributed in all quadrants in the premolar regions, and in the girl they were distributed bilaterally in the premolar regions in the mandible and bilaterally distal to the upper third molars. The clinical implications and management are discussed.

INTRODUCTION

Classified strictly, supernumerary teeth are a form of extra teeth which are clearly recognisable as teeth but would not be mistaken for those of the normal series. This distinguishes them from other forms of extra teeth such as supplementals which resemble teeth of the normal series and odontomes which are multiple small teeth or irregular masses of dental tissue(1). The occurrence of supernumerary teeth varies in different populations. Studies indicate values between 1 - 3.5% in the permanent dentition compared to 0.3 - 0.6% in the deciduous dentition(2).

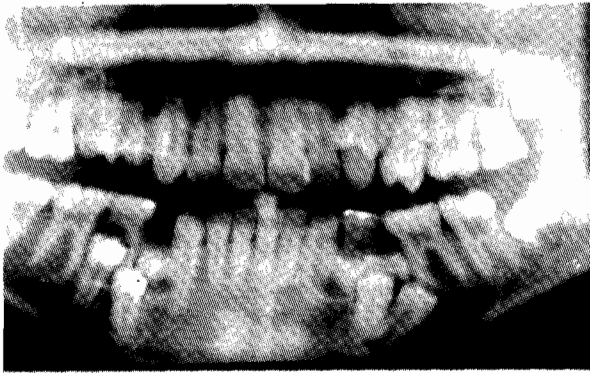
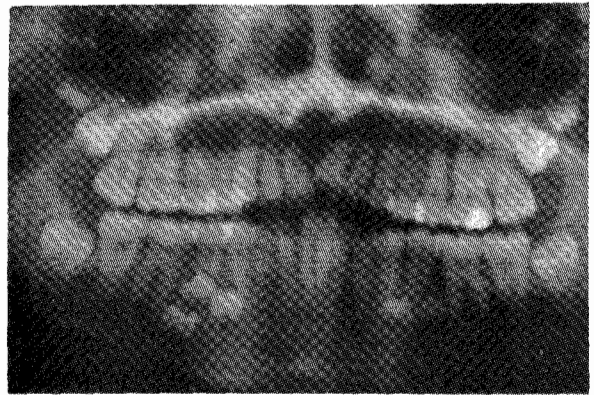
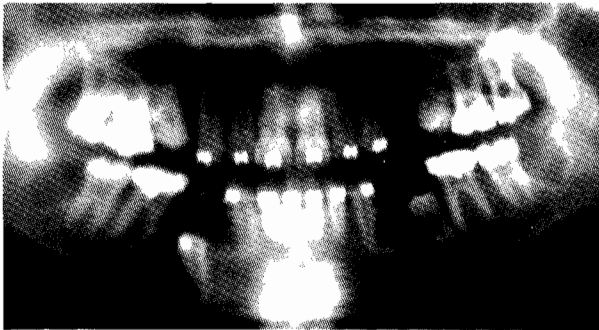
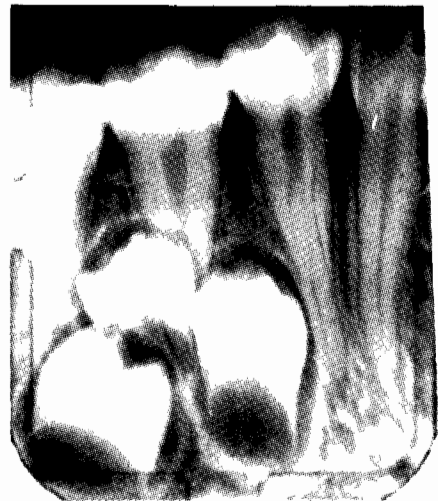Supernumerary teeth arise from a developmental disturbance of the tooth bud, the nature of which is not well understood. Some cases are familiar and may have a genetic background. The occasional presence of extra teeth in the same mouth as missing teeth (hypo-hyperdontia) suggests that they are not atavistic manifestations(3). Supernumerary teeth may be found either singly or in multiples(4). Multiple supernumerary teeth without any associated syndromes are rare(5). The teeth may create a variety of clinical problems such as derangement of the occlusion, prevention of eruption of permanent teeth, damage to adjacent teeth, cystic degeneration and root resorption(6). Early detection and timely management of these teeth is therefore essential. Literature search revealed

scanty documentation of supernumerary teeth in Africa(7,8). We report two cases of non-syndrome multiple supernumerary teeth and discuss the clinical implications and management.

CASE REPORTS

Case 1: A 14 year-old boy presented at an orthodontic clinic seeking an opinion regarding failure of eruption of some teeth in the lower jaw. The only past dental history was that the patient had had extractions of deciduous teeth. The medical history was non-contributory. Clinical examination showed an Angle's Class I malocclusion with mild crowding in the upper anterior segment, bilateral severe crowding in the premolar region, 14 in scissor bite, and over-retained 75 and 85. The 34, 44, 45 were not visible clinically. Standard orthodontic records were ordered. Evaluation of the Orthopantomograph (OPG) revealed a total of eight impacted supernumerary teeth (Figure 1). The teeth were bilaterally distributed in all four quadrants in the premolar regions. In view of the complex nature of the arrangement of the teeth, an immediate consultation with an oral-maxillofacial surgeon was sought.

Surgical removal of the supernumerary teeth was undertaken uneventfully under general anaesthesia. In addition, the four first premolars were removed to facilitate unravelling of the general crowding. Surgical exposure of 35 and 45 was done followed by orthodontic traction of the 35 (Figure 2). Full fixed orthodontic treatment was completed in 24 months.

Figure 1*Orthopantomograph showing eight supernumerary teeth in case 1***Figure 3***Orthopantomograph showing seven supernumerary teeth in case 2***Figure 2***Post surgery orthopantomograph showing orthodontic traction of 35 in case 1***Figure 4***Intraoral periapical radiographs showing close proximity of the supernumeraries to the root apices of 35 and 45 in case 2*

Case 2: A 13-year-old girl presented at an orthodontic clinic seeking a second opinion with regard to the progress of her treatment which was being undertaken by a dental practitioner. She had been wearing a removable appliance to re-align the upper anterior teeth for the previous two years with little improvement. She had no relevant medical history. Clinical examination revealed an Angle's Class I malocclusion with moderate crowding in the upper anterior segment, mild crowding in the lower anterior segment, overlap of 11 with 21, rotation of 21, and crossbite of 25 and 35. The OPG (Figure 3) revealed presence of all the permanent teeth and, in addition, there were seven unerupted supernumerary teeth. The supernumeraries were bilaterally distributed in the premolar regions in the mandible and bilaterally distal to the upper 3rd molars. Further investigation with intra-oral periapical radiographs showed close proximity of the supernumeraries to the root apices of 35 and 45 (Figure 4).

In consultation with an oral-maxillofacial surgeon, the prescribed treatment plan was removal of all supernumerary teeth, third molars, upper first premolars and lower second premolars under general anaesthesia, followed by full fixed orthodontic appliances in both jaws to realign the remaining teeth.

DISCUSSION

The clinical cardinal sign of erupted supernumerary teeth in an individual is an increase in the number of teeth. The presence of unerupted supernumerary teeth can be suspected where there is abnormal axial inclination of teeth in an area, local spacing especially in the upper central incisor region or failure of permanent teeth to

erupt(9). The majority of unerupted supernumerary teeth, however, do not cause any symptoms and therefore may only be detected during routine dental radiography. This is a major handicap in the developing countries as it is not always possible to obtain the necessary radiographs due to limited resources. While instances of one or two supernumerary teeth is a relatively common finding, multiple supernumeraries without associated syndromes like the ones reported here are quite uncommon(4). When they occur, they create occlusal disharmony by displacing and/ or preventing eruption of teeth of the normal series. In Case 1, failure of exfoliation of teeth no. 75 and 85 was due to the fact that the respective successor teeth had been obstructed from eruption by the supernumerary teeth. Since root formation of the premolars of the normal series was complete, it was necessary to assist the eruption of 35 through orthodontic traction (Figure 2). Supernumerary teeth in close proximity to the root apices of teeth of the normal series (Case 2, Figure 4) also pose the danger of resorption of the teeth(10).

From a management point of view, multiple supernumerary teeth present a challenge to the surgeon, and their effects create unusual orthodontic problems. The clinician is, therefore, reminded to always take appropriate radiographs prior to orthodontic treatment to rule out, among other things, the presence of supernumerary teeth. It has been shown that premolars, both in the normal series and supernumeraries, may develop later than their usual anticipated times. This, therefore, means that radiographs should also be taken at some appropriate time during and after orthodontic treatment in children. Appropriate management of multiple supernumerary teeth requires careful planning, and practitioners encountering this phenomenon are advised to seek appropriate interdisciplinary opinion to enable formulation of the best possible treatment plan for the patient(11).

Determination of the positions of the teeth from clinical and radiographic examination is critical. Surgical technique and the decision as to whether to approach the said tooth /teeth transorally, buccally or lingually is based on the determined position /location of the tooth/teeth. For example, in our experience, majority of the supernumerary teeth occurring in the mandible were in the premolar region and lay lingually. Hence, surgical approach comprised elevation of the lingual mucoperiosteal flap

and exposure of the supernumeraries via the lingual cortex. Excessive extraction force was avoided, and sectioning of the teeth surgically helped to minimise damage to the adjacent teeth. It is of utmost importance that all the associated dental follicles should be removed to avoid possible sequelae of degeneration of the latter into cysts or ameloblastoma(12).

Active orthodontic movement of the teeth adjacent to the surgical site should commence at about 2-3 months post-surgery. This guidance is based on the expected time taken for normal bone to heal sufficiently. If radiographic indications at this point suggest that bone healing has not occurred as expected, orthodontic movement should be differed. It is recommended that in order to give a general appraisal of the bone and the dentition, relevant radiographs be taken periodically in these patients. A final radiographic appraisal is recommended after about five years.

REFERENCES

1. Richardson A. The treatment of local irregularities. In: *Interceptive Orthodontics*. 3rd ed. British Dental Journal. London PP 54-57. 1995.
2. Primosh R.E. Anterior supernumerary teeth. Assessment and surgical intervention in children. *Paediatric Dent. J.* 1981; **3**:204-215.
3. Gardiner J.H., Leighton B.C., Luffingham J.K. and Valiathan A. Aetiology of malocclusion. In: *Orthodontics for Dental Students*. 4th ed. Oxford University Press. New Delhi, India. PP 83-85, 1998.
4. Yusof W.Z. Non-syndrome multiple supernumerary teeth. Literature review. *J. Can. Dent. Assoc.* 1990; **56**: 147-149.
5. Ruhlmann D.C. and Neely A.R. Multiple impacted and erupted supernumerary teeth. *Oral Surg* 1964; **17**: 99-203.
6. Bodin I., Julin P. and Thomson M. Frequency and distribution of supernumerary teeth among 21,609 patients. *Dentomaxillofac Radiol.* 1978; **7**:15-17
7. Lesan W.R. and Wandenya R. Double supernumerary impacted premolar teeth. *East Afr. Med. J.* 1989; **66**:489-490.
8. Ng'ang'a P.M. and Ng'ang'a R.N. Supernumerary teeth in a population of 8-15 year-old orthodontic patients in Kenya. *Afr. J. Oral Hlth. Sci.* 2000; **1**:16-18.
9. Burch J., Ngan P. and Hackman A. Diagnosis and treatment planning for erupted premolars. *Paediatr. Dent.* 1994; **16**:89-95.
10. Zvolanek J.W. and Spotts T.M. Supernumerary mandibular premolars: Report of cases. *J. Am. Dent. Assoc.* 1985; **110**:721-723.
11. Becker A., Bimstein E. and Shteyer A. Interdisciplinary treatment of multiple unerupted supernumerary teeth. Report of a case. *Am. J. Orthod.* 1982; **81**:417-422.
12. Chindia M.L., Guthua S.W. and Mwaniki D.L. Ameloblastoma after surgical removal of an impacted mandibular molar. *Int. J. Oral Maxillofac. Surg.* 1991; **20**: 73-74.