

## Hand Tumours in Lagos, Nigeria: A Clinicopathologic Study

B.O. Mofikoya<sup>1</sup>, C.C. Anunobi<sup>2</sup>, A.O. Ugburo<sup>1</sup>.

<sup>1</sup> Burns, Plastic Surgery and Hand Rehabilitation unit, Department, College of Medicine, University of Lagos, PMB 12003, Lagos Nigeria.

<sup>2</sup>Department of Anatomic and Molecular Pathology, College of Medicine University of Lagos PMB 12003, Lagos Nigeria

**Correspondence to:** Dr. B.O. Mofikoya, Email: bmofikoya@yahoo.com

**Background:** Hand tumours occur infrequently and are commonly benign, however when malignant they could be life threatening. This study was aimed at determining the prevalence, demographics, the clinical presentations and treatment outcome of hand tumours among patients attending the hand service of the Lagos University Teaching Hospital.

**Methods:** We studied the clinical and pathological records of a 124 consecutive hand tumours that presented at hand clinic of the Lagos University Teaching Hospital (LUTH) between June 2003 and June 2013.

**Results:** A total of 124 patients were seen of which 98 had excision biopsies. The male to female sex ratio was 1: 1.3. The mean age at presentation was 32.7 years  $sd \pm 8.44$  years. An overwhelming majority (94.9%) had their procedures done under local/regional anaesthesia. Two patients died and three of the tumours recurred during the follow up period. The commonest histopathological diagnoses included ganglion cyst, giant cell tumor of the tendon sheath and pyogenic granuloma constituting 23.8%, 15.7% and 6.7% of the cases seen respectively.

**Conclusion:** Hand tumours in Lagos tend to affect young adults with a slight female preponderance. Majority of the tumours were benign. Primary hand malignancy was uncommon and mortality was low. Nearly all (97%) of the surgically treated patients returned to their premorbid occupation.

**Key words:** Hand tumours, biopsy, soft tissue.

### Introduction

Hand tumours are commonly encountered entities by many clinicians. Some have estimated that they make up about 16% of all soft tissue tumours in the body and 6% of all bony tumours<sup>1,2</sup>. Majority of the tumours in the hand are benign. In our setting majority seek medical advice on account of aesthetic concerns, though when large, functional considerations become significant. The initial behaviour of many malignant lesions may be similar to that of a benign one and when missed consequences may be fatal. All tissues that make up the hand can be involved in the neoplastic process and occasionally diagnostic and therapeutic approach to certain lesions require unique considerations. In spite of their frequency there are relatively few reports concerning tumours of the hand in literature particularly from Africa. In this report we review our series of hand tumours seen in our centre highlighting the demographics of the lesions, discussions of the pathologies seen as well as treatment outcome.

### Patients and Methods

A comprehensive review of the clinical and anatomic pathology records of all patients seen at the Hand rehabilitation clinic of the Lagos University Teaching Hospital Idi Araba, Lagos between January 2002 and December 2012 was done. All patients who presented with tumours of the hand were included in the study. Patients basic biodata such as name, age, sex, site of lesion, duration of symptoms were noted. All patients had baseline Full blood counts as well as Radiological evaluation of the area. A pre operative incisional biopsy was done where required.

All patients had enbloc excision of the lesion carried out under digital, intravenous regional or general anaesthesia as required. All specimens were evaluated by standard histopathological techniques. Few

patients required adjuvant chemoradiation. All patients were followed up for 12 months. The results are presented.

## Results

One hundred and twenty four patients were seen at the Clinic over the study period with 50 males and 64 females (M:F, 1:1.3). The age ranged between 5 to 80 years with a mean of 32.7 years  $sd \pm 8.44$  years. There were 66 and 58 right and left handed lesions respectively. Ninety eight patients had surgical excision biopsy of their lesions. Ten of the cases were malignant. Eight of the patients had no definitive histopathological diagnosis and could not afford immunohistochemical analysis for further evaluation. Three patients had a spontaneous resolution of their lumps (Two patients with diagnoses of dorsal wrist ganglia and one with pyogenic granuloma).

All procedures except five were carried out under digital or intravenous regional block. Three patients (two with fibrosarcoma and one with epitheloid sarcoma) developed recurrence during the study, two of which necessitated a below elbow amputation. Two patients died of pulmonary metastases (one recurrent fibrosarcoma and one epitheloid sarcoma). All patients with benign tumours returned to their premorbid occupation. In the malignant group a patient with a diagnosis of neurofibrosarcoma who had a radial hemi-amputation in his dominant hand had to change jobs.

**Table 1.** Distribution of the Histopathological Diagnoses

Histopathological diagnosis	Number	Percentage
Ganglion cyst	29	23.8
Giant cell tumour of tendon sheath	19	15.3
Pyogenic Granuloma	12	9.7
Sarcoma	8	6.4
Glomus	9	7.3
Neurofibroma	3	2.4
Lipoma	3	2.4
Enchondroma	3	2.4
Dermatofibroma	2	1.6
Squamous cell carcinoma	2	1.6
No pathological diagnosis	8	6.4
Not operated	26	18.5
<b>Total</b>	<b>124</b>	<b>100</b>

## Discussion

The clinical importance of hand tumours is underscored by the wide varieties of pathologies that can present in this appendage. Many series estimate that they make up about 15% of all soft tissue tumors<sup>1</sup>. In our work tumours involving the hand make up 13.9% of all hand cases seen. The ten malignant ones made up 8% of all the hand tumours seen.

### *Ganglion cysts*

These represent the most frequent of all hand tumours in all reported studies<sup>3</sup>. This was further confirmed by our study where the 29 ganglia cysts seen constituted 35% of the cases operated. They tend to be benign, can be painful at extremes of motion and have a female preponderance<sup>4</sup> which is similar to our series that showed male: female ratio of 1:1.3. Of all the lesions seen in our study, four (19.3%) were volar while the remaining were dorsal which is in keeping with other reports<sup>3</sup>. They may be dorsal, wrist and distal metaphalangeal joint or volar (retinacular and metacarpophalangeal joint). Though their exact aetiology is unknown, numerous theories have been put forward. At present most

workers believe they represent cysts from the modified synovial or mesenchymal cells at the synovial – capsular interface in response to repetitive minor regional trauma<sup>3</sup>.

The common dorsal wrist ganglion has been shown to have an attachment to the scapholunate ligament in nearly all cases<sup>5</sup>. Microscopically the lesion usually consists of single or multiloculated cysts with their wall made of sheets of collagen fibres and completely devoid of synovial or epithelial lining, the fluid contained is clear jelly like and contains high levels of mucopolysaccharides<sup>6</sup>. Though there are continuing reports of non operative methods of treating the Ganglion in the hand, many of these experiences have been difficult to reproduce and recurrence rates have remained disappointingly high<sup>7</sup>. Enbloc excision in a bloodless field with meticulous dissection of the pedicle along with a cuff of dorsal wrist capsule is currently recommended by most workers<sup>7,8</sup>. In our series all operated patients were females. Three patients who opted for non operative treatment (aspiration and sclerosant injection) had an unsatisfactory outcome.

### *Giant cell tumour of the tendon sheath*

This was the second commonest tumour seen in our series and similar to what has been reported by other workers<sup>9,10</sup>. Its other synonyms are pigmented villonodular tenosynovitis, fibrous histiocytoma of the synovium, tenosynovial giant cell tumour, localized nodular synovitis, benign synovioma and fibrous xanthoma of the synovium. The recurrence rates have been shown to be as high as 45% in some series<sup>11,12</sup>. In our series all tumours occurred around the fingers (figure 1). The tumour is typically yellowish, well circumscribed, lobulated exophytic masses attached to the tendon sheath (figure 2). Some workers have classified it based on the degree of encapsulation, extent of growth (palmar, dorsal or circumferential) as well as the involvement of neurovascular structures<sup>13</sup>. Histologically, the lesion is said to be characterized by synovial cell hyperplasia, multinucleated giant cells, large amounts of histiocytes, haemosiderin laden macrophages as well as numerous collagen strands (figure 3). This peculiar lesion has been classified as intra articular localized, intra articular diffused type, extra articular diffuse and the rare malignant variety<sup>14</sup>. Though bony compression may be noted no frank erosion is usually observed.

Histological diagnosis of giant cell tumour is rarely difficult but the evaluation of certain atypical features can be problematic. The presence of mitotic features occasionally leads to a mistaken diagnosis of a malignant lesion. Although it may indicate an actively growing lesion that is likely to recur, but there is no evidence to suggest that such lesions metastasise<sup>15</sup>. The diagnosis is usually suspected clinically, Ultrasound usually demonstrates a solid homogenous hypoechoic mass and can provide information about surrounding structures<sup>16</sup>. Magnetic resonance imaging has been shown to be the most useful preoperative investigative tool as it depicts both the internal architecture of the tumour, its vascularity, tumour extensions as well as location of digital vessels in circumferential lesions<sup>17</sup>. We have not found these investigations cost effective for most patients in our practice. Standard complete surgical excision was done in all our patients. We do not administer post operative radiotherapy as reported by some workers<sup>18</sup>. All our patients were followed up for a period of 3 to 5 years with no recurrence in eighteen cases.

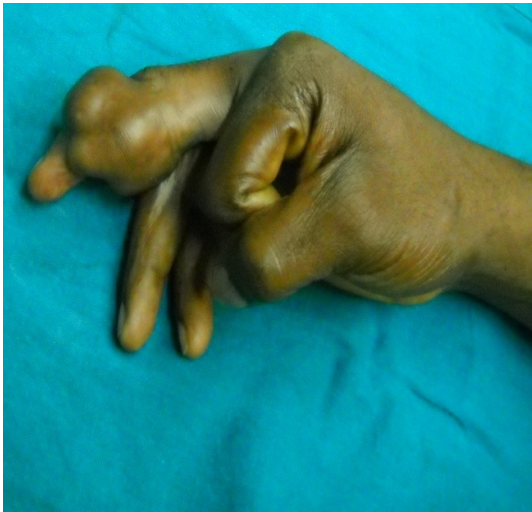### *Pyogenic Granuloma*

This was the third commonest tumour in this study accounting for 9.7%. The most common areas of involvement by this tumour are the head and neck, followed by the extremities. Since bleeding is a very common feature, the patient generally covers it with an adhesive. Therefore, some authors have called this “the band-aid sign”<sup>19</sup>. This is also known as lobular capillary haemangioma. The basic lesion is a lobular haemangioma set in a fibromyxoid matrix. Each lobule of the haemangioma is made up of a larger vessel with muscular wall and surrounded by smaller capillaries. Pyogenic granuloma is a misnomer, as it is neither infectious nor granulomatous in origin. This common tumour has no exact aetiology but commonly associated with a recent history of trauma and infection. It is said to arise due to an imbalance between positive and negative angiogenic stimuli following injury<sup>20</sup>. Others believe it represents an abnormal reaction to a foreign body. It bleeds easily following minor trauma. There is a

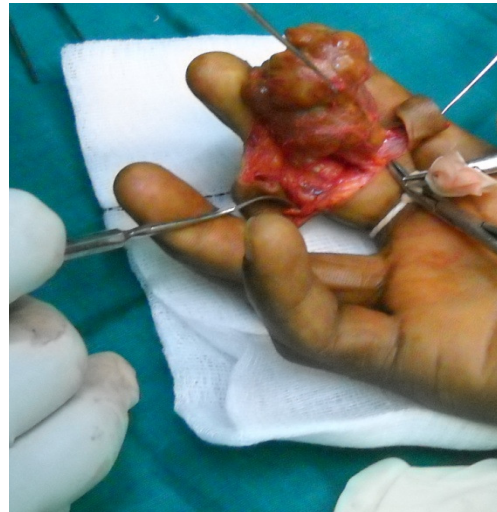pregnancy associated variety seen in 2% of women occurring commonly in the oral cavity<sup>21</sup>. Though some<sup>22</sup> have recommended curettage and silver nitrate application to the base we have preferred a wide excision and had one recurrence among our 12 cases. Other treatment modalities described, include curettage, electrodesiccation, pulse dye laser, cryotherapy, and topical imiquimod 5% cream<sup>23</sup>

### Sarcoma

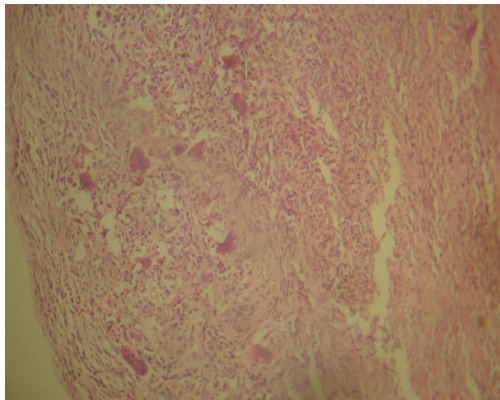
Soft tissue sarcoma involving the hand are uncommon and make up 8% of the hand tumours surgically treated<sup>24</sup>. The eight patients seen in this study included 5 with fibrosarcoma, one each with epithelioid sarcoma, glomangiosarcoma and a neurofibrosarcoma. The absence of sarcomas of bony origin from our series may reflect the general rarity of primary bone sarcomas in the hand. There is a wide range of subtypes with different disease pattern, recurrence, metastasis and response to treatment. They commonly present as painless masses.



**Figure 1.** A typical Giant cell tumour of the tendon sheath.



**Figure 2.** Intraoperative view of a yellowish lobulated lesion.



**Figure 3.** Giant cell tumour cell tendon Sheath (H & E, X20). A circumscribed moderately cellular tumour composed of sheets of round, polygonal and multinucleated giant cells

In our series three occurred in the web spaces and the rest arose from the hand. No patient with bony erosion was seen and all had an incisional biopsy. Only four patients had definitive surgery (two had wide excision and skin grafting, one fifth ray amputation for epithelioid sarcoma and a radial hemi-amputation for sarcomatous transformation of a neurofibroma). The predominance of fibrosarcoma in this study is at variance with some workers<sup>24,25</sup> who reported epithelioid sarcoma as the commonest soft tissue sarcoma occurring in the hand with others including synovial sarcoma rhabdomyosarcoma, malignant fibrous histiocytoma, and leiomyosarcoma. While literature has proposed that deep



location, high grade and a diameter of >5cm are associated with distant metastasis, studies on sarcomas of the hand have revealed a higher prevalence of local recurrence and metastatic disease compared to other sites<sup>26</sup>. Only four of our eight patients consented to any form of ablative surgery. While studies have shown that margin negative resections combined with radiation therapy reduces the recurrence rate of high grade soft tissue sarcomas of the hand resulting in comparable survival rates to amputations<sup>27-29</sup>. Our 25% mortality rate at one year in eight patients is inadequate to draw valid conclusions.

### **Glomus tumours**

Glomus tumours are rare benign tumours that occur in the hand. They make up 1 to 5% of all hand tumours. It arises from a glomus body which is from a neuromyoarterial apparatus described by Masson in 1924<sup>30</sup>. The tumour is yellowish in the African and consists of afferent arteriole and vascular channels lined by normal endothelial cells surrounded by solid proliferation of round and cuboidal cells. It accounted for 9.2% of all surgically treated patients in our series. One lesion was periungual, the rest occurred in various parts of the digits. Clinically distinguished by the Love and Hildreth's tests<sup>31,32</sup>. They were all completely excised under digital block, with complete resolution of the symptoms and no recurrence at two years.

### **Neurofibroma**

Neurofibromas along with schwannomas make up the commonest hand tumours of neural origin seen. Neurofibromas may assume one of three growth patterns: localized, diffuse, or plexiform. Diffuse and plexiform forms have a close association with neurofibromatosis 1 (NF 1). The localized variety is seen most commonly as superficial solitary tumour. All lesions seen were solitary lesions. Histologically tend to show a more disordered cellular pathology but in most characteristic form the neurofibroma contains interlacing bundles of elongated cells with wavy dark staining nuclei. There may be a solitary variety of nerve sheath myxoma called paccinian neurofibroma. While complete excision in our patients was curative, neurofibromas associated with Von Recklinghausen's disease have a distinct higher likelihood of malignancy. The remaining lesions such as dermatofibroma, enchondroma and lipoma each made up less than 5 % of all the tumours seen.

This study demonstrated a wide variety of lesions presenting as tumours of the hand. Hand tumours in Lagos tend to affect young adults with a slight female preponderance. Majority of the tumours were benign and nearly all patients returned to work after treatment.

### **References**

1. Garcia J, Bianchi S. Diagnostic imaging of tumors of the hand and wrist. *Eur Radiol* 2001; 11: 1470–1482.
2. Kransdorf MJ, Meis JM. From the archives of the AFIP: extraskelatal osseous and cartilaginous tumors of the extremities. *Radiographics* 1993; 13: 853–884.
3. Angelides AC. Ganglions of the hand and wrist. In: Green DP, ed. *Operative hand surgery*. 3rd ed. New York: Churchill Livingstone, 1993:2171-2183.
4. Barnes WE, Larson RD, Posch JL. Review of ganglia of the hand and wrist with analysis of surgical treatment. *Plast Reconstr Surg* 1964; 34: 570-578.
5. Angelides AC, Wallace PF. The dorsal ganglion of the wrist: its pathogenesis, gross and microscopic anatomy, and surgical treatment. *J Hand Surg* 1976;1:228-235.
6. Soren A. Pathogenesis and treatment of ganglion. *Clin Orthop* 1966;48:173-179.
7. Wright TW, Cooney WP, Ilstrup DM. Anterior wrist ganglion. *J Hand Surg [Am]* 1994; 19A:954-958.
8. Clay NR, Clement DA. The treatment of dorsal wrist ganglia by radical excision. *J Hand Surg [Br]* 1988;13B: 187-191.
9. Monaghan H, Salter DM, Al-Nafussi A. Giant cell tumor of tendon sheath (localised nodular tenosynovitis): clinicopathological features of 71 cases. *J Clin Path* 2001; 54:404-7.

10. Martin RC 2nd, Osborne DL, Edwards MJ, Wrightson W, McMasters KM. Giant cell tumor of tendon sheath, tenosynovial giant cell tumor, and pigmented villonodular synovitis: defining the presentation, surgical therapy and recurrence. *Oncol Rep* 2000; 7:413-419.
11. Reilly KE, Stern PJ, Dale JA. Recurrent giant cell tumors of the tendon sheath. *J Hand Surg [Am]* 1999; 24:1298-302.
12. Uriburu IJ, Levy VD. Intraosseous growth of giant cell tumors of the tendon sheath (localized nodular tenosynovitis) of the digits: report of 15 cases. *J Hand Surg [Am]* 1998; 23:732-736.
13. Monahgm H, Salter DM , Al-Nafussi A. Giant cell tumour of tendon sheath (localized nodular tenosynovitis): clinicopathological features of 71 cases *J Clin Pathol* 2001;54:404–407.
14. Lucas DR. Tenosynovial Giant Cell Tumor Case Report and Review *Lab Med.* 2012; 136:901–906;
15. Enzinger and Weiss's Soft Tissue Tumours. Eds Sharon W. Weiss and John R. Goldlum. 4th Edition, 2001. Mosby. 1038-1047
16. Middleton WD , Patel V, Teefey SA, Boyer M. Giant Cell Tumors of the Tendon Sheath: Analysis of Sonographic. *American Journal of Roentgenology.* 2004;183: 337-339
17. Beuckeleer L, De Schepper A , Belder F, Von Goethem J, et al. Magnetic resonance imaging of Localized Giant cell tumor of the tendon sheath(MRI of localized GCTTS). *European Radiology* (7). 1997:198-201
18. Prakash P. Kotwal, Vikas Gupta, Rajesh Malhotra. Giant-cell tumour of the tendon sheath Is radiotherapy indicated to prevent recurrence ? *J Bone Joint Surg [Br]* 2000; 82-B: 571-3.
19. Patrice SJ, Wiss K, Mulliken JB. Pyogenic granu-loma (lobular capillary hemangioma): A clinico-pathological study of 178 cases. *Pediatr Dermatol.* 1991; 8:267–276.
20. Catherine Godfraind, Monica L Calicchio and Harry Kozakewich Pyogenic granuloma, an impaired wound healing process, linked to vascular growth driven by FLT4 and the nitric oxide pathway *Modern Pathology* 2013 26, 247-255
21. Sills ES, Zegarelli DJ, Hoschander MM, Strider WE. Clinical diagnosis and management of hormonally responsive oral pregnancy tumor (pyogenic granuloma). *J Reprod Med.* Jul 1996; 41(7):467-470.
22. Quitkin HM, Rosenwasser MP, Strauch RJ. The efficacy of silver nitrate cauterization for pyogenic granuloma of the hand. *J Hand Surg Am.* May 2003; 28(3):435-438.
23. Sud AR, Tan ST. Pyogenic granuloma–treatment by shave-excision and/or pulsed-dye laser. *J Plast Reconstr Aesthet Surg.* 2010;63: 1364–1368.
24. Bryan RS, Soule EH, Dobyns JH, et al. Primary epithelioid sarcoma of the hand and forearm. *J Bone Joint Surg* 1974;56A:458–465.
25. SG Talbot, BJ Mehrara, JJ Disa, AK Wong, A Pusic, PG Cordeiro, EA Athanasian Soft Tissue Reconstruction of the Hand Following Sarcoma Resection *Plast Reconstr Surg* 121: 534-543, 2008
26. Brien EW, Terek RM, Geer RJ, et al. Treatment of soft-tissue sarcomas of the hand. *J Bone Joint Surg [Am]* 1995;77:564–571.
27. Talbert ML, Zagars GK, Sherman NE, et al. Conservative surgery and radiation therapy for soft tissue sarcomas of the wrist, hand, ankle, and foot. *Cancer* 1990; 66:2482-2491
28. McPhee M, McGrath BE, Zhang P, et al. Soft tissue sarcoma of the hand. *J Hand Surg [Am]* 1999; 24:1001–1007.
29. Bray PW, Bell RS, Bowen CV, et al. Limb salvage surgery and adjuvant radiotherapy for soft tissue sarcomas of the forearm and hand. *J Hand Surg [Am]* 1997; 22:495–503.
30. Sorene ED, Goodwin DR. Magnetic resonance imaging of a tiny glomus tumour of the fingertip: a case report. *Scand J Plast Reconstr Surg Hand Surg.* 2001; 35:429–431.
31. Dahlin LB, Besjakov J, Veress B. A glomus tumour: classic signs without magnetic resonance imaging finding. *Scand J Plast Reconstr Surg Hand Surg.* 2005; 39:123–125.
32. Bhaskaranand K, Navadgi BC. Glomus tumour of the hand. *J Hand Surg* 2002;27B:229 – 231.