



Deep palmar space lipoma: Case report and review of the literature

O. A. Olawoye^{1,2}, O.N. Enemo³, A.O. Iyun², E.E. Akang⁴.

¹Department of Surgery, College of Medicine University of Ibadan;

²Department of Plastic Surgery, University College Hospital, Ibadan;

³Department of Surgery, University College Hospital, Ibadan;

⁴Department of Pathology, University of Ibadan and University College Hospital, Ibadan.

Correspondence to: Dr O. A. Olawoye -Email: yinkaolawoye@yahoo.co.uk

Background: *Although lipoma is the commonest benign tumour in the body, it is rarely found in the hand. Subcutaneous lipomas have characteristic distinguishing features which place them among the most easily diagnosed cutaneous lesions. However, the diagnosis of deep lipomas of the hand are often missed because of the rarity of the condition and the inelastic aponeurosis of the hand which obscures the usually commonly distinguishing features of lipoma.*

Case presentation: *We present the case of a 55 year old right hand dominant woman who had an 18 month history of painless swelling on the right hand. The physical examination and plain radiograph were uncharacteristic and it was difficult making a definitive diagnosis. With a presumptive assessment of right palmar soft tissue swelling, an excision biopsy was planned which revealed a lipomatous mass diagnosed as right palmar lipoma on histology.*

Conclusion: *The rarity of lipoma of the hand makes the clinical preoperative diagnosis challenging. A high index of suspicion along with the use of appropriate imaging techniques such as magnetic resonance imaging becomes critical in the pre-operative diagnosis and management of deep lipoma of the hand.*

Keywords: Palmar lipoma, lipoma of the hand, lipoma

Introduction

Lipomas are the commonest benign tumours found in humans. They have been reported to be the single most common soft tissue tumour.¹ Though they have been reported in virtually every part of the body, the deep palmar space of the hand remains a less likely location, posing significant diagnostic challenge on physical examination. Lipomas of the hand are usually asymptomatic and patients usually present only when there are cosmetic concerns or rarely when there are pressure effects and they become symptomatic with paraesthesia, muscle atrophy and paralysis. A high index of suspicion is helpful to make a diagnosis of deep palmar lipoma.

Case Report

The patient was a 55 year old right hand dominant trader who presented with 18 month history of progressive swelling on the ulnar aspect of the palmar surface of her right hand. She had no antecedent history of trauma. She is of the Yoruba descent and there was no family history. She noticed some limitation of extension of the ring and little finger about 6 months after the onset of the lesion, she however did not have pain, itching or loss of sensation over the lesion. She denied any history of diabetes mellitus or any other medical co morbidity.

On examination, a prominent fluctuant swelling was found on the hypothenar eminence of the right palm (Figure 1). The lesion had no features of inflammation and there was no sensory

deficit over the lesion. There was spontaneous capillary refill of all the fingers of the right hand. There was some flexion deformity of the proximal interphalangeal joints of the ring and little fingers. The contralateral hand was essentially normal.

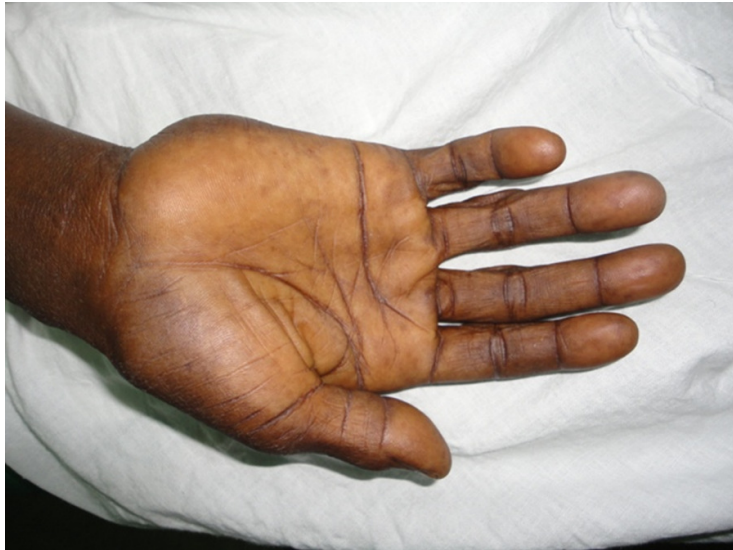

Figure 1

Radiographic findings

The mass was apparent on plain radiograph as a hypo dense circumscribed lesion at the base of the little finger (Figure 2). A diagnosis of right palmar soft tissue tumour was made.

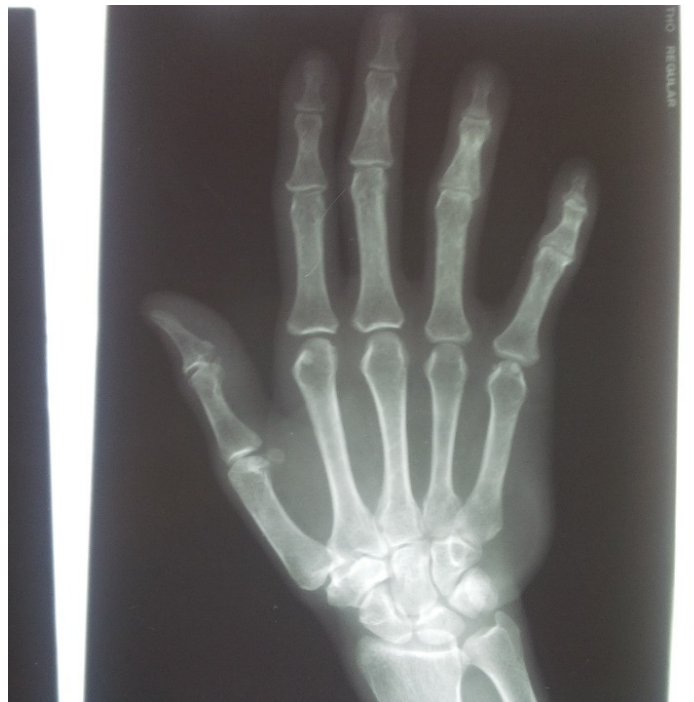

Figure 2 . Plain radiograph of the right hand

Surgical management

Her surgery was performed under wrist block with 0.5% lignocaine solution. A longitudinal incision was made and the intraoperative finding was that of a circumscribed yellowish mass located deep to the hypothenar muscles with attachment to the metacarpophalangeal joint of the little finger by a fibrous band. Marginal excision of the tumour was done. The tumour measured 4 cm by 3 cm and weighed 9 grams (Figure 3). Haemostasis was secured and the wound cavity was irrigated with saline and closed in layers. She was managed on outpatient basis.

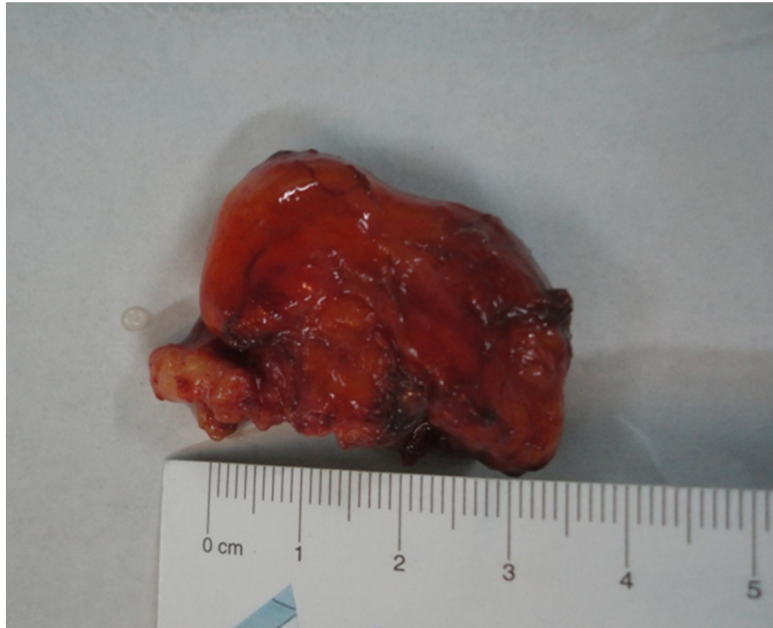

Figure 3. Photograph of gross specimen showing a circumscribed lobulated yellow mass

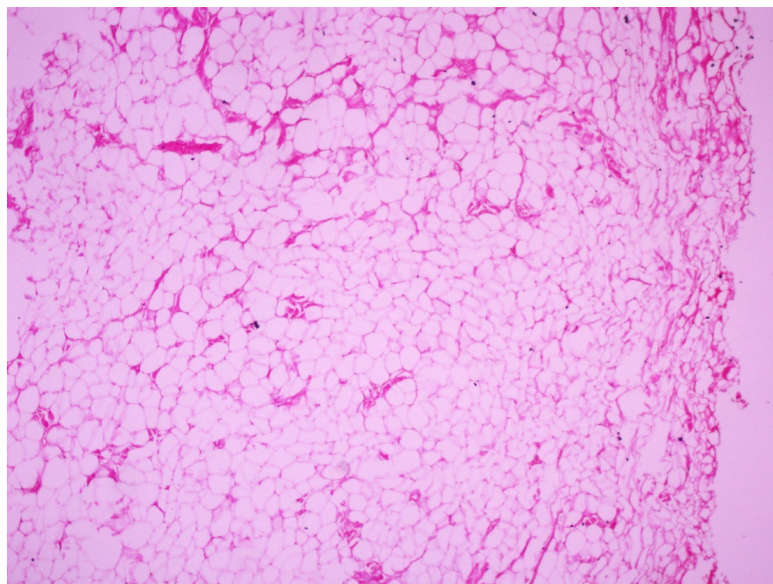


Figure 4- Photomicrograph of specimen showing benign neoplasm composed of mature adipocytes

The histopathological analysis of the resected tumour revealed a benign mesenchymal neoplasm composed of sheets of mature adipocytes (Figure 4).

Discussion

Unlike subcutaneous lipomas that have characteristic pathognomonic clinical features, deep lipomas of the hand are rarely diagnosed clinically before surgery. Some of the reasons for this include the presence of the unyielding aponeurosis in the hand and the rarity of the condition. In one of the early reports by Straus² in which thirty four cases of deep palmar lipomas were reviewed, it was found that the diagnosis of deep lipoma of the hand was made correctly in only one patient. Our patient similarly presented with an eighteen month history of a progressive mass in the ulnar aspect of her right hand with no other characteristic feature of a lipoma. This was the only record of palmar lipoma managed in our unit over a ten year period.

The deep lipomas of the hand have been categorized into two groups based on their relationship to the tendon sheath. Those whose origin and expansion occur within the tendon sheaths have been referred to as endovaginal³. They constitute the largest group and they have been further divided into lipoma simplex symmetricum and lipoma arborescens. The occurrence of lipoma arborescens within a tendon sheath was first reported by Billroth². The second group is the epivaginal or subaponeurotic lipoma. Epivaginal lipomas are attached to the tendon sheath rather than the subaponeurotic tissue.² Both endovaginal and epivaginal lipomas have been found in the fingers, palm and the wrist while the endovaginal lipomas have been described in the hand, the dorsum of the wrist and the foot.^{4,5} The palmar lipoma in our patient was epivaginal as it was attached to the tendon sheath.

Another classification of palmar lipomas into superficial and deep palmar lipomas was proposed by Mason⁶ in 1937. Superficial palmar lipomas have been found to be more common⁷. The rarity of deep palmar lipoma is buttressed with the scarcity of reported cases. In a case series of four hundred and seventy six lipomas of the upper limb by Barrile⁸, only one palmar lipoma was found. Similarly some other authors have highlighted the rarity of the condition in their reports^{9 - 13}. Most lipomas of the hand begin as painless swellings and remain quiescent for a variable period of time before the onset of a progressive growth phase. Many patients seek medical attention when the size of the lesion attains such a proportion as to give them cosmetic concerns. Others present as a result of compressive neuropathy, grasping difficulties, decrease in digital flexion or deviation of the fingers^{7, 12 - 15}.

Deep palmar lipoma are usually in close approximation to vital structures such as the neurovascular bundle and tendons in the hand thus extreme caution is required in their dissection to avoid iatrogenic injury to these structures. The pressure effect of relatively bigger lesions may also lead to distortion of the anatomical landmark of some of these vital structures. Many of the palmar lipomas have been reported to be peripherally located as was found in our patient. (Figure 1) The peripheral location of most of these tumours is said to be due to the centrally located thick deep palmar fascia¹³. Deep palmar lipomas can be deceptively large and extensive¹⁶ and magnetic resonance imaging has been found useful for its preoperative diagnosis and surgical care^{16,17,18}.



Conclusion

Though lipomas are the commonest soft tissue tumour in the body, they are rarely found in the hand, thus presenting a diagnostic dilemma and high rate of misdiagnosis. A high clinical index of suspicion coupled with the use of appropriate imaging modalities should assist with prompt diagnosis and surgical care.

Acknowledgement

The authors thank Dr Maina for his involvement in the management of the patient.

References

1. Pagonis T., Givissis P., Christodoulou A. Complications arising from a misdiagnosed giant lipoma of the hand and palm; a case report. *J MedCaseRep* 2011; 5(1):552. <http://jmedicalcasereports.com/content/5/1/552> accessed on the 13th October, 2013
2. Straus F.H. Deep lipomas of the hand. *Ann Surg.* 1931; 94(2):269-73.
3. Gross F.C., Rohmer J., Vautrin A., André P. *Nouveaux éléments de pathologie chirurgicale générale.* Paris, Baillière, 1898: pp. 392.
4. Muller P. Palmar lipoma of finger. *Bull Men. Soc. Chir. Paris* 1928; 20:390-2.
5. Martin A., Grenier J. A case of lipoma of a finger. *Paris Med.* 1922;12:303-4.
6. Mason M.C. Tumours of the hand. *Surg. Gynecol. Obstet.* 1937; 64:129-35.
7. Leffert R.D. Lipomas of the upper extremity. *J. Bone Joint Surg.* 1972; 54A:1262-6.
8. Barrile N.M. Gran lipoma subaponeurotico. *Presna Med. Argent.* 1958; 45:318-20.
9. Schmitz R.L., Kelly J.L. Lipoma of the hand. *Surgery* 1957; 42:696-700.
10. McEnery E.T., Schmitz R.L., Nelson P.A. Palmar lipoma; report of a case *AMA Arch. Surg.* 1959; 699-700.
11. Hueston J.T. Massive lipoma of the hand. *Aust. NZJ. Surg.* 1965;34:19-21.
12. Paarlberg D., Linscheid R.L., Soule E.H. Lipoma of the hand. *Mayo Clin. Proc.* 1972; 47:121-4.
13. Oster L.H., William F.B., Curtis M.S. Large lipomas in the deep palmar space. *J. Hand Surg.* 1989; 700-4.
14. Booher R.J. Lipoblastic tumours of the hands and feet: Review of literature and report of thirty-three cases. *J Bone Joint Surg.* 1965; 47A:727-40.
15. Brand M.G., Gelberman R.H. Lipoma of the flexor digitorum superficialis causing triggering at the carpal canal and median nerve compression. *J. Hand Surg.* 1988; 13A:342-4.
16. Jagannath KK, Ramachandra KB, Praveen B, Shridhar Chetna S. A giant lipoma in the hand – Report of a rare case. *Online J. Health Allied Sci.* 2006; 5. <http://www.ojhas.org/issue17/2006-1-6.htm>. Accessed on 19 November 2013.
17. Capelastegui A., Astigarraga E., Fernandez-Canton G., Saralegui I., Larena J.A., Merino A. Masses and pseudomasses of the hand and wrist: MR findings in 134 cases. *Skeletal Radiol.* 1999; 28:498-507.
18. Phalen G.S., Kendrick J.I., Rodriguez J.M. Lipomas of the upper extremity. A series of fifteen tumours in the hand and wrist and six tumours causing nerve compression. *Am. J Surg.* 1971; 121:298-306.