

## Management of Avascular Necrosis of Femoral Head (ANFH) in Sickle Cell Disease

**J.A.O. Mulimba**

Chairman Dept of Ortho. Surgery, University of Nairobi, P. O. Box 52507-00200 – Nairobi

Email: [josephatmulimba@yahoo.com](mailto:josephatmulimba@yahoo.com)

**Sickle cell disease manifests itself in various forms the worst of which is sickle cell crisis. Among tissues most affected is bone with avascular necrosis of the femoral head (ANFH) being the most chronic and debilitating. After various treatments failed, recourse was made to total hip replacement or arthroplasty (THA). Over a period of 10 years 1999 to 2009, 27 THAs in 25 patients were done, 13 male and 12 female. There was one resurfacing done elsewhere. There were 11 cemented and 16 uncemented. Age ranged between 16 and 38 years. All patients came late with Ficat grade 4. Peak age for operations was 16 – 20 years. Six patients died, no death surgery related. End result was improvement of Harris hip score to between 70 and 88 from 40 to 55. Very few complications were noted and the overall outcome rated as good. Further research is recommended to identify viable biological treatment modalities.**

### Introduction

Sickle cell disease is an autosomal recessive genetic disorder characterized by red blood cells changing their shape to a sickle shape when they are subjected to an environment of reduced oxygen tension. This sickling shape impairs their smooth flow through the blood vessels leading to blockage of blood vessels and thrombosis. The end result is necrosis of the areas affected by this blockage. As a result of this blockage a large number of manifestations are witnessed as symptoms and signs. These include almost every organ in the body. The more common features are those of anaemia i.e. malaise, tiredness on slight exertion, breathlessness headaches and light headedness, chest pains and fatigue in general. Other manifestations are crises; the sickle cell crisis. It affects bones, joints, lungs and abdomen. The crises are often acute but can also be chronic and debilitating. Very often these crises are accompanied with jaundice. Other problems include splenomegally or autosplenectomy, recurrent infections which may affect any organ such as spleen and liver, but lungs are the most affected, sometimes leading to pulmonary hypertension.

Growth may be retarded and very often there is bossing of the skull; recurrent strokes may lead to mental retardation. Not infrequently cholelithiasis becomes a problem. One interesting feature is priapism, children who present with this are in agony. Some sufferers present with vision problems due to affected retina. Ulcers in the legs are a common feature with hyper-pigmentation in the lower 3<sup>rd</sup> of the leg where these ulcers occur. They rarely occur before the age of 10 and can be chronic. In this communication the main concern is with osseous manifestations of sickle cell disease (SCD). They include dactylitis also referred to as hand and foot syndrome, bossing of the skull, avascular necrosis of the femoral head and osteomyelitis which often becomes chronic with salmonella infection being a special feature of this osteomyelitis.

In a recent publication, Mulimba<sup>1</sup> reported that 5% of Total Hip Arthroplasties (THA) were due to Avascular Necrosis of the Femoral Head (ANFH). At first management of ANFH was done by various methods previously described including osteotomy, core decompression and fusion. None of them gave satisfactory results. The reason being that most of the patients came late with ANFH grade 4<sup>2,3,4</sup>. Locally THA had become firmly established and improved. There were a number of reports on THA in younger patients mostly due to Still's disease, congenital hip dysplasia and traumatic ANFH<sup>5,6,7,8,9</sup>. So this was decided to be the sensible way to go. Sickle cell disease is prevalent in Kenya in malaria prone areas that is Coastal region and Shores of Lake Victoria.

The Objective of management was to give relief to the suffering caused by ANFH in patients who usually presented with late disease and assess the success or otherwise of this mode of management.

## Patients and Methods

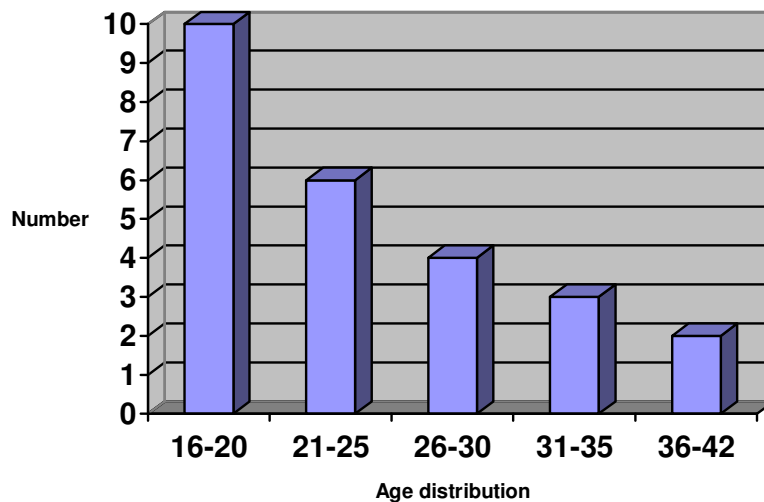
Patients who were mostly referred from other clinics or hospitals were assessed with history, examination and xrays. The degree of disability was ascertained. Since most were end stage disease all were scheduled for THA. After assessment and radiological diagnosis, they were admitted to hospital early. They were managed by a haematologist until declared fit; they were then anaesthetically assessed and date set for surgery. Haemoglobin levels lay between 8 and 10gm/dcl. Transfusion was done prior to surgery. Post operative management was multidisciplinary as was pre operative management. The first lot were all cemented and later uncemented. Post operative follow up included Harris Hip Score assessment.

## Results

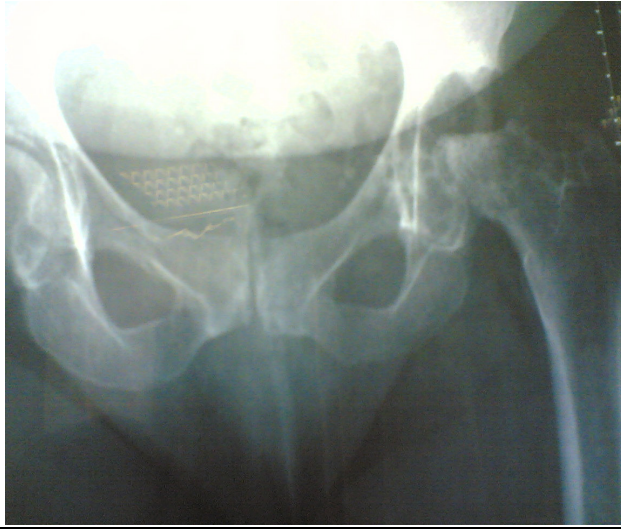The period of assessment was from January 1999 to December 2009. A total of 25 patients were operated on, 13 male and 12 female. In total, 28 hips were operated: 11 were cemented, 16 were uncemented and 1 had resurfacing which was done in Italy. Table 1 shows the age distribution. The patients' ages ranged between 16 and 38 years. The peak was in the 16-20 years age group (Figure 1).

**Table 1.** Age distribution

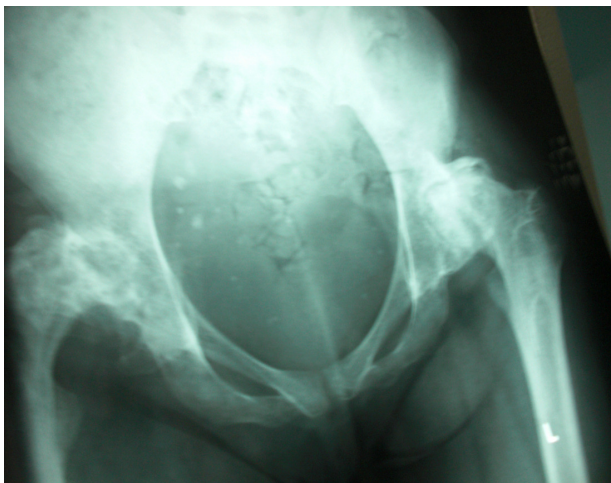
Age in Years	Number of patients
16 – 20	10
21 - 25	6
26 - 30	4
31 - 35	3
36 - 42	2
Total	25



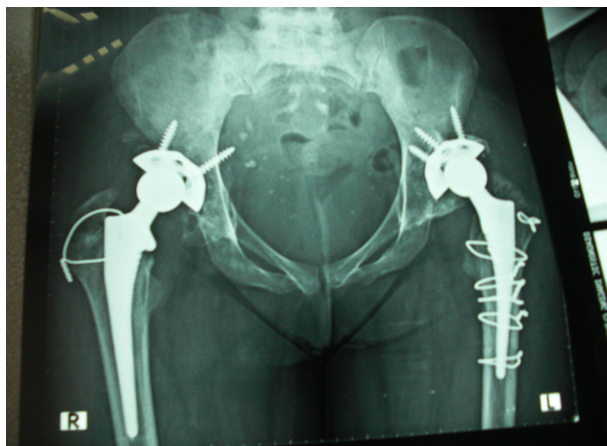**Figure 1.** Age distribution



**Figure 2.** Ficat Grade 4 Avascular Necrosis of Femoral Head in a Sickler



**Figure 3.** Bilateral Avascular Necrosis of Femoral Head



**Figure 4.** Bilateral total hip replacement in a sickler

### Outcome

All patients improved with Harris Hip score rising to between 70 and 88. Those eventually lost to follow up were 5 i.e. 4 plus the one from Italy. 6 died, deaths unrelated to surgery. 15 are alive and well. Superficial infection occurred in one patient and one patient had femoral fractures.

### Discussion

Avascular necrosis of the femoral head in sicklers is a common osseous manifestation. It is quite debilitating and requires robust management to alleviate the suffering. ANFH occurring in other situations, and found early has responded to head preserving procedures such as core decompression, osteotomy and implanting of cages. In our local situation the systemic nature of the disease and late referral of the patients<sup>1,2,3</sup> make conservative management unattractive alternative. The fact that these patients may suddenly die from their disease makes choice of replacement very difficult.

As shown in this review 25 patients were treated with total hip replacement with a total of 27 hips, two being bilateral. The male to female ration was 1:1. The age range was 16-38 years with a pick between 16 and 25 years. In fact as a single age, the majority were 19 years. The choice of whether to carry out cemented or uncemented arthroplasty was that in the beginning only the cemented prosthesis was available. Later the uncemented prosthesis was introduced into the Kenyan market. The cemented prosthesis is not the best for the young and all these patients being young, the uncemented was the best choice<sup>10</sup>. Unfortunately the uncemented prosthesis costs three times the cemented. In view of the fact that some of these patients die suddenly between the age of 20 and 30 years, is it justifiable to use such an expensive prosthesis? In this case 6 patients died suddenly none of them from surgery. The deaths were usually associated with sickle cell crisis, however, one died on the night following his wedding for yet undetermined reason. Since the care for sicklers has improved a great deal in recent years, some have been known to survive to middle ages, the option of uncemented prosthesis will be the most preferred<sup>11,12,13</sup>.

Without exception all patients improved following THA. After operation the Harris Hip Score ranged between 70 and 88 from 40 to 55. For patients who previously could not walk even a kilometer this was a remarkable improvement<sup>14,15</sup>. All were able to leave walking aids within three months.

There was only one patient done resurfacing in this group. The operation was done in Italy and was doing well, but unfortunately was lost to follow up. With scarce resources and that rather uncertain outcome of resurfacing<sup>16,17</sup> one is left wondering whether this is a reliable alternative in Africa. There is always fear that sickle cell disease being associated with a high incidence of osteomyelitis may not be safe with THA. In this study there was only one incidence of superficial wound infection. This responded well to treatment and healed without involving the prosthesis. It should also be borne in mind that most of our theatres cannot afford lamina air flow.

There were two cases of fractured femora. The first was a male patient who had bilateral cemented THA that walked home and came back within a month with pain and xrays showed crack fractures just distal to the prostheses. He was treated conservatively and healed with no further problems. The second is the case shown in Figure 4. This was a 38 year old female who had bilateral uncemented THA. The right femur just snapped when she was in bed the second post operative day. These patients always have a tinge of jaundice and it does not pay to wait for jaundice to clear before surgery is carried out. There wasn't a single case of hepatorenal syndrome. These patients have narrow femoral canals and reaming may be difficult, therefore, one should also keep smaller prostheses like those used in cases of hip dysplasia.

As already seen in this review the patients are young and THA may not be the best solution for their problem of ANFH in the long run. Research should be continued to find a method of conservative treatment to preserve the femoral head as has been done in other aetiologies of ANFH. The answer is likely to come from early detection of the problem and decompression of the head with implantation of cages containing bone or bone substitutes or injection of Bone Morphogenetic Proteins (BMPs) and/or stem cells<sup>19,20,21</sup>. Newer osteotomies being tried out for other causes of ANFH may also prove useful in early cases and could be tried out<sup>22</sup>. It is a pity that the region with this problem that is best suited to study it is also the region with the least ability to access stem cells. Stem cells and BMPs have been reported to be successful in restoring the head in certain circumstances<sup>22</sup>.

## References

1. Mulimba JAO: Total hip arthroplasty experience in a developing African country. *East Afr. Ortho. J.*, 2007, 2: 68 – 73.
2. Schmitt-Sody, Kirchoff C, Mayer W, Goeber M, Jansson V: Avascular necrosis of the femoral head: inter-and intraobserver variations of Ficat and ARCO classifications. *Int.Ortho.(SICOT)*, 2008: 283-287.
3. Ficat RP: Idiopathic bone necrosis of the femoral head. Early diagnosis and treatment. *J.Bone and J. Surg(Br)*, 1985, 67: 3-9.
4. Falez F, Favetti F, Casella F, Panegrossi G: Hip resurfacing: Why does it fail? Early results of our first 60 cases. *Int. Ortho.(SICOT)*, 2008; 32: 209-216.
5. Besette BJ, Frassier F, Tanzer M, Books CE: Total hip arthroplasty in patients younger than 21 years: a minimum, 10 years follow up. *Can J. of Surg.* 2003; 46:257-262.
6. Hartley WT, McAuley JP, Culpeper WJ, Engh OA Jr., Engh CA Sr: Osteonecrosis of the femoral head treated with cementless total hip arthroplasty. *J. Bone & J Surg.(A)*, 2000;82:1408-1413.
7. Kim YH, Oh SH, Kim JS, Koo KH: Contemporary total hip arthroplasty with and without cement in patients with osteonecrosis of the femoral head. *J. Bone & J. Surg.(A)*, 2003; 85: 675 -681.
8. Xuen Yony Qiu, Jing Yang, Bin Shan, Zongke Zhou, Hui, Zhang, Fuxing Pei: Mid term results using a cementless hip prosthesis in young Chinese patients: a five to seven-year follow-up study. *Int.Ortho.(SICOT)*2009; 33: 1507-1512.
9. Wangen H, Lereim P, Holm I, Gunderson R, Reikeras O: Hip arthroplasty in patients younger than 30 years. Excellent ten to 16-year follow up results with a HA-coated stem. *Int. Ortho.(SICOT)*,2008;32: 203- 208.
10. Wroblewski BM, Purbach,B, Siney PD, Fleming PA: Charnley low friction arthroplasty in teenage patients. *J.Bone and J. Surg.(B)*,2010, 92:486-488.
11. Ramaswamy R, Kosashvili Y, Cameron H: Total hip replacement in patients with multiple epiphysial dysplasia with a mean follow up of 15 years and survival analysis: *J. Bone and J.Surg.(B)*, 2010, 92:489- 495.
12. Kennedy DM, Hanna SE, Stratford DW, Wessel J, Gollish JD: Prospective function and gender predict pattern of functional recovery after total hip and knee arthroplasty. *J. Arthroplasty*, 2006, 21(4): 559-566.
13. Kim YH, Choi Y, Kim JS: Cementless total hip arthroplasty with ceramic-on-ceramic bearing in patients younger than 45 years with femoral head necrosis. *Int.Ortho.(SICOT)*, 2010; 34: 1123-1127.
14. Ethgen O, Bruyere O, Richy F, Dardennes C, Reginster JY: Health-related quality of life in total hip and total knee arthroplasty. A qualitative and systematic review of the literature. *J. Bone & J Surg.(A)*,2004, 86(5): 963-974.
15. Nercessian OA, Wu WH, Sarkissian H: Clinical and radiographic results of cementless AML total hip arthroplasty in young patients. *J. Arthroplasty*: 2001; 16: 312-316.
16. Yoon TR, Song EK, Rowe SM, Park CH: Failure after cone decompression in osteonecrosis of the femoral head. *Int. Ortho.(SICOT)*, 2001, 24:316-318.

17. Glyn-Jones S, Pandit H, Kwon YM, Doll H, Gill HS, Murray DW: Risk factors for inflammatory pseudotumour formation following hip resurfacing. *J. Bone and J. Surg.(B)*, 2009, 91: 1566 -1574.
18. Van Der Wal BCH, Vischjager M, Grinum B, Heyligers K, Tonino AJ: Periprosthetic fractures around cementless hydroxyapatite – coated femoral stems. *Int. Ortho.(SICOT)*, 2005, 29:235-240.
19. Bishop GB, Einhorn TA: Current and future clinical applications of bone morphogenetic proteins in orthopaedic trauma surgery. *Int. Ortho.(SICOT)*, 2007, 31:721-727.
20. Marko P, Slobodan V: Biological aspects of bone, cartilage and tendon regeneration. *Int. Ortho.(SICOT)*, 2007, 31: 719-720.
21. Lind M, Bunger C: Orthopaedic application of gene therapy. *Int.Ortho.(SICOT)*,2005, 29: 205-209.
22. Haverkamp D, Marti RK: Bilateral varus osteotomy in hip deformities: are early interventions superior? A long-term follow – up. *Int. Ortho.(SICOT)*, 2007, 31: 185-191.