

## Glomus tumours of the Hand in Lagos, Nigeria

B.O. Mofikoya<sup>1</sup>, C.C. Anunobi<sup>2</sup>, G.O. Enweluzo<sup>3</sup>

<sup>1</sup>Burns , Plastic Surgery Hand rehabilitation units, Department of Surgery College of Medicine University of Lagos , P M B 12003 Surulere, Lagos , Nigeria

<sup>2</sup>Morbid Anatomy Department , College of Medicine , University of Lagos , P M B 12003 Surulere, Lagos, Nigeria

<sup>3</sup>Trauma and Hand rehabilitation unit , College of Medicine , University of Lagos , P M B 12003 Surulere, Lagos, Nigeria

*Correspondence to:* Dr. BO Mofikoya, Email: bmofikoya@yahoo.com

**Background:** Glomus tumours of the hand are uncommon intriguing tumours which cause significant morbidity. Few reports have documented the epidemiology and presentation in the West African subregion. The aim of this review is to identify the common baseline demographics, the presentation, evaluation, diagnosis and treatment outcome of glomus tumours of the hand in Lagos, Nigeria

**Methods:** A 10 year retrospective review of the records of all patients seen with histopathologically diagnosed glomus tumor of the hand at the Lagos University teaching hospital was carried out noting the biodata, demographics, method of presentation and treatment of this condition.

**Results:** 11 patients were seen over the study period .There were nine females and 2 males seen. The mean age of the patients was 41 years. The symptoms had been on for between 3 and 40 months .All patients seen had a positive Love test. Only one patient had associated bony erosion. All had complete excision with no recurrence at 6 months

**Conclusion:** Glomus tumor of the hand is an uncommon tumour often occurring in adult women. Clinical test (Love “test”) will correctly identify the diagnosis. Surgical treatment was curative in all our cases. High index of suspicion is needed to make earlier diagnosis.

### Introduction

Glomus tumours of the hand are said to make up between 1% and 5% of all soft tissues tumours in the hand<sup>1</sup>. Though first described by Wood in 1812, it was Masson that accurately described the histopathology that has puzzled surgeons for centuries in 1924<sup>2</sup>. Masson recognized that the large polyhedral cells found are similar to those found in the coccygeal gland or glomus coccygeum and named the lesion glomus( latin for ball)<sup>1-3</sup>. Glomus bodies are present in the stium reticularis of the dermis and occur all over the body. They are particularly concentrated around the tips of the digits and in the subungal region<sup>4</sup>. The typical presentation of glomus tumour in the hand is that of pain which develops from contraction of the glomus cells, can be excruciating paroxysmal and aggravated by changes in environmental temperature particularly cold<sup>5</sup>.

On account of very few reports concerning this condition in our subregion we present a 10 year review of 11 operated cases at Hand rehabilitation clinic of the Lagos university teaching Hospital as well as a clinicopathologic review of literature.

### Patients and Methods

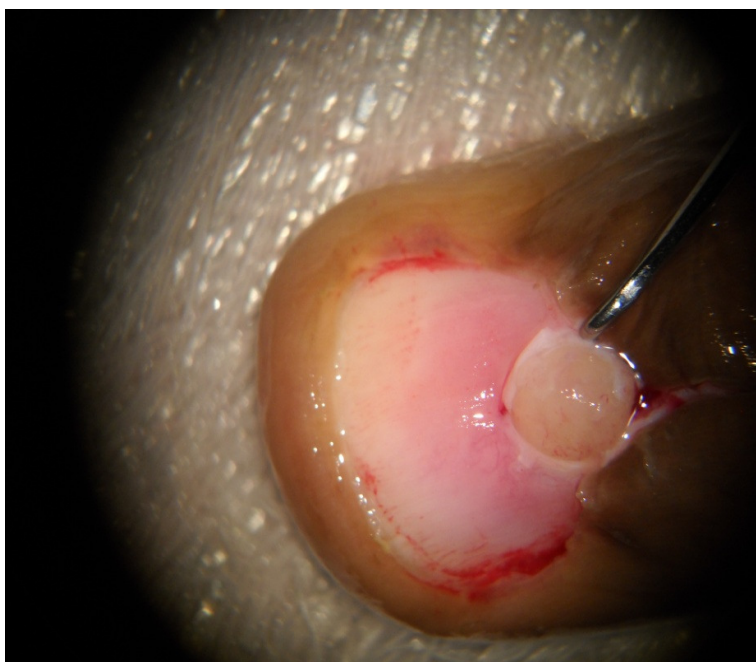
We reviewed the records of all patients who had surgery for histopathologically confirmed glomus tumours of the hand at the Hand rehabilitation unit of the Lagos university Teaching hospital from July<sup>1st</sup> 2000 to 30<sup>th</sup> of June 2010. The case records were studied for age, sex, duration of symptoms, location of the lesion, type of treatment, final histopathologic diagnosis and early results. All patients had their diagnosis made clinically and surgery was done under digital block or intravenous regional (Biers ) block in a bloodless field under an operating microscope .Lesions over the volar digits were directly excised via an incision over the most tender spot. The subungal lesion were excised following an initial nail plate removal, matrix splitting careful tumour excision with the tip of size 15 scapel blade and a careful closure of the nail matrix with 6/0 vicryl and replacement of the nail matrix

(Figure 1) . Surgery was done on outpatient basis in all cases. All patients were followed up for a minimum period of 6 months.

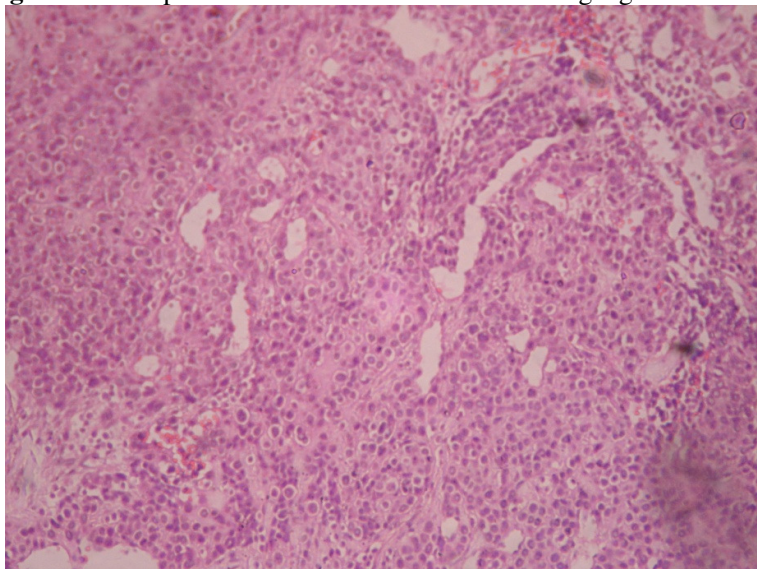
### Results

**Table 1.** Characteristic Features of Patient

No	Age	Sex	Occupation	Duration of symptoms(Months)	Side	Location of Lesion	X –ray Changes
1	21	F	Student	4	R	Distal phalanx base (radial)	-ve
2	34	F	Teacher	7	R	Peri-ungal	+ve
3	44	M	Bussiness	4	L	Proximal phalanx radial border	-ve
4	48	M	Bussiness	10	L	Distal phalanx base (volar)	-ve
5	58	F	Retired	45	R	Distal Phalanx pulp	-ve
6	57	F	Unemployed	40	R	Distal phalanx pulp	-ve
7	60	F	Retired	12	L	Proximal phalanx radial border	-ve
8	41	F	Secretary	18	L	Proximal phalanx ulnar border	-ve
9	35	F	Bussiness	4	R	middle phalanx volar	-ve
10	26	F	Student	3	L	Subungal	-ve
11	31	F	Bussiness	9	R	Proximal phalanx ulnar border	-ve



**Figure 2.** Intraoperative views of excision of a Subungal glomus tumour



**Figure 2.** Glomus tumour. Section showing solid nests of compact polyhedral cells surrounding blood vessels (H & E X 100)

Eleven patients were studied over the stated period. All nine females and two males presented with marked unexplained pain over the various parts of the digits. The mean age of the patients studied was 41 years. Six patients presented with lesions at the tip of the digits of which 3 were around the nail and one subungal. Four patients had pain along the lateral surface of the digits and one patient had painful lesion along the ulnar border of the little finger. Duration of symptoms ranged from 3 to 40 months. None of the patients seen had a correct diagnosis prior to presentation. There was no overt swelling in all but one patient. Four patients admitted to cold intolerance. All patients demonstrated a positive Love's test. Hildreth's test was not elicited in any of the patients.

Only one patient demonstrated a lytic erosion of the distal phalanx. All patients were seen for up to 6 months and were all symptom free. Longer follow ups were impossible on account of default.

### Discussion

Glomus tumor- is an uncommon vascular tumour which is said to occur at any age, at any anatomical site but with a predilection for the subungal region. Over a third of these tumours occur in the hands<sup>6,7</sup>.

#### *Aetiology and pathogenesis*

The normal glomus body is a contractile neuromyoarterial receptor that controls blood pressure and temperature by regulating flow in the cutaneous microvasculature<sup>8</sup>. Anatomically the glomus bodies are made up of an afferent arteriole, a vascular anastomosis (the Sucquet-Hoyer canal), a collecting vein, an intraglomerular reticulum, (containing glomus cells, nerve fibres and interstitial cells) and a capsule<sup>9</sup>. The glomus cells are specialized smooth muscle cells derived from Zimmerman pericytes and they are concentrated around the dilated vascular space. Changes in temperature lead to contraction of myofilaments in the glomus cells resulting in an increase in intracapsular pressure that is transmitted by the unmyelinated nerve fibres leading to the perception of pain<sup>10</sup>. Glomus bodies are highly concentrated in the tips of digits, especially under the nail. So, the tumors are usually in the subungual area<sup>11</sup>. Nearly 75% of glomus tumors are localized in the hands, particularly in the nail apparatus<sup>12</sup>. Occasionally glomus tumours can occur in extracutaneous sites such as the gastrointestinal tract, bone, genitourinary system and respiratory tract.<sup>13</sup> Although the cause of glomus tumour is unknown some authors have proposed that a weakness in the structure of the

glomus body may lead to reactive hyperplasia following trauma or that they represent hamartomas in which the components are hypertrophied<sup>9</sup>.

### **Classification**

Glomus tumors can be divided into 2 variants: solitary and multiple. Solitary glomus tumors are more common, usually occur in adults, and are predominantly found in the extremities, particularly the nail bed<sup>10,14</sup>. Multiple glomus tumors, also known as glomangiomas or glomovenous malformations due to their angiomatous appearance, account for less than 10% of all cases. Unlike the solitary forms of the tumor, these appear in younger patients and usually exhibit autosomal dominant inheritance with variable expression. Unlike the solitary forms, multiple glomus tumors tend not to be painful<sup>15</sup>.

### **Histology**

Grossly isolated glomus tumors present as a small painful bluish nodule. The cut surface of the tumor could be firm and solid or cystic, and gray or grayish-red or grayish-white, or dark brown in color.<sup>16</sup>

Microscopically, the tumour is constituted by an afferent arteriole and vascular channels lined by normal endothelial cells and surrounded by a solid proliferation of round or cuboidal cells (figure 2)<sup>17,18</sup>. The glomus tumour cells are usually uniformly monotonous with oval to round hyperchromatic nuclei homogenous chromatin and scant eosinophilic cytoplasm<sup>19</sup>.

The glomus tumours are made up of three components: glomus cells, vascular structures and smooth muscle cells. According to the World Health Organization (WHO) Classification of Tumors of Soft Tissue and Bone (2002)<sup>20</sup>, glomus tumour can be further divided into “solid glomus tumor”, “glomangioma”, and “glomangiomyoma” depending on the relative prominence of glomus cells, vascular structure and smooth muscle. The solid glomus tumours are made up of few vascular structures and few if any smooth muscle cells while the glomangiomas which are less well circumscribed contain prominent large vascular channels. The glomangiomas are variants that show a predominance of vascular structures and smooth muscle cells.

No nuclear pleomorphism or mitotic activity is in glomus tumours generally. The tumours are usually well circumscribed but unencapsulated, and the background stroma may be fibrous or myxoid.<sup>21</sup>. Immunohistochemically they manifest reactivity for myosin, vimentin, actin and basal lamina components but not for desmin<sup>19,21</sup>. Endothelial markers are absent in the tumour cells<sup>21</sup>

According to the WHO Classification of Tumors of Soft Tissue and Bone<sup>20</sup>, “glomus tumor” should be defined as a malignant tumor when its size is > 2 cm and located at subfascia or viscera, with atypical mitotic figures or marked nuclear atypia and mitotic activity. However whether these tumours are truly aggressive biologically is a debatable point<sup>22</sup>

Our finding of eleven cases over 10 years in one major urban tertiary care center may reflect the uncommon nature of this tumor as this is comparable to the many reports<sup>23,24</sup>. Most studies<sup>24,25</sup> show a clear female predominance of this lesion as documented in our findings of male : female ratio of 1:5. Some workers have suggested that hand subungual tumours are commoner in females while extradigital tumours show a male preponderance<sup>6,26</sup>. Our mean age incidence was 41 years generally reflecting our young adult population. Even though the duration of symptoms ranged from 3 to 40 months, the universal absence of a correct diagnosis prior to presentation demonstrates the low awareness of this condition among our health workers. This is similar to other reports<sup>3,26</sup>.

Exquisite tenderness on localized pin head compression (Love's test) was positive in all patients seen by us. Our findings were same with that of Bhaskaranand and Navadgi<sup>27</sup> i.e this test is 100% sensitive and specific for glomus tumor of the hand. Though high resolution MRI has been shown to clearly delineate the lesion, with tumor showing high signal intensity on T2 weighted spin MR images and strong enhancement after Gadolinium injection<sup>4</sup>. This modality is not cost effective for many of our patients as the cost of surgery is about 10% to 20% the cost of MRI. We tend to agree with

Dahlin<sup>5</sup> that exploration of a clinically painful fingertip is justifiable based on clinical suspicion of a glomus tumour.

Our operative approach was direct incision over the most tender point and complete en bloc excision of the tumour under digital block. Transungual incision has been the approach for many decades, recently there have been approaches aimed at minimizing trauma to the nail bed using the lateral approach<sup>11,17</sup>, some have advocated the volar approach<sup>28</sup>. Few centers use general anaesthesia because of the possible need to harvest a nail bed graft from the toe nail.

We believe our 6 month follow up period is too short to be able make useful deductions from. However recurrence rates of between 1 and 18 % have been reported in literature<sup>23</sup>. Lesion recurring within months of surgery is generally due to inadequate excision while that occurring more than 2 years after surgery is regarded as a true recurrence.

### Conclusion

In conclusion Glomus tumours of the hand are uncommon tumors arising from glomus bodies which are numerous around the finger tips. Typically made up of glomus cells, vascular structures and smooth muscle cells, they commonly present as pain and hypersensitivity in the digits. They can be a considerable source of morbidity when diagnosis is delayed. Surgical excision is usually curative.

### References

1. Tuncali D, Yilmaz AC, Terzioglu A, et al. Multiple occurrences of different histologic types of the glomus tumor. *J Hand Surg.* 2005;30A:161–164.
2. Masson P. Le glomus neuromyo-arterial des regions tactiles et ses tumeurs. *L J ~ Coh~ir* 1924; 21: 256-80.
3. Carroll RE, Berman AT. Glomus tumors of the hand: A Review of literature and a report on twenty eight cases. *J Bone Joint Surg Am.* 1972;54:691-703.
4. Theumann NH, Goettmann S, Le Viet D, Resnick D, Chung CB, Bittoun J, et al. Recurrent glomus tumors of fingertips:MR imaging evaluation. *Radiology* 2002;223:143–151
5. Dahlin LB, Besjakov J, Veress B. A glomus tumour: classic signs without magnetic resonance imaging finding. *Scand J Plast Reconstr Surg Hand Surg.* 2005;39:123–125.
6. Tsuneshoshi M, Enjoji M. Glomus tumor : A clinicopathologic and Electron microscopic study. *Cancer* 1982;50 1601-1607
7. Heys SD, Brittenden J, Atkins P, Eremin O. Glomus tumor ; An analysis of 43 patients and review of literature. *Br J Surg* 1982;79:345-347
8. Sorene ED, Goodwin DR. Magnetic resonance imaging of a tiny glomus tumour of the fingertip : a case report. *Scand J Plast Reconstr Surg Hand Surg.* 2001;35:429–431.
9. E Samaniego, A Crespo, and A Sanzkey diagnostic features and treatment of subungual glomus tumor. *Actas Dermasifiliogr.* 2009;100:875-82
10. Rohrich R, Hochstein L, Millwee R. Subungueal glomus tumors: an algorithmic approach. *Ann Plast Surg.* 1994;33: 300-4
11. Vasisht B, Watson HK, Joseph E, Lionelli GT. Digital glomus tumors : a 29-year experience with a lateral subperiosteal approach. *Plast Reconstr Surg.* 2004;114:1486–1489.
12. Laura de Sena Nogueira Maehara, Eugenia Maria Damasio Ohe, Mauro Yoshiaki Enokihara, Nilceo Schwery Michalany, Sergio Yamada, Sergio Henrique Hirata. Diagnosis of glomus tumour by nail bed and matrix dermoscopy. *An. Bras. Dermatol.* 2010; 85(2) : 236-238
13. Kleontas A, Barbetakis N, Asterion C, Nikolaidou A, Baliaka A et al. Primary glamangiosarcoma of the lung: A case report. *J. Cardiothoracic surg* 2010. 4;5(1):76
14. Gombos Z, Zhang P. Glomus tumor. *Arch Pathol Lab Med.*2008;132:1448-52
15. Hui-Qiong Fang, Jing Yang, Fen-Fen Zhang, Yi Cui, An-Jia Han. Clinico-pathological features of gastric glomus tumour. *World J Gastroenterol.* 2010.1636; 16(36) :4616-4620.
16. Monteagudo B, de las Heras C, Requena L, Ginarte M. Solitary congenital plaque-like telangiectatic glomangioma. *Acta Dermofiliogr* 2007; 98(9): 649-51.



17. McDermott EM, Weiss AP. Glomus tumors. *Hand Surg.* 2006;31:1397-400.
18. Baran R, Richert B. Common nail tumors. *Dermatol Clin.* 2006;24:297-311.
19. Mehdi G, Siddiqui F.A, Ansari HA, Mansoor T. Glomus tumour occurring in male breast – An unusual site of presentation. *J Postgrad Med.*2010;56;218-9
20. Folpe AL. Glomus tumours. In: Fletcher CDM, Unni KK, Mertens F, editors. World Health Organization Classification of Tumours: Pathology and Genetics of Tumours of Soft Tissue and Bone. Lyon: IARC Press, 2002: 136-137
21. Mehdi G, Siddiqui F.A, Ansari HA, Mansoor T. Glomus tumour occurring in male breast –An unusual site of presentation. *J Postgrad Med.*2010;56;218-9
22. Folpe AL et al. Atypical and malignant glomus tumours: analysis of 52 cases with a proposal for the reclassification of glomus tumours. *Am J Surg Pathol.* 2001;25(1):1-12
23. Nazerani S, Motamedi M, Keramati M. Diagnosis and management of glomus tumors of the hand. *Technique in hand and upper extremity surgery* 2010;14(1):8-13
24. Foucher G, Le Viet D, Dailiana Z, Pajardi G. Glomus tumor of the nail area a series of 55 cases . *Revue de Chirurgie Orthopédique et Traumatologique* 1999; Vol 85, N° 4 - août p. 362
25. De Maertelie W, Naetens P, De Smet L. Glomus tumors . *Acta Orthopaedica Belgica* 2000;66;169-173
26. Fletcher CDM, Unni K, Meretens F, eds. Pathology and Genetics of Tumours of the Nervous System. Lyon, France: IARC Press; 2002:136–137.
27. Bhaskaranand K, Navadgi BC. Glomus tumour of the hand. *J Hand Surg* 2002;27B:229 – 231.
28. Afsar AR, Abdi-Rad I. Volar approach to extirpate subungual glomus tumors : A Report of 2 cases . *Arch Iranian Med* 2005; 8 (4): 311 – 313