

Basic Surgical Skills Corner**Chest Tube insertion – The need for safe practices****S.A. Salati**

King Fahad Medical City, Riyadh, Saudi Arabia.

Email : docsajad@gmai.com

Cases are regularly being reported in literature regarding complications arising out of chest tube insertion¹⁻⁴ indicating the need to propagate and educate safe methods of chest tube insertion. Careless approach by the medical practitioner can cause morbidities and mortalities and guidelines and recommendations for safer practice are being published from time to time⁵. I would like to stress the following factors related to chest tube insertion :

1. **Consent:** The importance of informed and documented consent needs to be highlighted. In developing and underdeveloped world, the consent in its true sense is usually neglected due to economic and educational backwardness of the masses. The patient irrespective of his social status has the right to know about his disease and the proposed procedure along with the possible complications and alternatives.
2. **Pre-procedure preparation:** The most important factor is to arrange an operator knowing the procedure fully. In a published study from western literature where doctors were asked to indicate where they would insert a chest drain, 45% indicated they would insert the drain at a wrong site⁶. Preoperative preparation would also involve proper imaging (except in tension pneumothorax) and to rule out conditions likely to cause complications like coagulopathy.
3. **Site of insertion:** Immediately prior to the procedure the identity of the patient should be verified and the site and side for insertion of the chest tube confirmed by reviewing the clinical signs and the chest radiograph. Proper positioning needs to be ensured. For chest tube insertion, the concept of Safety Triangle⁵ (Fig 1) needs to be taught and it will be really helpful if this figure is hung over the walls of emergency rooms along with other commonly used figures like Glasgow Coma scale, Wallace's rule of 9 etc. This is the triangle bordered by the anterior border of the latissimus dorsi, the lateral border of the pectoralis major muscle, a line superior to the horizontal level of the nipple, and an apex below the axilla. This position minimises risk to underlying structures (eg internal mammary artery) and avoids damage to muscle and breast tissue resulting in cosmetically disagreeable scarring.

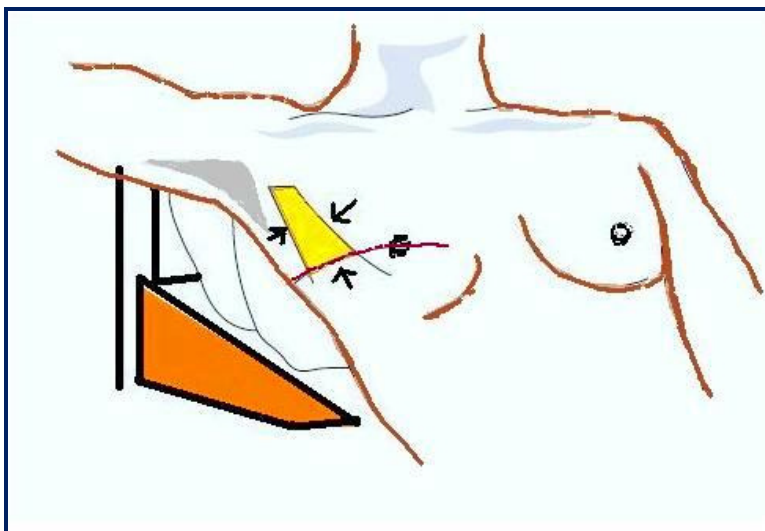


Figure 1. Safety triangle for chest tube insertion (yellow area pointed with black arrows)

4. **Aseptic Technique :** Chest tube insertion should take place in a clean area using full aseptic technique. Empyema is a serious and avoidable complication , the risk of which is greater with multiple attempts. Although this is uncommon, estimations of the empyema rate following drain insertions for trauma are approximately 2.4%⁷.
5. **Anesthesia and analgesia:** It needs to be stressed that chest drain insertion has been reported to be a painful procedure. In one study⁸, 50% of patients experienced pain levels of 9-10 on a scale of 10. Furthermore pains and discomfort can lead to sudden patient movements during procedure and resultant complications. This analgesia needs to be continued till the tube is in place.
6. **Size of the tube:** Size of the chest tube to be used is at best debatable. Studies have shown that the smaller sized tubes are often as effective as larger bore tubes⁹ and are in fact more comfortable and better tolerated by the patient. In the case of acute hemothorax, however, large bore tubes (28–30 F minimum) continue to be recommended for their dual role of drainage of the thoracic cavity and assessment of continuing blood loss¹⁰.
7. **Post procedure care:** The position of the chest tube needs to be verified by imaging. This proper care needs to be continued as complications can arise which include pain, malfunction, dislodgement and infection. Furthermore proper technique needs to be applied for chest tube removal as complications including pneumothorax and bleeding can occur at this stage when the patient has recovered from initial cause of tube thoracostomy and these complications can potentially prolong the misery of the patient. Traditionally, chest radiographs have been done on all patients immediately after tube removal to detect complications, but recently studies¹¹ have questioned the necessity of such imaging and exposure to radiation. Palesty JA *et al*¹¹ described a retrospective review of 73 patients with tube thoracostomy. Out of these 73 patients, only 8 patients' radiology reports changed after the chest tube removal. Of those, two required chest tube reinsertion (2.7%), but in both cases the decision was based on clinical assessment rather than on radiographic findings

References

1. Chad G. Ball, Jason Lord, Kevin B, et al. Chest tube complications: How well are we training our residents? *Can J Surg*. 2007 December; 50(6): 450–458.
2. Bailey RC. Complications of tube thoracostomy in trauma. *J Accid Emerg Med* 2000;17:111-4.
3. Gilbert TB, McGrath BJ, Soberman M. Chest tubes: indications, placement, management and complications. *J Intensive Care Med* 1993;8:73-86
4. Deneuille M. Morbidity of percutaneous tube thoracostomy in trauma patients. *Eur J Cardiothorac Surg* 2002;22:673-8
5. D Laws, E Neville, J Duffy .BTS guidelines for the insertion of a chest drain. *Thorax* 2003;58(Suppl II):ii53–ii59
6. Griffiths JR, Roberts N. Do junior doctors know where to insert chest drains safely? *Postgrad Med J* 2005; 81(957):456-58.
7. Millikan JS, Moore EE, Steiner E, et al. Complications of tube thoracostomy for acute trauma. *Am J Surg* 1980;140:738–41
8. Luketich JD, Kiss M, Hershey J, et al. Chest tube insertion: a prospective evaluation of pain management. *Clin J Pain* 1998; 14(2):152-54.
9. Clementsen P, Evald T, Grode G, et al. Treatment of malignant pleural effusion : pleurodesis using a small bore catheter. A prospective randomized study. *Respir Med* 1998; 92:593–96.
10. Parry GW, Morgan WE, Salama FD. Management of haemothorax. *Ann R Coll Surg Engl* 1996;78:325–6.
11. Palesty JA, McKelvey AA, Dudrick SJ: The efficacy of x-rays after chest tube removal. *American Journal of Surgery* 2000; 179(1):13-16.