

A Rare Case of Extraosseous Osteosarcoma of the Parotid Gland

A. Adeyemo¹, A. O. Komolafe², S. A. Ameye¹, A. M. Owojuyigbe³, A. O. Olakanmi⁴, S. Ohuche⁵

¹Otorhinolaryngology Unit, Department of Surgery, Obafemi Awolowo University, Ile-Ife.

²Department of Morbid Anatomy, Obafemi Awolowo University, Ile-Ife

³Department of Anaesthesia and Intensive care, Obafemi Awolowo University, Ile-Ife.

⁴Department of Surgery, Ondo Trauma Centre, Ondo State

⁵Department of Otorhinolaryngology Head and Neck Surgery, Obafemi Awolowo University Teaching Hospitals Complex, Ile-Ife.

Correspondence to: Dr Sanyaolu A. Ameye, Email: sanyaameye@hotmail.com; ameyesa@oauife.edu.ng

Primary extraosseous osteosarcomas (EEO) are very rare and extraosseous osteosarcoma of the parotid gland is even rarer. When they occur, EEO pursues a very aggressive course. The consequence of the rarity of this malignancy and its aggressive course is that treatment guidelines are not yet standardized. We present a case of extraosseous osteosarcoma of the parotid gland we encountered in our practice

Key Words: Extraskelatal Osteosarcoma, extraosseous osteosarcoma, Parotid gland, salivary gland, Cancer.

DOI: <http://dx.doi.org/10.4314/ecajs.v21i2.17>

Introduction

Among all the various salivary glands, the parotid gland is the most commonly involved in neoplasm^[1]. Despite this, primary malignant tumours of the parotid gland are still rare and there are several histological subtypes that can be seen in this gland^[2].

Extra-skeletal or extraosseous osteosarcoma is an aggressive mesenchymal tumour that characteristically produce osteoid, bony or cartilaginous elements without clinical or radiological evidence of bone attachment at diagnosis^[3]. Histological types described include osteoblastic, chondroblastic, fibroblastic, osteoclastic (Giant cell), telangiectatic, small cell (well differentiated) forms. Extraosseous osteosarcomas are relatively rare and involvement of the parotid gland by this tumour is even rarer^[4]. Sarcomas affecting salivary glands commonly arise in a previously irradiated gland or in a background of a previous salivary gland tumour^[5].

The prognosis of EEO is generally poor. Aside from the aggressive nature of this tumours^[6, 7], the late presentation is also a major contribution to the poor prognosis in our environment^[8].

We present a case of extraosseous osteosarcoma of the parotid gland.

Case Report

The patient is a 46-year-old male trader with an 8-month history of left sided progressively increasing jaw swelling which was initially painless but became painful close to the time of presentation. The patient did not notice any change in the swelling with meal or change in the overlying skin. He had no nasal, throat or ear complaints. There was no history of fever, weight loss or night sweat. The patient did not notice swelling in any other part of the body.

He was a known hypertensive diagnosed 9 years prior to presentation and blood pressure was controlled and stable on anti-hypertensives. He was however not a known diabetic and had no

other known chronic medical condition. He has no history of head and neck irradiation. He had no family history of cancer and had never smoked tobacco or taken alcohol.

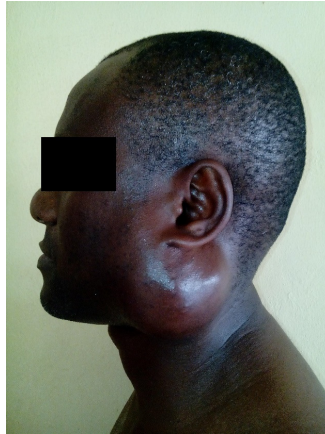

Figure-1. Left side view of the patient showing the mass.

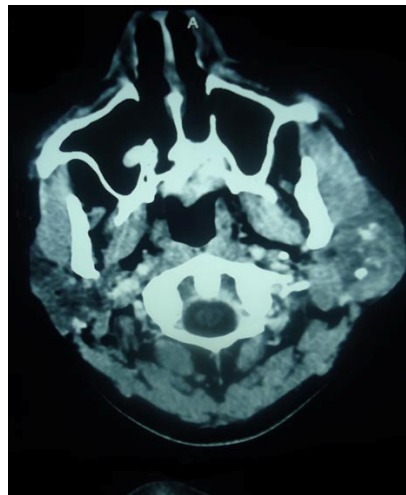


Figure 2. Axial slice showing the parotid mixed density lesion with no involvement of the mandible.

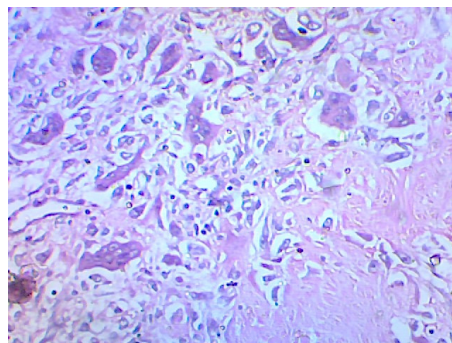


Figure 3. (H&E X 200). The section from the mass shows numerous giant cells (upper part of the microphotograph) and osteoid (right lower corner) that are laid down by the proliferating malignant spindle cells.

Examination revealed a healthy looking man who was not in any distress. No physical evidence of pallor, dehydration, and jaundice. His temperature was normal. Cardiorespiratory examination findings were also essentially normal.

He had a large left jaw mass 16cm x 14cm displacing the pinna cranially with normal overlying skin. The mass was hard, not tender and not differentially warm. It was fixed to underlying structures but not to skin. No intraoral extensions of the mass. No bruits heard over the mass and no neck masses.

He had left facial nerve palsy (House-Brackmann I).

Chest and abdominal examination were essentially normal. An FNAC of the Jaw swelling was reported as inflammatory. Chest X-ray and abdominal ultrasound are normal.

Computerized Tomographic Scan of the region showed a large hypodense lesion in the left parotid region with areas of eggshell calcification. The mass extended into the deep lobe of the parotid. The ipsilateral temporal bone and the mandible showed no evidence of involvement. (Fig 1).

A provisional diagnosis of the left benign parotid tumor to rule out malignancy was made.

The patient had left Total Conservative Parotidectomy under general anaesthesia. Intraoperatively, we found a large 10cm x 6cm hard mass not distinct from the parotid. Mass is attached to the upper part of the ipsilateral sternocleidomastoid muscle and the lower division of the facial nerve. The post-operative period was uneventful.

Histopathology of the mass showed tissue composed of proliferating malignant mesenchymal cells. These malignant cells are spindle shaped. Polyhedral, large cells are found intermixed within and in direct contact with lacelike and sheet-like osteoid of which is laid down by them. There are also numerous osteoclast-like multinucleated giant cells distributed throughout the tissue stroma. There are tumour giant cells as well as numerous mitotic figures. This finding suggested the histological diagnosis of osteosarcoma (Giant cell rich variant). Based on this report, the patient was referred to oncologists for chemo-radiation.

He was free of local recurrence and distant metastasis 4 months post operation.

Discussions

We chose to report this case because of the extreme rarity of EOO occurring in the parotid gland. To our knowledge, there are less than 5 reported cases of EOO of the parotid gland in literature in the last 20 years.^[4,9]

Osteogenic sarcoma is the commonest primary bone malignancy of young adults with several known histological subtypes including extraosseous variants^[10]. Primary extraosseous osteosarcoma classically described as producing osteoid but devoid of attachment to bone^[8].

The distinction between benign and malignant parotid tumour seems to blur with regard to clinical presentations, our initial impression had to do with the relative rarity of malignant tumours of the parotid compared to other salivary glands^[2]. Our miss with regards to the final diagnosis was not however influenced by the negative FNAC as we are fully aware of the implication of negative FNAC finding in patients with parotid gland tumours^[11].

Our patient's tumour was seen as a soft tissue mass with no bony attachments consistent with extraosseous osteosarcoma. However, benign parotid tumours too do not attach to the bone thus this knowledge did not help in reaching the final diagnosis. Extraosseous osteosarcoma

sometimes occurs in a background of previously existing neoplasia or following radiation exposure in 10% of cases [5]. Our patient who had hitherto had been in excellent health with no previous irradiation.

The peak age of occurrence has been found to be predominantly in middle-aged and older adults [6, 12] although there is a report in our environment of 3 patients out of 5 being under 20 years old [8]. The age and sex of our patient are, however, consistent with what has been commonly reported from several centres [7, 13, 14].

This tumour is known to be very aggressive with a very high recurrence rate [6, 7]. Reports from several authors reveal a tendency toward early local recurrence within 2 years and a propensity for early metastasis. Our patient presented with a rapidly growing tumour suggestive of an aggressive tumour however our duration of follow-up is not enough to determine the possibility of local failure or not, there were, however, no evidence of distant metastasis.

Generally, patients in our environment present late and this has often limited the options available to the surgeons. This was the experience of Alonge et al in which late presentation was reported to have contributed to the poor prognosis of their patients [8]. However, our index patient presented early though the part of the body affected, i.e. the parotid precluded biopsy that could have given us a pre-operative definitive diagnosis. We believe that this would have influenced the extent of the surgery especially with regards to sparing the facial nerve.

We decided to use multimodal management in our patient due to the aggressive nature and the poor prognosis associated with the tumor. This decision was also based on the similar experience of other workers [9, 15].

In conclusion, the extreme rarity of extraosseous osteosarcomas in the head and neck makes it important for reporting so that there can be enough knowledge base to understand this disease. It is important also for head and neck surgeons to be aware that osteosarcoma can occur in the salivary glands. Therefore, this tumour should be considered when confronted with an aggressive hard salivary gland tumour.

References

1. Watkinson J, Gilbert RW. Stell & Maran's Textbook of Head and Neck Surgery and Oncology: CRC Press; 2011.
2. Seifert G, Sobin LH. The World Health Organization's histological classification of salivary gland tumors. *Cancer*. 1992;70(2):379-85.
3. Enzinger F, Weiss S. Osseous soft tissue tumors. *Soft tissue tumors*, 3rd edn Mosby, St Louis. 1995:1013-39.
4. Manning JT, Raymond AK, Batsakis JG. Extraosseous osteogenic sarcoma of the parotid gland. *The Journal of Laryngology & Otology*. 1986;100(02):239-42.
5. Maillie HD, Gilda JE. Radiation-induced cancer risk in radiographic cephalometry. *Oral Surg Oral Med Oral Pathol*. 1993;75(5):631-7.
6. Sordillo PP, Hajdu SI, Magill G, Golbey R. Extraosseous osteogenic sarcoma. *Cancer*. 1983;51(4):727-34.
7. McCarter MD, Lewis JJ, Antonescu CR, Brennan MF. Extraskelatal osteosarcoma: analysis of outcome of a rare neoplasm. *Sarcoma*. 2000;4(3):119-23.
8. Alonge TO, Obamuyide HA, Ogun GO. Extraosseous osteosarcoma in Ibadan: case series over a 20-year period. *Rare tumors*. 2009;1(1).
9. Stimson PG, Valenzuela-Espinoza A, Tortoledo ME, Luna MA, Ordonez NG. Primary osteosarcoma of the parotid gland. *Oral surgery, oral medicine, oral pathology*. 1989;68(1):80-6.



10. Meyers PA, Gorlick R. Osteosarcoma. Pediatric Clinics of North America. 1997;44(4):973-89.
11. Hee CGQ, Perry CF. Fine-needle aspiration cytology of parotid tumours: Is it useful? ANZ J Surg. 2001;71(6):345-8.
12. Lin S-Y, Chen W-M, Wu HH, Chen WY-K, Chen T-H. Extrasosseous osteogenic sarcoma. Journal of the Chinese Medical Association. 2005;68(11):542-5.
13. Lee JS, Fetsch JF, Wasdhal DA, Lee BP, Pritchard DJ, Nascimento AG. A review of 40 patients with extraskeletal osteosarcoma. Cancer. 1995;76(11):2253-9.
14. Torigoe T, Yazawa Y, Takagi T, Terakado A, Kurosawa H. Extraskeletal osteosarcoma in Japan: multiinstitutional study of 20 patients from the Japanese Musculoskeletal Oncology Group. Journal of Orthopaedic Science. 2007;12(5):424-9.
15. Ahmad SA, Patel SR, Ballo MT, Baker TP, Yasko AW, Wang X, et al. Extrasosseous osteosarcoma: response to treatment and long-term outcome. Journal of Clinical Oncology. 2002;20(2):521-7.