

## **A 32- Weeks Abdominal Pregnancy with Live Foetus Presenting as Acute Abdomen: A Case Report**

**A Ojuka, S Lukens, A Lasta**

Kanye SDA Hospital, Botswana

**Correspondence to:** Andrew Ojuka, Email: [andrewojuka@gmail.com](mailto:andrewojuka@gmail.com)

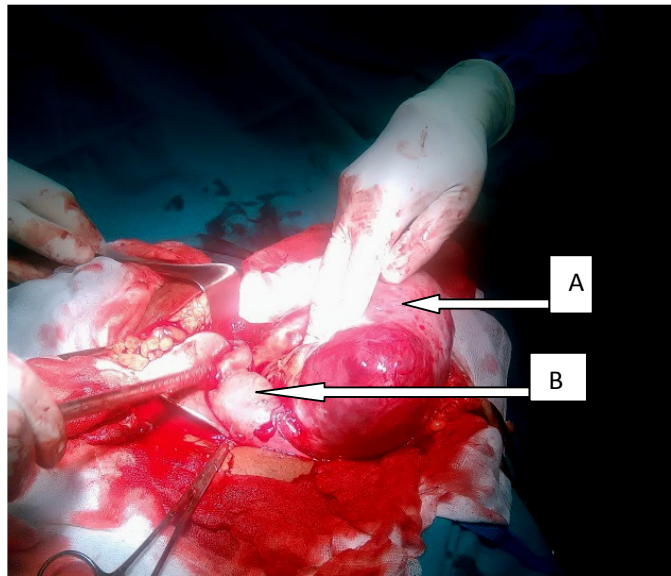
### **Introduction**

*Abdominal pregnancy is a very rare type of ectopic gestation, with its frequency been directly related to the frequency of ectopic gestation in the population<sup>1,2</sup>. About 2% of all pregnancies are ectopic and abdominal pregnancy where implantation occurs within the peritoneal cavity is much more uncommon, accounting for 1%-4% of all ectopic pregnancies<sup>2</sup>. The incidence of abdominal pregnancy differs in various publications and ranges between 1: 10000 pregnancies and 1:30,000 pregnancies.<sup>(3,4)</sup> It is more common in developing countries<sup>(1)</sup> and is life threatening condition that requires early and accurate diagnosis if the severe complications associated with it are to be avoided. <sup>(2)</sup> It was reported for the first time in 1708 as an autopsy finding and numerous cases have been reported worldwide ever since. In most of these cases, the diagnosis is made on the basis of the ensuing complications such as hemorrhage and abdominal pain. The clinical presentation of abdominal pregnancy is variable and physical examination by its self may be insufficient for the diagnosis.<sup>(2, 5)</sup> Clinical features such as persistent abdominal pain, painful fetal movements, weight loss, abnormal presentations, uneffaced and displaced cervix, vagina bleeding and, palpation of an abdominal mass distinct from the uterus should raise the suspicion<sup>1, 6</sup>. To assist in pre-operative diagnosis and reduce errors, an array of diagnostic procedures including oxytocin stimulation, abdominal x-ray, hysterosalpingography and ultrasound scan have been use.<sup>7, 8</sup> Most cases of advanced abdominal pregnancy are associated with dead fetuses<sup>2,5,6</sup>. A case of abdominal pregnancy with live fetus in 16 years old mother at 32weeks is hereby presented.*

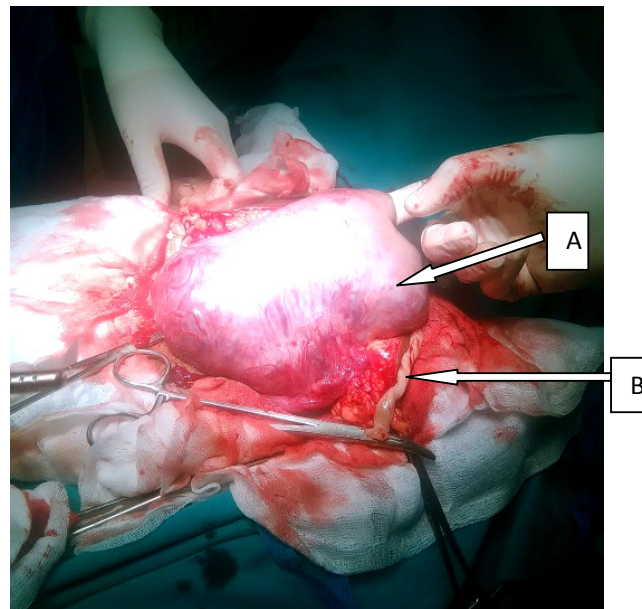
### **Case report**

A 16-year old, Prime gravida, was admitted at 32 weeks of amenorrhea with sudden severe generalized abdominal pain. She had no PV bleeding. She had attended antenatal care clinic 5 times and had unremarkable reviews. She had done 2 obstetric scans at 19 and 25 weeks of amenorrhea and both had indicated single intra uterine pregnancy with anterior low lying placenta with adequate liquor volume.

On examination, she was in pain though was not pale and had normal vital signs. Cardiovascular and respiratory systems did not reveal any abnormalities. Abdominal examination had generalized tenderness with guarding. Palpation of fetal parts and auscultation of fetal heart rate was difficult due to the guarding. Vaginal examination revealed closed cervix with no bleeding. Ultrasound scan done showed single fetus with heart rate of 146bpm in transverse lie with large anterior placenta suspicious of concealed abruptio placenta and there was oligohydromnios. The sonographer could not confirm whether the pregnancy was intrauterine or not. The hemoglobin level was 10.2g/dl. She was taken for emergency caesarean section due to abruptio placenta.



**Figure 1.** The placenta(A) and the normal uterus(B)



**Figure 2.** Placenta (A)and the cord(B)

At operation, Pfannenstiel incision was first made then later converted to midline incision. Abdominal pregnancy with a live female baby weighing 1.2 kilograms lying free in the right hypochondrium without amniotic sac was found. There was meconium stained peritoneal fluid and the placenta was attached to the left ovary, left tube, left paracolic gutter and medially to the appendix (Figure 1).

The uterus, right tube and other abdominal organs were normal.

There was bleeding from detached portions of the placenta on the left ovary and tube during the operation, which prompted partial removal of the placenta and left salpingo-oophorectomy to achieve haemostasis. Tube drainage was left to monitor bleeding postoperatively. Total estimated blood loss was 800mls.

A unit of compatible blood was transfused intra-operatively and another one was given postoperatively. The patient had uneventful recovery with the abdominal drain producing 300mls, 200mls, 50mls and nil on 1<sup>st</sup>, 2<sup>nd</sup>, 3<sup>rd</sup> and 4<sup>th</sup> postoperative days respectively. The abdominal drain was removed on the 4<sup>th</sup> postoperative day and the patient was discharged on the 7<sup>th</sup> post-operative day. Ultrasound scan done after three weeks of operations showed a mass 5cm x 4.3 cm posterior to the uterus. The patient remained in the hospital to take care of her premature baby who was admitted in the neonatal unit with no abnormalities and was showing normal growth and progress. Was discharged after 10 weeks when the child had gained 2kgs.

### Discussion

Abdominal pregnancy is a rare Obstetric complication with high maternal and even higher perinatal mortality<sup>7</sup>. Its diagnosis is difficult and a high index of suspicion is important in recognizing the condition<sup>2,7,8</sup>. In this case the patient presented with acute abdominal pain which could have resulted after acute rupture of the amniotic sac. This was more evident by the fact that the last two previous scans had reported adequate liquor volume compared to the one done after her acute symptoms showing oligohydromnios. Other clinical presenting features include painful fetal movements, weight loss, vaginal bleeding and uneffaced cervix. Most of the cases of abdominal pregnancies are secondary from aborted or ruptured tubal pregnancy.<sup>(9)</sup> In this case, abdominal implantation could have been secondary to undiagnosed ruptured left tubal ectopic pregnancy. Clinical diagnosis can be very difficult and ultrasound is very helpful during the early stages of gestation but can also be disappointing in the later stages. However in our case the patient had two ultrasound scans that could not detect the abdominal pregnancy.

Other radiological studies such as MRI and CT scan are helpful in the later stages<sup>13</sup>. Unfortunately these advanced imaging technologies are not easily available in most parts of the third world. In poorly resourced centers, high index of suspicion is key for prompt diagnosis and timely intervention to prevent life-threatening complications.

Management of abdominal pregnancy poses a clinical challenge because of risk of maternal death from hemorrhage and the possibility of congenital abnormalities<sup>7</sup>. The widely accepted treatment is immediate laparotomy because of the above complications<sup>8</sup>. However, there has been debate regarding the use of a more conservative approach if the pregnancy is discovered after 24 weeks of gestation and the fetus is alive<sup>1</sup>. This approach should only be undertaken if the patient can be kept under strict observation, preferably in Hospital<sup>1,5</sup>. One of the challenging problems during laparotomy for abdominal pregnancy is risk of massive hemorrhage when attempts are made to remove the placenta<sup>7</sup>. It is advised that except the entire blood supply to the placenta can be secured with minimal risk to the patient; the placenta is best left in situ<sup>5</sup>. and make a follow up with human chorionic gonadotropin levels. The use of methotrexate to hasten placental involution and resorption has been reported<sup>7</sup>. The decision to remove the placenta or not can be a determining factor for the survival of the patient and this decision is subject to the surgeon's expertise and the particular case in question<sup>10</sup>. In our case there was

significant bleeding from one side of the detached portions of the placenta that prompted partial removal to achieve haemostasis.

The patient was transfused with two units of blood, one during the operation and the other one post operatively. Since most cases of advanced abdominal pregnancy are associated with fetal or maternal demise<sup>2,6,7</sup> delivery of live fetus at 32 weeks in a 16 year old mother in this case was interesting. For the newborn, it is very important to rule out congenital malformations. There are reports of fetal malformations as high as 40% associated with abdominal pregnancies and only 50% of these babies survive up to one week post-delivery<sup>11, 12</sup>. In this case the baby was normal without any malformations at birth.

### Conclusion

Abdominal pregnancy can present as acute abdomen in late pregnancy especially if the amniotic sac ruptures suddenly. Diagnosis of the condition can be difficult and can easily be missed by ultrasound scan if the pregnancy is advanced. High level of suspicion, careful clinical and ultrasound examinations are the routine means of diagnosis though C T scan and MRI can be useful. Bleeding is the single most important life-threatening complication for the mother whilst fetal malformation is one of the numerous challenges that can confront the newborn

### References

1. P baffoet al. Term Abdominal Pregnancy with Healthy Newborn: A Case Report, Ghana Med J. 2011 Jun; 45(2): 81-83.
2. Ekele BA, Ahmed Y, Nnadi D, Ishaku K. Abdominal pregnancy: ultrasound diagnosis aided by the balloon of a Foley catheter. Acta Obstet Gynecol Scand. 2005;84:701-2.
3. Nwobodo EI. Abdominal pregnancy. A case report. Ann Afr Med. 2004;3(4):195-196.
4. Badria L, Amarin Z, Jaradat A, Zahawi H, Gharaibeh A. Full-term viable abdominal pregnancy. A case report and review. Arch Gynaecol Obstet. 2003;268(4):340-342
5. Mutazedian S. Term asymptomatic abdominal pregnancy with good maternal and perinatal outcome; a case report. Ir J Med Sci. 2000;25:76-80.
6. Nwobodo EI. Abdominal pregnancy: a case report. Ann Afr Med 2004;3:195-196.
7. Gradzinskas JG. Abdominal pregnancy In: Edmond OK (ed). Dewhurst's text book of Obstetrics and Gynaecology for Postgraduates. Blackwell, Edinburgh, 1999;70
8. Martin JN, Sessams JK, Martin RW. Abdominal pregnancy: current concept of management. Obstet Gynecol. 1998;71:549-557.
9. Amritha B, Sumangali T, Priya B, Deepak S, Rai S. A rare case of term viable secondary abdominal pregnancy following rupture of a rudimentary horn. A case report. J Med case reports. 2009;3:38.
10. Jianping Z, Fen L, Qiu S. Full-Term Abdominal Pregnancy. A Case Report and Review of the Literature. Gynecol Obstet Invest. 2008;65(2):139-141.
11. Kun K, Wong P, Ho M, Tai C. Abdominal pregnancy presenting as a missed abortion at 16 weeks gestation. Hong Kong Med J. 2000;6(4):425-427.
12. Stevens CA. Malformations and deformations in abdominal pregnancy. Am J Med Genet. 1993; 47(8):1189-1195.
13. Karat LS. Viable Abdominal Pregnancy. J Obstet Gynecol India. 2007;57(2):169-170.