

Laryngeal spindle cell lipoma: case report

O Despotov MD PhD,
Department of Otorhinolaryngology,

Assoc Prof Pophrisstova MD
Department of Pathology

N P Lukwasa
Registrar, Department of Otorhinolaryngology,
University Hospital "Queen Ioanna", Sofia Bulgaria.

Key words: Larynx , spindle cell, lipoma.

This is a case report of a 24-year-old female patient who presented with a history of hoarseness of the voice, dysphagia and difficulty in breathing. A mass located on the laryngeal surface of the epiglottis was found and removed. Histology revealed a spindle cell lipoma which is an extremely rare benign tumour of the larynx.

Introduction

Spindle cell lipoma accounts for approximately 1.5% of all adipose tumours. It is a histological variant of lipoma. Unlike the usual lipoma, which occurs predominantly in women, spindle cell lipoma occurs in men between the ages of 40-60 years. Almost all spindle cell lipomas involve the superficial subcutaneous tissues of the posterior aspect of the neck, the upper part of the back, the shoulder, the extremities and the perineal region.

Lipomas of the larynx are rare with approximately 80 reported cases to date worldwide. Large benign tumours in the aperture of the larynx are uncommon, especially those on the epiglottis. Lipomas of the larynx may be either pedunculated or submucosal. Usually they arise from the aryepiglottic fold, epiglottis or true vocal cords.

Case Report

A 24-year-old female patient presented to us in April 1999 at the Department of Otorhinolaryngology at

the University Hospital "Queen Ioanna" with a history of hoarseness of the voice for the past year. Gradually she had also developed dysphagia and difficulty in breathing, especially at night.

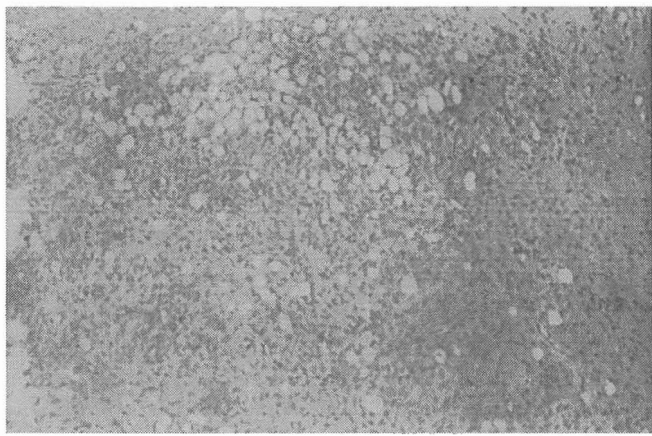
Indirect laryngoscopy revealed the presence of a pink smooth-surfaced tumour, about the size of an olive, located on the laryngeal surface of the epiglottis 0.5 cm from its free upper boarder. It was fixed and causing partial obstruction of the laryngeal inlet. A clinical diagnosis of laryngeal cyst was made.

Direct laryngoscopy was performed. A semisolid yellowish tumour with a wide base and arising from the left aryepiglottic fold was found and removed with a laryngeal punch forceps and a laryngeal hook. The true vocal cords appeared normal.

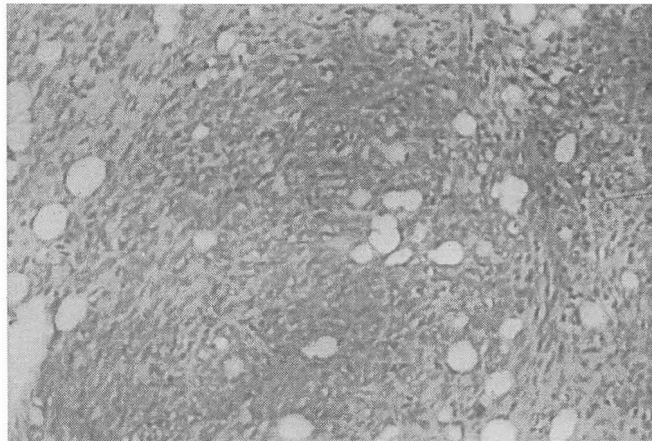
Histological examination showed a lesion composed almost entirely of spindle cells and scarce fat cells. The spindle cells were haphazardly arranged but at times they were grouped in such a way that their nuclei produced a palisading pattern. The findings were consistent with a spindle cell lipoma.

Discussion

Lipomas of the larynx are rare while spindle cell lipomas are extremely rare. These lipomas have to be distinguished from liposarcomas of the larynx. By 1995, 30 primary liposarcomas of the larynx or



Laryngeal spindle cell lipoma:
Magnification x 100



Laryngeal spindle cell lipoma:
Magnification x 200

hypopharynx had been reported in the literature. The distinction between spindle cell lipoma and the sclerosing or myxoid form of liposarcoma is based on the absence of lipoblasts, nuclear pleomorphism, mitotic activity, a diffuse plexiform capillary network and pools of mucinous material. The superficial location of a spindle cell lipoma is also in sharp contrast to the usual deep location of liposarcoma.

The treatment of spindle cell lipoma is excision. The prognosis is excellent although there is a possibility of recurrence after poor clearance of margins. For that reason prolonged follow-up is necessary.

This case is of special interest because this spindle cell lipoma presented in a young female patient when it usually occurs predominantly in elderly males.

The laryngeal location of the described histological type is extremely rare. Such a tumour is important since it may cause fatal airway obstruction as it grows or at induction of general anaesthesia.

References

- 1 Paparella , Shumrick. Otolaryngology 1973; 4: 660.
- 2 Scott - Brown's Diseases of the Ear, Nose and Throat. London1979; 4 :424.
- 3 P.M.Stell Laryngology. Butterworth and Co. 1987 ;pp 192.
- 4 Muir's Textbook of Pathology. London : 1971 ; pp 242.