

Protective role of vitamin C against lindane toxicity on the histo-architecture of the epididymis and vas deferens of male mice (*Mus musculus*)

Varsha Gautam & Vinoy K. Shrivastava*

Endocrinology Unit, Department of Biosciences, Barkatullah University, Bhopal- 462026 (M.P.), India

Abstract

We studied the protective effects of vitamin C against the toxic effects of lindane on the epididymis and vas deferens of male mice. There were four treatments: controls (untreated), lindane (20 mg/kg), lindane plus vitamin C (10 mg/kg) and vitamin C only. Lindane induced histopathological alterations in the epididymis and vas deferens characterized by a reduced epithelium with degenerative changes in the muscular layers and connective tissues, and a lack of spermatozoa in the lumen of both epididymis and vas deferens. These changes were restored towards normalcy by vitamin C. These results suggest that vitamin C has some protective role against lindane toxicity in epididymis and vas deferens of male mice.

Keywords:

Introduction

Lindane is an organochlorine insecticide and fumigant commonly used in fungicides as a treatment agent and in public health measures to control insect-borne diseases (Sahoo *et al.* 2000). It is also used in a variety of domestic and agricultural applications such as dips, sprays and dusts for livestock and domestic pets. Other uses of lindane include lotions, creams and shampoos for the control of lice and mites (scabies) in humans (Oberoi *et al.* 2007). Chronic exposure to lindane causes damage to liver, kidney, pancreas, brain, heart, lungs and the nasal mucous membranes (ATSDR 2005), and it also affects the respiratory, circulatory, excretory and immune systems (Junqueira *et al.* 1997, Koner *et al.* 1998). It has been also reported to lower gametogenic and steroidogenic activities in male and female mammals and thus induce infertility (Sumpter 1998, Willette *et al.* 1998, Sharma & Singh 2010).

Vitamin C (ascorbic acid) is an essential micronutrient required for normal metabolic functioning of the body (Salem *et al.* 2001) and it is beneficial in chronic diseases such as cardiovascular disease, cancer and cataract, probably through its antioxidant mechanism (Carr & Frei 1999). The antioxidant effects of vitamin C prevent free-radical damage in different organs, and act against the toxic, mutagenic and carcinogenic effects of environmental pollutants by stimulating liver detoxifying enzymes (Esrefoglu *et al.* 2006). Vitamin C also has defined functions in hormone secretion, gamete protection, and gonadal tissue remodeling (Davis 1991).

The present experimental investigation was carried out to evaluate the antioxidative effects of vitamin C in neutralizing histopathological alterations induced by lindane exposure in the accessory reproductive organs (epididymis and vas deferens) of male mice (*Mus musculus*).

Materials & Methods

A total of 20 adult male mice *Mus musculus* weighing about 30 ± 5 g were used. They were maintained in our departmental animal house under controlled conditions, *i.e.* 22 ± 3 °C with 14 hrs light and 10 hrs dark photoperiod. All animals were fed with mice feed and water *ad libitum*. The animals were divided into four groups of five each. The control group continued to be fed with mice feed and water *ad libitum*. The lindane-treated group received on alternate

* Author for correspondence: tel +91 755 2491828 email : vinoyks2001@yahoo.com

days an intraperitoneal injection of lindane (20 mg per kg body weight). The lindane+vitamin-treated group received on alternate days the same intraperitoneal injection of lindane along with a daily oral dose of vitamin C (10 mg per kg body weight) via their drinking water. The final group was the vitamin-treated group, that received only the same daily oral dose of vitamin C via their drinking water. Animals were sacrificed on the 31st or the 61st day of treatment by cervical dislocation, and their accessory reproductive organs (epididymis and vas deferens) quickly dissected out and fixed in Bouin's fixative. 5 μ -thick sections were then cut and stained with haematoxylin (H) and eosin (E) (Ehrlich 1886) for histopathological studies.

Results

Caput epididymis from control as well as vitamin-c only treated up to 30 and 60 days *Mus musculus* animals showed normal architecture of tubules characterized by tall columnar epithelial cell with prominent nuclei, stereocilia and large numbers of spermatozoa in the lumen (Figs.1 & 2). However, the animals exposed with lindane up to 30 days showed thickened epithelial follicular layer in the tubules with less number of spermatozoa and disrupted muscle fibers as compared to control and vitamin-c only treated animals (Fig 3). While, epididymis exposed with lindane up to 60 days, showed decreased tubular cell height and devoid of sperms in the luminal space (Fig.4). But, when the animals supplemented with vitamin-C along with lindane, some part of recovery were observed in 30 and 60 days treated groups characterized by almost normal columnar epithelial cells with large number sperms in the lumens (Figs.5 & 6). In addition to this, cauda epididymis exposed with lindane up to 30 days revealed thin walled tubules with disrupted muscle fibers and reduced number of spermatozoa as compared to control and vitamin-C only treated groups (Figs.7, 8&9). While, more severe changes were noticed in later part of the experiment characterized by thin walled epithelial layer, inhibited muscle fiber and lumens devoid of spermatozoa (Fig.10). However, when vitamin-C were supplemented with lindane up to 30 and 60 days showed some part of recovery in the epithelial cells along with visible muscle fiber, connective tissue and number of spermatozoa (Figs.11 & 12).

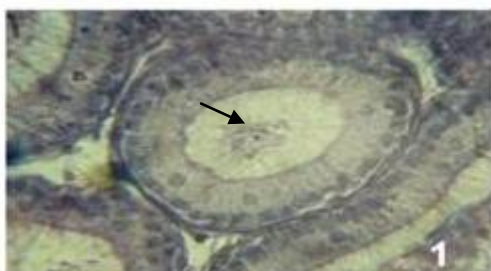


Fig. 1: Control epididymis (caput region) showing lumen lined by well-defined tall pseudostratified columnar epithelial cells with prominent nucleus. Spermatozoa are present in the lumen (arrows) (H & E x 400).

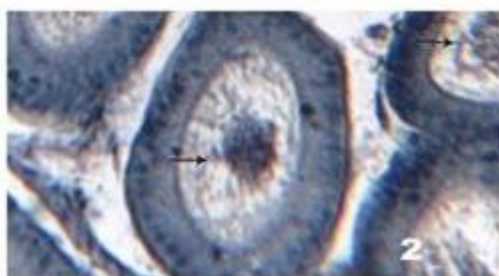


Fig. 2: Epididymis treated with vitamin C up to 30 days shows normal structural features as in the control. Lumens are largely filled with spermatozoa (arrows) (H & E x 400).

Besides this, it has been also noticed that lindane impairs the histological structure of vas deference of male *Mus musculus* characterized by degenerative changes in the epithelium layers have less stereocilia as compared to control and vitamin-c only treated animals (Figs.13, 14 & 15). These changes were more severe i.e. epithelial degeneration with pycknotic nuclei and loss of stereocilia were observed when lindane treatment was extended up to 60 days. (Fig.16). However, these changes showed recovery in epithelial layer and stereocilia when vitamin-C were supplemented along with lindane exposure up to 30 and 60 days (Fig.17 & 18).

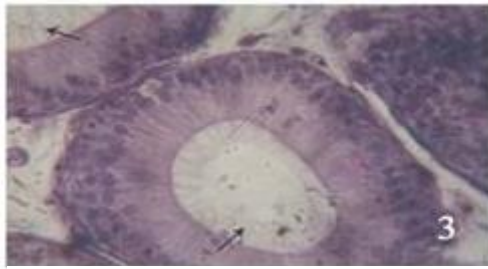


Fig. 3: Epididymis exposed with lindane up to 30 days showing thickened pseudostratified columnar epithelial cells with stereocilia and disrupted muscle fibers. Lumens are devoid of sperm (arrows) (H & E x 400).

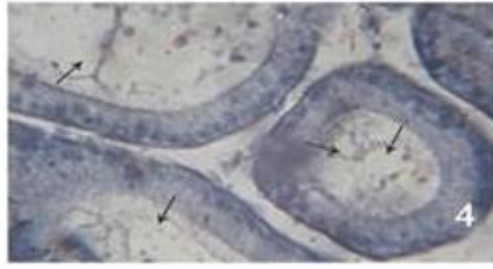


Fig. 4: Epididymis exposed with lindane up to 60 days showing decreased tubular cell height with much less connective tissue and no sperm in the lumens (arrows) (H & E x 400).

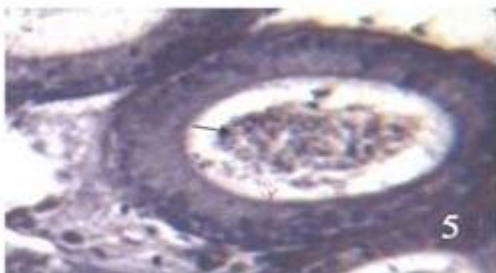

Fig. 5: Epididymis exposed with lindane + vitamin C up to 30 days shows recovery with normal architecture of tubules and pseudostratified epithelial cells. Connective tissue present between the tubules. Sperm seen in the lumen (arrows) (H & E x 400).




Fig. 6: Epididymis exposed with lindane + vitamin C up to 60 days showing recovery with normal tubular diameter. The tubular layer regains its structure. Spermatozoa are present in the lumen (arrows) (H & E x 400).

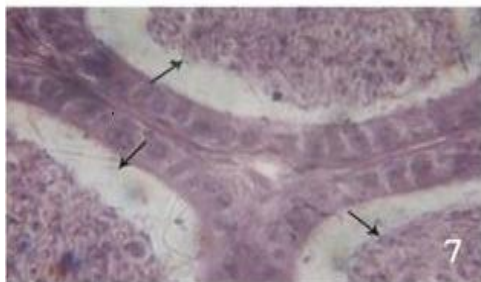


Fig. 7: Control cauda epididymis showing normal tubules lined by low pseudostratified columnar epithelium with large lumen. The ducts are surrounded by connective tissue and smooth muscle. Lumens are filled with spermatozoa (arrows) (H & E x 400).

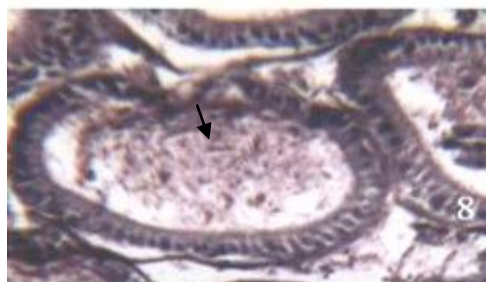


Fig. 8: Cauda epididymis treated with vitamin C for 30 days showing normal tubular structure, as in the control. Lumens are filled with spermatozoa (arrow) (H & E x 400).

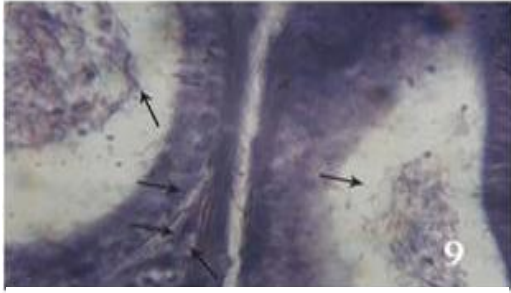


Fig. 9: Cauda epididymis treated with lindane for 30 days showing thin-walled epithelial layer with less connective tissue and fewer spermatozoa (arrows) (H & E x 400).

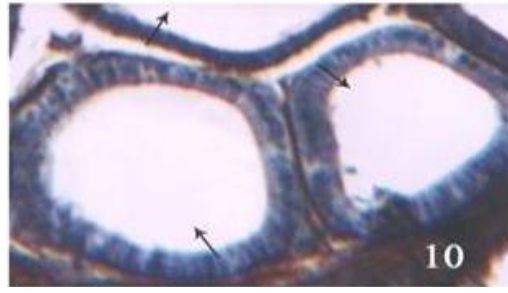


Fig. 10: Cauda epididymis treated with lindane up to 60 days showing thin-walled epithelial layer with small nuclei. No spermatozoa are seen in the lumen (arrows) (H & E x 400).

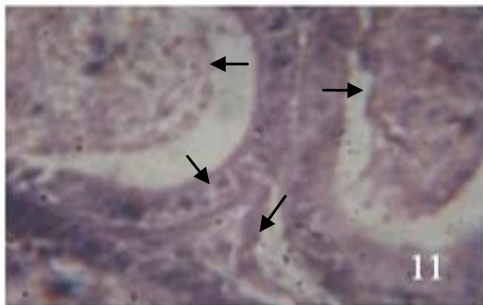


Fig. 11: Cauda epididymis exposed with lindane + vitamin C up to 30 days showing recovery of the epithelial layer, and connective tissue is visible in between the tubules. Spermatozoa are largely seen in the lumen (arrow) (H & E x 400).

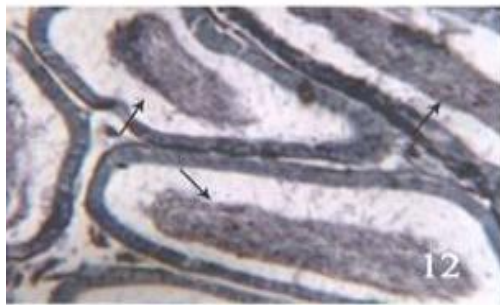


Fig. 12: Cauda epididymis treated with lindane + vitamin C up to 60 days showing recovery in the tubules and connective tissue. Lumens are filled with spermatozoa (arrows) (H & E x 400).

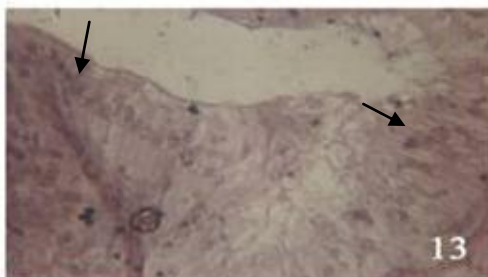


Fig. 13: T.S. of vas deferens of control mice showing well-organized epithelium with stereocilia. The epithelium is covered by a lamina propria and is surrounded by thick muscular coat (arrows). Mucosa lined by pseudostratified columnar epithelium (H & E x 400).

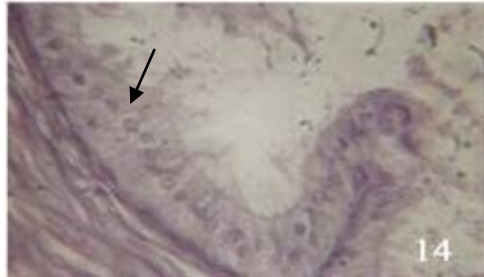


Fig. 14: Vas deferens treated with vitamin-C only for 30 days showing normal epithelium with stereocilia and well-defined nucleus (arrow) (H & E x 400).

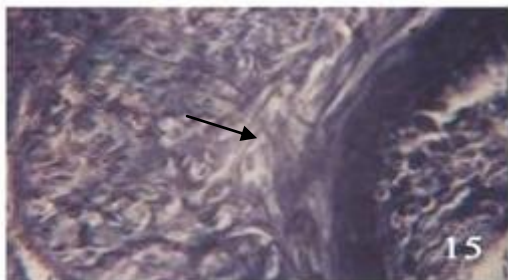


Fig. 15: Vas deferens treated with lindane up to 30 days showing degenerative changes in the epithelial layer with fewer stereocilia and pycknotic nuclei present and vacuolation in muscular region (arrow) (H & E x 400).

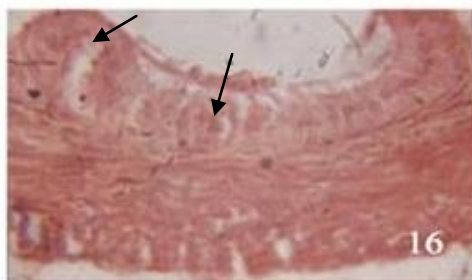


Fig. 16: Vas deferens treated with lindane up to 60 days showing degenerative changes in vassal epithelium characterized by pycknotic nuclei and loss of stereocilia. Lamina propria also showed regressive changes (arrows) (H & E x 400).

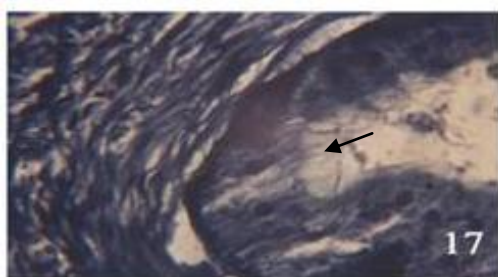


Fig. 17: Vas deferens treated with lindane + vitamin C up to 30 days showing recovery in the epithelium layer, with stereocilia (arrow) (H & E x 400).

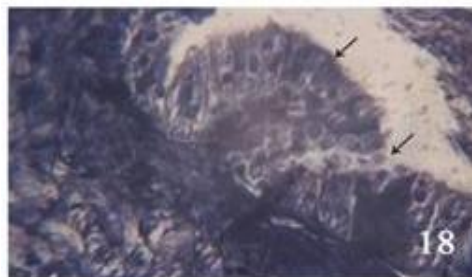


Fig. 18: Vas deferens treated with lindane + vitamin C up to 60 days showing recovery in epithelial layer with normal nuclei and stereocilia (arrows). Lumen filled with spermatozoa (H & E x 400).

Discussion

Lindane is a known endocrine disruptor in animals, and is associated with a range of serious effects on reproduction and development. These effects include testicular damage, reduced sperm production, inhibited testis steroidogenesis, atrophy of accessory sex organs, including epididymis, seminal vesicles, vas deferens, disrupted estrus cycles, delayed puberty in females, ovarian and uterine atrophy, reduced ovulation rate and infertility (Uphouse & Williams 1989, Dalsenter *et al.* 1996, Kuriyama 2005). Chitra *et al.* (2001) reported a significant decrease in the epididymal weight after lindane treatment in rats. Adult male rats treated with lindane showed atrophy of their accessory sex organs, including the epididymis, seminal vesicle and vas deferens, consistent with treatment with an anti-androgen (Chowdhury *et al.* 1993). Lindane potently inhibited contractions in other smooth muscle as well, including rat vas deferens (Gandhi & Venkatakrishna-Bhatt 1989).

The role of vitamin C in male fertility is very well documented (Dawson 1992). Supplementation of vitamin C has been reported to restore the spermatogenic process and thus fertility damaged by toxic heavy metals (Sallam *et al.* 2005), reduces oxidative stress-related effects on spermatogenesis in Cd-treated swiss mice (Acharya *et al.* 2008), protects sperm from oxidative damage and is effective in treating sperm agglutination, a condition which causes sperm to stick together (Fraga *et al.* 1991).

In our study, lindane induced marked degenerative changes in caput and cauda epididymis and the vas deferens, but these changes were prevented with vitamin C supplementation along with lindane. It has been suggested that the degenerative changes in the

epididymis and vas deferens show a decreased bioavailability and production of androgens (Mennela & Jones 1980). Thus lindane may modulate androgen levels in the blood by acting on androgen-producing cells or through the hypothalamo-hypophysial-gonadal axis. Since the epididymal epithelium structure, function and spermatozoa maturation are all androgen-dependent, hence the observed degenerative changes in the epididymis caused by lindane exposure may be due to low androgen levels in the serum. Recovery of epididymal structure after vitamin C supplementation may indicate the restoration of androgen synthesis. All these observations suggest that lindane has androgen-antagonistic functions in male *Mus musculus*. Since application of vitamin C showed normal histoarchitectural features in the epididymis and vas deferens, this indicates that vitamin C has antioxidative and protective roles against lindane toxicity.

Acknowledgements

The authors gratefully acknowledge the help and financial support of Prof. Meenakshi Banerjee (Professor and Head), Department of Biosciences, Barkatullah University, Bhopal (M.P), India..

References

- Acharya UR, Mishra M, Patro J & Panda MK (2008) Effect of vitamins C and E on spermatogenesis in mice exposed to cadmium. *Reproductive Toxicology* 25:84-8.
- Agency for Toxic Substances and Disease Registry (ATSDR) (2005) U.S. Department of Health and Human Services. Toxicologic profile for alpha-, beta, gamma- and delta-hexachlorocyclohexane. August 2005.
- Carr AC & Frei B (1999) Toward a new recommended dietary allowance for vitamin C based on antioxidant and health effects in humans. *American Journal of Clinical Nutrition* 69: 1086-1107.
- Chitra KC, Sujatha R, Latchoumycandane CC & Mathur PP (2001) Effects of lindane on antioxidant enzymes in epididymis and epididymal sperm of adult rats. *Asian Journal of Andrology* 3:205-8
- Chowdhury AR, Bhatt HV, Gautam AK & Gandhi DN (1993) Lindane induced changes in epididymis, vas deferens and seminal vesicle in rats: Histological and Pharmacological study. *Indian Journal of Physiology & Allied Sciences* 47(4):176-183.
- Dalsenter PR, Faqi AS, Webb J, Merker H-J & Chahoud I (1996) Reproductive toxicity and tissue concentrations of lindane in adult male rats. *Human Experimental Toxicology* 15:406-410.
- Davis MB, Austin J & Partridge DA (1991) *Vitamin C: its chemistry and biochemistry*. Cambridge: Royal Society of Chemistry.
- Dawson EB, Harris WA, Teter MC & Powell LC (1992) Effect of ascorbic acid supplementation on the sperm quality of smokers. *Fertility & Sterility* 58:1034-1039.
- Ehrlich P (1886) Fragekasten. *Zeitschrift für wissenschaftliche Mikroskopie und mikroskopische Technik* 3:150.
- Esrefoglu M, Gül M, Ates B & Yilmaz I (2006) Ultrastructural clues for the protective effect of ascorbic acid and N-acetylcysteine against oxidative damage on caerulein induced pancreatitis. *Pancreatology* 6:477-85.
- Fraga CG, Motchnik PA & Shigenaga MK (1991) Ascorbic acid protects against endogenous oxidative DNA damage in human sperm. *Proceedings of the National Academy of Sciences USA* 88:11003-11006.
- Gandhi DN & Venkatakrishna-Bhatt H (1989) Effects of hexachlorocyclohexane (HCH) on the contractile response induced by norepinephrine in the rat isolated vas deferens. *Pharmacology & Toxicology* 65:376-380.
- Junquera VB, Koch OR & Arisi AG (1997) Regression of morphological alterations and oxidative stress-related parameters after acute lindane-induced hepatotoxicity in rats. *Toxicology* 117:199-205.
- Koner BC, Banerjee BD & Ray A (1998) Organochlorine pesticide induced oxidative stress and immune suppression in rats. *Indian Journal of Experimental Biology* 36:395-8.
- Kuriyama K, Kitamura T, Yokoi R, Hayashi M, Kobayashi K, Kuroda J & Tsujii H (2005) Evaluation of testicular toxicity and sperm morphology in rats treated with methyl methanesulphonate (MMS). *Journal of Reproduction & Development* 51:657-667.
- Mennela MRF & Jones R (1980) Properties of spermatozoal superoxide dismutase and lack of involvement of superoxide metals ion catalyzed lipid peroxidation reactions in semen. *Biochemical Journal* 191:289-97.
- Oberoi S, Ahmed RS, Suke SG, Bhattacharya, SN, Chakraborti A & Banerjee BD (2007) Comparative effect of topical application of lindane and permethrin on oxidative stress parameters in adult scabies patients. *Clinical Biochemistry* 40:1321-4.
- Sahoo A, Samanta L & Chainy GB (2000) Mediation of oxidative stress in HCH-induced neurotoxicity in rat. *Archives of Environmental Contamination & Toxicology* 39:7-12.
- Salem MH, Kamel KI, Yousef MI, Hassan GA & EL-Nouty FD (2001) Protective role of ascorbic acid to enhance semen quality of rabbits treated with sub lethal doses of aflatoxin B1. *Toxicology* 162:209-218.

- Sallam SMA, Nasser MA, Yousef MSH, El-morsy AM, Mahmoud, SAS & Yousef MI (2005) Influence of aluminium chloride and ascorbic acid on performance, digestibility, and caecal microbial activity and biochemical parameters of rabbits. *Research Journal of Agricultural Biological Science* 1:10-16.
- Sharma P & Singh R (2010) Protective role of curcumin on lindane induced reproductive toxicity in male wistar rats. *Bulletin of Environmental Contamination & Toxicology* 84:378-84.
- Sumpter JP (1998) Reproductive effects from oestrogen activity in polluted water. *Archives of Toxicology* 20:143-49.
- Uphouse L & Williams J (1989) Diestrous treatment with lindane disrupts the female rat reproductive cycle. *Toxicology Letters* 48:21-28.
- Willete KL, Ulrich EM & Hites RA (1998) Differential toxicity and environmental fates of hexachlorocyclohexane isomers: a critical review. *Environmental Science & Technology* 2197-2207.

الملخص العربي

دور فيتامين (ج) الوقائي ضد تأثير الليندين الضار على بنية أنسجة البربخ والأسهر لذكور الفئران المنزلية (*Mus musculus*)

فارشا جوتام & فينوى شريفاستافا*

وحدة علم الغدد الصماء، قسم العلوم الحيوية، جامعة بركة الله، بوبال، الهند

الملخص العربي

تناول البحث دراسة التأثيرات الوقائية لفيتامين (ج) ضد الآثار السامة لليندين على الأسهر والبربخ للفئران المنزلية المذكورة. لقد قسمت الفئران المعالجة إلى 4 فئات وهي: فئران قياسية (غير معالجة) ، فئران معالجة بالليندين (20 ملجم / كجم) ، فئران معالجة بالليندين مع فيتامين (ج) (10 ملجم / كجم)، وفئران معالجة بفيتامين (ج) فقط. وجد أن الليندين قد تسبب في بعض التغييرات التشريحية المرضية للأسهر والبربخ تتلخص في إختزال الطبقة الطلائية وفساد طبقات العضلات والأنسجة الضامة وغياب الحيوانات المنوية في تجويف كل من البربخ والأسهر. استطاع فيتامين (ج) أن يعيد هذه التغييرات نحو الشكل الطبيعي لها ، مما يشير إلى أن فيتامين (ج) له دور وقائي ضد التأثير الضار لليندين على الأسهر والبربخ لذكور الفئران المنزلية.