

## Partial Duplication of Chromosome 8p: Report of 5 Patients and Review of Literature

Makia J Marafie, Maha M Abu-Henedi, Sawsan J Abulhasan, Amal Al-Wadaani

Kuwait Medical Genetics Centre, Maternity Hospital, Kuwait

### ABSTRACT

The partial chromosome 8p duplication is a rare syndrome and is associated with a characteristic phenotype, including multiple congenital anomalies and mental retardation of various degrees. However, different outcomes depend on the size and location of the duplicated area. We present clinical and cytogenetic data of 5 Arab patients with *de novo* inversion duplication of 8p. This report provides additional cases to the growing literature.

#### Key Words:

Chromosome duplication, multiple congenital anomalies, mental retardation, phenotype

#### Corresponding Author:

Makia J Marafie  
E-mail: mj\_marafie@yahoo.com

### INTRODUCTION

Partial duplication of short arm of chromosome 8 has been described in a considerable number of patients. The majority of these duplications had resulted from an unbalanced segregation of parental balanced translocations involving chromosome 8.<sup>1-9</sup> Carriers for this type of partial duplication are thus monosomic for other chromosomal material involved in the translocation. The phenotypic outcome depends on the amount of duplicated/deleted genetic material. Also, a considerable number of chromosome 8p rearrangements have resulted from *de novo* events; such as tandem duplications of 8p, deletions of 8p23, pericentric inversions 8 (p23 q22), and isolated duplications of 8p23.<sup>10-15</sup> However, some of these aberrations showed no

clinical manifestation.<sup>11,12-16,17</sup> In human genome large obvious paracentric inversions are frequent at a rate of 1-5/10000 individuals.<sup>18</sup> A common long human paracentric inversion polymorphism spanned >2.5Mb, was identified on chromosome 8p23.1-22. The estimated allele frequency was 21% in 50 unrelated individuals of European ancestry.<sup>19</sup> There is a common agreement that inversion duplication of 8p is a chromosomal abnormality of maternal origin that causes multiple abnormalities<sup>3-5,20-21</sup>, including developmental delay, mental retardation of various degrees with speech involvement and different craniofacial abnormalities, microcephaly and agenesis of the corpus callosum. Additional symptoms like

orthopaedic abnormalities, scoliosis and/or kyphosis, hypotonia and congenital heart defect have also been observed.

At Kuwait Medical Genetics Centre (KMGC), five patients karyotyped for multiple congenital anomalies were found to be carriers for *de novo* inversion duplication of 8p. The rearrangements were subsequently characterized by Fluorescent in situ hybridization (FISH) analyses. Their clinical findings and related cytogenetic results are discussed.

### **Case report:**

#### ***Patient 1:***

The proband was a Kuwaiti girl, the third born child to healthy, distally related parents, father being 31 years old and mother 29 years old at delivery. She had two more healthy sibs, a boy and a girl. Her mother's first pregnancy ended as abortion in the first trimester. She was delivered at 36 weeks of gestation by normal vaginal delivery due to premature rupture of membranes. She weighed 2150g and developed severe neonatal jaundice for which she was incubated for a period of 11 days and extensive blood transfusion was provided. She presented with bossing of fore head, wide anterior fontanel, micro retrognathia, high arched narrow palate, bulbous nose, everted lower lip, large ears and mega cornea. She had wide gap between first and second toes with deep planter creases. Brain CT showed partial agenesis of head of caudate nucleus. Karyotype revealed 46, XX with a *de novo* inv dup 8p (p21-p ter). Her sister's and parent's karyotypes were normal.

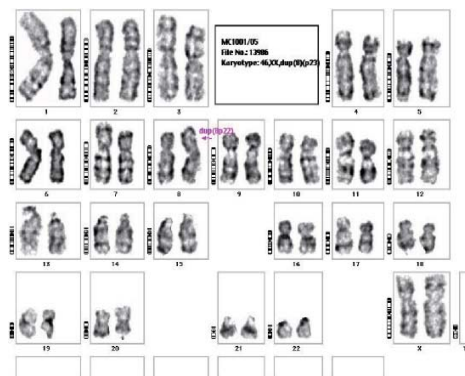
#### ***Patient 2:***

This Proband was a Kuwaiti male, the fifth born child of healthy first cousin parents, father being 39 years old, and mother 36 years old at delivery. Mother had two previous first trimester abortions for unknown causes, and one neonatal death of a girl due to pulmonary hypoplasia. He also had two normal sisters and a younger brother. He was born at term by spontaneous vaginal delivery, however, the pregnancy was complicated in its second trimester by vaginal bleeding and maternal diabetes, for which the mother was hospitalized for about one month. All birth measurements were not available. In his first year, he had mild psychomotor delay for which he received physiotherapy. At 8 years of age, he was referred to KMGC in order to evaluate his phenotypic features. His height was 122cm (<10 centile), weight 25kg (<50 centile) and OFC was 51cm (<50 centile). He presented with high forehead, brachycephaly, full cheeks, bulbous nasal tip, macrostomia with thick lower lips, down turned angles of mouth, gum hyperplasia, large fissured tongue, high arched narrow palate, large ears with flattened helix and prominent tragus. Additionally, there was pectus excavatum, generalized hypotonia, tapering fingers with atrophy of thenar and hypothenar muscles and laxity of interphalangeal joints, contracture of knee joints, bilateral talipes equino varus, undescended testis and severe mental retardation. Karyotype was 46, XY, der (8), inv dup (8p 12-22) with deletion of 8p 23p ter. Brain CT revealed agenesis of corpus callosum. Skeletal survey showed generalised osteopenia. Abdominal ultrasound was normal. Parental karyotypes were normal.

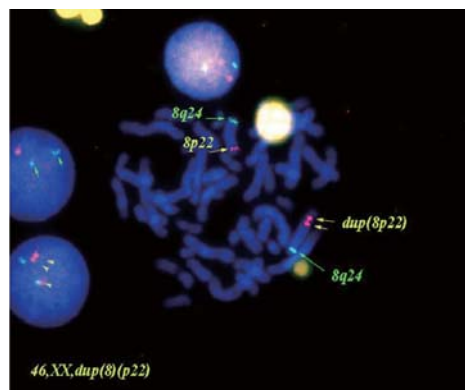
**Patient 3:**

The proband was a Syrian girl, the sixth born child to healthy, unrelated parents, mother being 32 years old and father 43 years at time of delivery. Mother had two first trimester abortions. Patient had five sisters and one elder brother. She had one uncle who died at age of 8 years due to unclarified renal disorder, and one first cousin male who had dextrocardia with VSD. She was delivered at term by spontaneous vaginal delivery and weighed 3200g. She was incubated for one week because of cyanosis, hypothermia and a small ASD which was later closed spontaneously. At 8 months, she was hospitalized because of recurrent tonic clonic seizures. Patient was referred to KMGC at age of 5 years and 3 months for assessment of her dysmorphic features, developmental delay and seizures. She weighed 18kg (50<sup>th</sup> centile), with an OFC of 46cm (98<sup>th</sup> centile). She had brachycephaly, broad forehead, bitemporal depression, hypertelorism, down slanting of palpebral fissures, low set ears, broad nasal tip, down turned thin lips, high arched palate, and short webbed neck. The hands displayed fixed flexion deformity of fifth fingers and deep palmer creases. His feet showed overriding of third and fourth toes, and deep planter creases. Other abnormalities observed were hypotonia, cutis marmorata of skin and scoliosis of spine. Psychomotor development has been severely delayed. She was on Depakine for the last six months for treatment of epilepsy. Chromosomal analysis revealed a *de novo* 46,XX dup (8) (p22) (Figure 1 and Figure 2). Her parental karyotypes were normal. EEG revealed abnormal records, skeletal survey showed generalized osteopenia with spinal scoliosis. Other

investigations were normal such as CBC, LFT, abdominal ultrasound, echocardiography, brain CT scan and MRI.



**Fig. 1:** Conventional karyotype of case 3 showing duplication of chromosome 8p22 region.



**Fig. 2:** FISH analysis on metaphase spread and interphase nuclei showed duplication of chromosome 8p22 region.

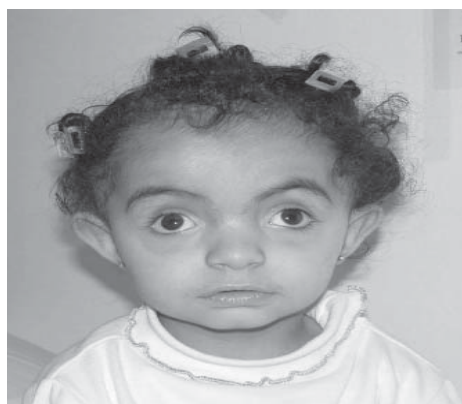**Patient 4:**

The proband was an Egyptian girl, the second born child to healthy, non-consanguineous parents. Family history was irrelevant. She has one normal elder brother. She was delivered at term following uneventful pregnancy, by caesarian section due to foetal distress. She was referred to genetics centre at age of two years for evaluation of her psychomotor retardation and her facial

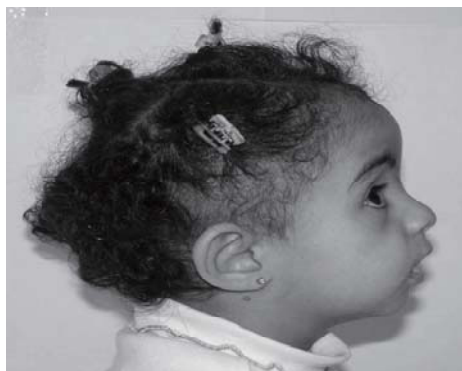features. Physical examination showed high forehead with frontal and parietal bossing, prominent eyes, micrognathia, hypertelorism, small feet with planter flexion, muscular hypotonia and delayed psychomotor milestones. Fundal examination, EEG and cardiac ultrasound were normal. However, CT of brain revealed agenesis of corpus callosum. Chromosomal and FISH analyses showed *de novo* 46XX, dup 8 (p22-23). Her parental karyotypes were normal.

#### **Patient 5:**

The proband was a Kuwaiti girl, the only born child to healthy, non-consanguineous parents, mother being 23 and father 28 years old. Family history revealed presence of a maternal brother, sister and an uncle with a congenital eye disorder of an unclarified type. She was delivered following an uneventful pregnancy at full term, by caesarian section because of prolonged labour and foetal distress. She weighed 2750g. She was referred to the genetics clinic at age of 15 months for assessment of her developmental delay. She had a length of 69cm (<5<sup>th</sup> centile), a weight of 8kg (<5<sup>th</sup> centile), and OFC of 45cm (<5<sup>th</sup> centile). On physical examination dysmorphism was noted. It included hypertelorism, downward slanting of palpebral fissures, broad nasal bridge, strabismus, curved eye brows, thin lips with flat philtrum, high arched palate, a small benign haemangioma behind right ear lobe and short neck (Figure 3A and Figure 3B). She also showed mild muscular hypotonia, umbilical hernia and deep planter creases.



**Fig. 3a:** Characteristic facial features of inversion duplication of chromosome 8p as shown in patient 5.



**Fig. 3b:** lateral view of the face in patient 5 showing a small haemangioma under right ear

Chromosomal and FISH analyses revealed a *de novo* 46,XX, inv dup (8p23) as her parents karyotype were normal. CT of brain showed defect in the shape of skull vault with no evidence of craniostenosis. Other investigations were normal such as CBC, LFT, abdominal ultrasound, echocardiography and EEG. I.Q assessment at age of 30 months showed mild mental retardation with speech delay.

## DISCUSSION

---

We have described the clinical and cytogenetic findings of 5 patients carrying *de novo* direct/or inversion tandem duplication of chromosome 8p with breakages at different segments and normal homologues. Initially, conventional chromosomal analyses with GTG banded metaphase were performed according to the standard procedure. To determine the chromosomal breakpoints more precisely, FISH technique was applied on metaphase spread and interphase nuclei using whole chromosome painting (WCP 8) and c-myc oncogene probe for locus (8q24.12-q24.13) [VYSIS]. Chromosomal analysis of all parents revealed normal karyotypes.

To date, more than 50 cases with direct or inv dup (8p), which can be either di or monocentric has been published.<sup>3-7,11,13-16,20,22</sup> The prevalence of both types is estimated to be 1/22 000-30 000 of the white western population. The majority of described cases were associated with facial dysmorphism, mental retardation, brain defects and/or developmental delay. The variability of phenotypic features associated with 8p duplication can be attributed to differences in chromosomal imbalances.

As with the previously published cases, clinical findings of our 5 patients included multiple congenital anomalies, developmental delay or mental retardation (Table 1).

A spectrum of cardiac dysfunction and serious cardiac malformations were the second most prominent feature found in some cases with 8p23.1 duplication.<sup>13,23-29</sup>

A number of authors suggested that a candidate gene/or a cluster of genes located in 8p23 region behaves as a dominant mutation that interferes with normal cardiac morphogenesis leading to a wide spectrum of congenital heart defects, including conotruncal lesions, atrial septal defects, atrioventricular canal defects, and pulmonary valve stenosis.<sup>23-25</sup> An 8p heart defect critical region was delineated, and the zinc finger transcription factor GATA4 was considered a likely candidate for these defects.<sup>26</sup> This finding was later supported by Pehlivan et al. who identified haploinsufficiency of GATA4 in several patients with interstitial deletion of 8p23.1 and congenital heart disease.<sup>27</sup> Where as Giglio and coworkers. excluded a major role of GATA4 in these congenital heart defects<sup>28</sup>, as molecular investigations of 8p deletion in their cohort of patients have narrowed the critical region for a single candidate gene associated with heart defect, to the 5-cM interval between D8S1825 and WI-8327 at chromosome 8p23. Only one of our patients (Case 3), a carrier of 46, XX, dup (8) (p22), presented with congenital hear defect (ASD) with no obvious deletion involving the critical 8p region. Some cases with inv dup of 8p may be associated with undetectable small deletions<sup>21</sup>, therefore, further molecular characterization of this region would clarify it. Follow up of other patients would identify or exclude any cardiac complications in the future.

Patient 5 showed some features of Kabuki syndrome. A recent report described a duplication of 8p22–p23.1 in multiple patients with Kabuki

**Table 1:** Clinical features and karyotypes of 5 patients with partial duplication of 8p

	<b>Patient 1</b>	<b>Patient 2</b>	<b>Patient 3</b>	<b>Patient 4</b>	<b>Patient 5</b>
	<b>6211</b>	<b>8579</b>	<b>13986</b>	<b>16237</b>	<b>18341</b>
Karyotype	46, XX, inv	46,XX, inv dup	46, XX, dup (8)	46, XX, derv 8 inv	46, XX, dup (8)
Proband	dup (8) (p21-pter)	(8) (p12-22), del p23-pter	(p22)	dup 8 (p22-p23)	(p23)
Sibs	Sister normal				
Skull	Frontal Bossing , wide anterior fontanelle	High Forehead, brachycephaly	Microcephaly, broad forehead	High Forehead, frontal and parietal bossing	Microcephaly, broad forehead
Eyes	Megalocornea	Hypertelorism	Hypertelorism, downslanting	Prominent	Arched eyebrows, strabismus, ectropion of lower eyelids,
Ears	Large ear lobes	Large malformed	Low set		Low set, prominent
Nose and nasal bridge	Bulbous nasal tip	Bulbous nasal tip	Broad		Broad
Mouth and palate	high arched narrow palate, everted lower lips	Thick lower lips, fissured tongue, carp mouth, high arched palate, gum hyperplasia	High arched palate, thin lips		High arched palate, thin upper lip
Micrognathia	+	+	-	+	+
Neck and chest	-	Pectus excavatum	Short webbed		Short neck
Hand and foot	Gap between 1 <sup>st</sup> and 2 <sup>nd</sup> Toes, deep planter creases	Hyper-extensible, long tapering fingers TEV	Flexion deformity left hand, bilateral overriding 3 <sup>rd</sup> and 4 <sup>th</sup> toes	Small feet, planter flexion	-
CNS anomalies	Agenesis of head of caudate nucleus	Agenesis of corpus callosum	Epilepsy	Agenesis of corpus callosum	-
Congenital heart anomalies	-	-	ASD	-	-
Musculoskeletal anomalies	Hypotonia	Hypotonia, TEV contracture deformity knee joints, kyphoscoliosis, generalized osteopnia	Hypotonia	Hypotonia	Hypotonia
Skin	-		Cutis marmorata		-
Genitalia	-	Undescended testis		-	-
Growth and development	Mental retardation	Mental retardation	Severe mental retardation	delayed	Mental retardation

syndrome.<sup>30</sup> However, 8p22–p23.1 duplication may not be a common mechanism for Kabuki syndrome as this suggestion was disproved later by other researchers.<sup>31–33</sup> Moreover, we have performed FISH analyses for 6 patients with Kabuki syndrome and excluded chromosomal aberration at this region (Marafie et al. unpublished data). Future molecular investigations should help to achieve a final genetic localization of this syndrome.

In keeping with previously published reports, all our 5 patients had variable degrees of craniofacial manifestations and psychomotor/mental retardation. Three of our patients were found to have agenesis of corpus callosum; patients 4 and 5 carried duplication of p23 region, while patient 2 had inv dup 8p12-22 with deletion of p23 pterminal region. This is the only patient with terminal deletion of 8p in association with the 8p duplication, which is contrary to what was reported by some authors.<sup>4,5,21,34</sup> Patient 1 had agenesis of head of caudate nucleus, she carried inv dup (8) (p21-pter). This region was suggested to be the critical region for 8p duplication syndrome.<sup>35</sup> Also, a gene for brain development might be present at 8p region.<sup>36</sup>

The phenotypic effect of isolated 8p23.1 duplication is a subject of debate. Duplication of 8p23.1-23.3 was considered an irrelevant aberration detected in a phenotypically normal male, however its relation to his oligoasthenozoospermia could not be explained.<sup>17</sup> Also, 8p23.1 duplication was reported in a mother and her

two daughters with minor clinical manifestations.<sup>8</sup> Whereas other authors emphasized its clinical implication in several patients.<sup>13,29</sup>

Furthermore, a woman carrier for inv dup (8p) with developmental anomaly and cerebral palsy developed breast cancer at age of 36 years. However, an association between breast cancer and inv dup (8) (cent-->p23.1) was excluded. On the contrary, deletion in regions 8p11-p12, 8p21-p22, and duplication of 8p12 are postulated to be associated with breast cancer.<sup>22</sup>

A group of researchers have identified a locus on chromosome 8p23, associated with maturity onset diabetes of the young, which is a subtype of diabetes defined by an autosomal dominant inheritance and a young onset. A gene at that locus may account for 30% of the cases not caused by any of 6 previously discovered genes.<sup>37</sup>

Regular follow up of these patients is recommended to exclude further medical complications. Since the parents have normal karyotype with no evidence for mosaicism, the recurrence risk is very small for these families. In conclusion, molecular cytogenetic diagnosis of structural anomalies enables accurate genetic counselling of such families.

## REFERENCES

1. Clark CE, Telfer MA, Cowell HR. A case of partial trisomy 8p resulting from a maternal balanced translocation. *Am. J. Med. Genet.* 1980; 7 (1): 21-5.

2. Brocker Vriends AH, van de Kamp JJ, Geraedts JP, Bos SE, Nijenhuis TA. Unbalanced karyotype with normal phenotype in a family with translocation (8;13) (p21;q22). *Clin. Genet.* 1985; 27 (5): 487-95.
  3. Kleczkowska A, Fryns JP, D'Hondt F, Jaeken J, Van den Berghe H. Partial duplication 8p due to interstitial duplication: Inv dup (8) (p21.1----p22). Further delineation of the phenotype from birth to adulthood. *Ann. Genet.* 1987; 30 (1): 47-51.
  4. Guo WJ, Callif Daley F, Zapata MC, Miller ME. Clinical and cytogenetic findings in seven cases of inverted duplication of 8p with evidence of a telomeric deletion using fluorescence in situ hybridization. *Am. J. Med. Genet.* 1995; 58 (3): 230-6.
  5. De Die Smulders CE, Engelen JJ, Schrandt Stumpel CT, Govaerts LC, de Vries B, Vles JS, et al. Inversion duplication of the short arm of chromosome 8: Clinical data on seven patients and review of the literature. *Am. J. Med. Genet.* 1995; 59 (3): 369-74.
  6. Feldman GL, Weiss L, Phelan MC, Schroer RJ, Van Dyke DL. Inverted duplication of 8p: Ten new patients and review of the literature. *Am. J. Med. Genet.* 1993; 47 (4): 482-6.
  7. Minelli A, Florida G, Rossi E, Clementi M, Tenconi R, Camurri L, et al. D8S7 is consistently deleted in inverted duplications of the short arm of chromosome 8 (inv dup 8p). *Hum. Genet.* 1993; 92 (4): 391-6.
  8. Gibbons B, Tan SY, Barber JC, Ng CF, Knight LA, Lam S, et al. Duplication of 8p with minimal phenotypic effect transmitted from a mother to her two daughters. *J. Med. Genet.* 1999; 36 (5): 419-22.
  9. Rodriguez Martinez L, Jimenez Munoz Delgado N, Nieto C, Martinez Carrascal A, Lopez Grondona F, Martinez Frias ML. Duplicacion invertida del brazo corto del cromosoma 8. [Inverted duplication of the short arm of chromosome 8]. *An. Esp. Pediatr.* 2001; 55 (5): 458-62.
  10. Williams L, Larkins S, Roberts E, Davison EV. Two further cases of variation in band 8p23.1. Not always a benign variant? *J. Med. Genet.* 1996; 33 (Suppl 1): A3.020.
  11. Barber JC, Joyce CA, Collinson MN, Nicholson JC, Willatt LR, Dyson HM, et al. Duplication of 8p23.1: A cytogenetic anomaly with no established clinical significance. *J. Med. Genet.* 1998; 35 (6): 491-6.
  12. O'Malley DP, Storto PD. Confirmation of the chromosome 8p23.1 euchromatic duplication as a variant with no clinical manifestations. *Prenat. Diagn.* 1999; 19 (2): 183-4.
  13. Tsai CH, Graw SL, McGavran L. 8p23 Duplication Reconsidered: Is it a True Euchromatic Variant with no Clinical Manifestation? *J. Med. Genet.* 2002; 39 (10): 769-74.
  14. Kondoh T, Takano J, Sugawara H, Ida T, Harada N, Matsumoto T, et al. Clinical manifestations of Coffin-Lowry syndrome associated with de novo 8p23 duplication. *Am. J. Hum. Genet.* 2001; 69 (4 Supplement): 293.
  15. Redha AA, Murthy DS, Kandil H, Farag TI, Usha R, al Awadi SA, et al. Partial trisomy of short arm of chromosome 8 (46,XY, inv dup (8) (p21- ->pter) in a Bedouin child with multiple congenital anomalies and mental retardation. *Indian J. Pediatr.* 1994; 61 (3): 301-6.
-



16. Krasikov N, Lamb AN, Vetrano LA, Hansen JL, Menges DE, Lytle CH, et al. Benign variant 8p23.1? *Am. J. Hum. Genet.* 1993; 53 (Suppl): A568.
17. Engelen JJ, Moog U, Evers JL, Dassen H, Albrechts JC, Hamers AJ. Duplication of chromosome region 8p23.1-->p23.3: A benign variant? *Am. J. Med. Genet.* 2000; 91 (1): 18-21.
18. Pettenati MJ, Rao PN, Phelan MC, Grass F, Rao KW, Cospser P, et al. Paracentric inversions in humans: A review of 446 paracentric inversions with presentation of 120 new cases. *Am. J. Med. Genet.* 1995; 55 (2): 171-87
19. Broman KW, Matsumoto N, Giglio S, Lese Martin C, Roseberry JA, Zuffardi O, et al. Common long human inversion polymorphism on chromosome 8p. In: Goldstein DR, editor. *Science and statistics: A festschrift for terry speed*. Ohio: IMS Lecture notes monograph series institution of mathematical statistics; 2003. p. 237-45.
20. Floridia G, Piantanida M, Minelli A, Dellavecchia C, Bonaglia C, Rossi E, et al. The same molecular mechanism at the maternal meiosis I produces mono- and dicentric 8p duplications. *Am. J. Hum. Genet.* 1996; 58 (4): 785-96.
21. Kotzot D, Martinez MJ, Bagci G, Basaran S, Baumer A, Binkert F, et al. Parental origin and mechanisms of formation of cytogenetically recognisable de novo direct and inverted duplications. *J. Med. Genet.* 2000; 37 (4): 281-6.
22. Seltmann M, Harrington P, Ponder BA. A case of inv dup (8p) with early onset breast cancer. *J. Med. Genet.* 2000; 37 (1): 70-1.
23. Marino B, Reale A, Giannotti A, Digilio MC, Dallapiccola B. Nonrandom association of atrioventricular canal and del (8p) syndrome. *Am. J. Med. Genet.* 1992; 42 (4): 424-7.
24. Hutchinson R, Wilson M, Voullaire L. Distal 8p deletion (8p23.1---8pter): A common deletion? *J. Med. Genet.* 1992; 29 (6): 407-11.
25. Wu BL, Schneider GH, Sabatino DE, Bozovic LZ, Cao B, Korf BR. Distal 8p deletion (8) (p23.1): An easily missed chromosomal abnormality that may be associated with congenital heart defect and mental retardation. *Am. J. Med. Genet.* 1996; 62 (1): 77-83.
26. Devriendt K, Matthijs G, Van Dael R, Gewillig M, Eyskens B, Hjalgrim H, et al. Delineation of the critical deletion region for congenital heart defects, on chromosome 8p23. 1. *Am. J. Hum. Genet.* 1999; 64 (4): 1119-26.
27. Pehlivan T, Pober BR, Brueckner M, Garrett S, Slauch R, Van Rheaden R, et al. GATA4 haploinsufficiency in patients with interstitial deletion of chromosome region 8p23.1 and congenital heart disease. *Am. J. Med. Genet.* 1999; 83 (3): 201-6.
28. Giglio S, Graw SL, Gimelli G, Pirola B, Varone P, Voullaire L, et al. Deletion of a 5-cM region at chromosome 8p23 is associated with a spectrum of congenital heart defects. *Circulation.* 2000; 102 (4): 432-7.
29. Kennedy SJ, Teebi AS, Adatia I, Teshima I. Inherited duplication, dup (8) (p23.1p23.1) pat, in a father and daughter with congenital heart defects. *Am. J. Med. Genet.* 2001; 104 (1): 79-80.

30. Milunsky JM, Huang XL. Unmasking Kabuki syndrome: Chromosome 8p22-8p23.1 duplication revealed by comparative genomic hybridization and BAC-FISH. *Clin. Genet.* 2003; 64 (6): 509-16.
31. Miyake N, Harada N, Shimokawa O, Ohashi H, Kurosawa K, Matsumoto T, et al. On the reported 8p22-p23.1 duplication in Kabuki make-up syndrome (KMS) and its absence in patients with typical KMS. *Am. J. Med. Genet. A.* 2004; 128 (2): 170-2.
32. Hoffman JD, Zhang Y, Greshock J, Ciprero KL, Emanuel BS, Zackai EH, et al. Array based CGH and FISH fail to confirm duplication of 8p22-p23.1 in association with Kabuki syndrome. *J. Med. Genet.* 2005; 42 (1): 49-53.
33. Sanlaville D, Genevieve D, Bernardin C, Amiel J, Baumann C, de Blois, M C, et al. Failure to detect an 8p22-8p23.1 duplication in patients with Kabuki (Niikawa-Kuroki) syndrome. *Eur. J. Hum. Genet.* 2005; 13 (5): 690-3.
34. Macmillin MD, Suri V, Lytle C, Krauss CM. Prenatal diagnosis of inverted duplicated 8p. *Am. J. Med. Genet.* 2000; 93 (2): 94-8.
35. Fan YS, Siu VM, Jung JH, Farrell SA, Cote GB. Direct duplication of 8p21.3-->p23.1: A cytogenetic anomaly associated with developmental delay without consistent clinical features. *Am. J. Med. Genet.* 2001; 103 (3): 231-4.
36. Tonk VS, Wilson GN, Velagaleti GV. Duplication 8 [inv dup(8)(p12p23)] with macrocephaly. *Ann. Genet.* 2001; 44 (4): 195-9.
37. Sung-Hoon Kim, Xiaowei Ma, Stanislaw Weremowicz, Ton-ino Ercolino, Christine Pow-ers, Wojciech Mlynarski, K. Aviva Bashan, James H. Warram, Josyf Mychaleckyj, Stephen S. Rich, Andrzej S. Krolewski, and Alessandro Doria. 2004. Identification of a Locus for Maturity-Onset Diabetes of the Young on Chromosome 8p23. *Diabetes.* 53: 1375-1384.