

A Novel Use of Hydrocolloid Dressing as a Packing Material after Functional Endoscopic Sinus Surgery

Alaa M. Abdelsamie, Mohamed A. Elsayed, Nahed M.A. Ashmawy*,

Otorhinolaryngology Department, Faculty of Medicine, Benha University, Egypt

*Corresponding author: Nahed M.A. Ashmawy, Mobile: (+20) 01212794383, E-mail: nahedmaged106@gmail.com

ABSTRACT

Background: Functional endoscopic sinus surgery (FESS) is integral in managing chronic rhinosinusitis, often necessitating postoperative nasal packing to mitigate bleeding, clotting, and adhesion risks. However, traditional packings, like Merocel, contribute to patient discomfort and pain during removal.

Objective: To compare the outcomes of using hydrocolloid dressing and merocel as a nasal packing after FESS.

Patients and Methods: This prospective, single-blinded, randomized controlled study was performed on 60 patients undergoing FESS for chronic rhinosinusitis. They were divided into two groups: one received a hydrocolloid dressing and the other received Merocel packing. Objective assessments included bleeding, adhesions, crusts, mucosal edema, and subjective symptoms, which were rated on Visual Analogue Scales (VAS) for pain, nasal obstruction, and discharge. Endoscopic evaluations were conducted postoperatively at various intervals.

Results: The hydrocolloid dressing group demonstrated lower pain scores during early follow-up visits (1 and 2 weeks) and pack removal. Subjective parameters such as discharge, and nasal blockage were generally lower in the hydrocolloid group. The incidence of bleeding was higher in the hydrocolloid group early postoperatively but increased during Merocel removal. The incidence of crust formation favored Merocel at 1 week. Adhesion scores were higher for Merocel at later intervals.

Conclusion: Hydrocolloid dressing offers a comfortable alternative to Merocel for nasal packing, reducing pain, blockage, discharge, and complications like adhesions and edema, thus promoting quicker nasal mucosa recovery. However, it carries a higher risk of early postoperative bleeding.

Keywords: Hydrocolloid Dressing; Merocele; Packing Material; Functional Endoscopic Sinus Surgery.

INTRODUCTION

Functional endoscopic sinus surgery (FESS) stands as the predominant surgical method for treating chronic rhinosinusitis. It boasts a success rate exceeding 90%, offering significant enhancements to patients' quality of life ^[1]. Despite its effectiveness, FESS is not without its challenges, including frequent post-surgical issues like bleeding and adhesion formation ^[2].

To mitigate these complications, the nasal cavity is typically filled with materials aimed at halting bleeding, minimizing clotting, reducing adhesion risk, and fostering recovery. Nevertheless, the use of detachable nasal packs can lead to increased discomfort for the patient, including pain and pressure sensations. Moreover, the process of nasal pack removal is often cited as one of the most distressing experiences associated with the surgery ^[3,4]. Hydrocolloid dressings create a seal over wounds, preserving a moist environment crucial for healing and blocking bacteria ^[5]. When these dressings absorb wound fluid, they generate a gel that may break down fibrin, aiding in the healing process, preventing secondary infections, and shielding the wound from external pollutants. These dressings are composed of a polyurethane outer layer and an inner mixture of gelatin, pectin, and carboxymethylcellulose ^[6]. This combination cultivates an optimal moist setting for the wound, manages fluid discharge, supports natural tissue removal, and acts as a defense against external pathogens ^[7].

This research aimed to assess the effectiveness of hydrocolloid dressings used as nasal packs in improving patients' subjective symptoms, achieving blood control, and enhancing wound healing after FESS.

PATIENTS AND METHODS

This prospective, single-blind, randomized controlled study was conducted with 60 patients (120 nostrils), attending Benha University Hospitals the ENT Outpatient Clinic between June 2021 and 2022.

Patients were divided into two groups: Group A: 60 nasal openings treated with hydrocolloid dressing and Group B: 60 nasal openings treated with Merocel.

The study included patients of both sexes, aged 16 to 60 years who underwent FESS due to chronic rhinosinusitis without sinonasal polyposis. Exclusion criteria encompassed patients younger than 16 years, those with unilateral chronic rhinosinusitis, a history of previous FESS, sinonasal neoplasms, systemic diseases affecting the nose, abnormal blood coagulation, and pregnancy.

Preoperative preparation:

Preoperative preparation involved evaluating patients through a comprehensive history, diagnostic nasal endoscopy, imaging (primarily CT scans of the nose and paranasal sinuses with coronal and axial views), and laboratory investigations, including CBC, coagulation profile, serum creatinine, random blood sugar, and virology tests.

Anesthesia:

For anesthesia, all procedures were performed under general anesthesia. Controlled hypotension was utilized to reduce intraoperative blood loss and optimize the surgical field visibility. Following induction and intubation, patients were positioned in an approximately 30° reverse Trendelenburg position. Additionally, a standard dose of adrenaline (1:200,000) was applied to the nasal cavity to assist in controlling bleeding.

Surgical procedure:

The surgical procedures were carried out exclusively by a senior staff surgeon to maintain consistency and avoid bias, utilizing the Messerklinger technique. The scope of the FESS was tailored to the severity of the patient's condition and the surgeon's personal methodology. Typically, the procedure involved a sequence of steps: uncinectomy and middle meatal antrostomy, anterior ethmoidectomy, posterior ethmoidectomy, and sphenoidectomy.

Following the operation, nasal packs were inserted on each side, with patients unaware of which side received the hydrocolloid pack and which the Merocele pack. These packs were strategically positioned within the middle meatus and the nasal floor to ensure comprehensive coverage (**Figure 1 and figure 2a-2b**).

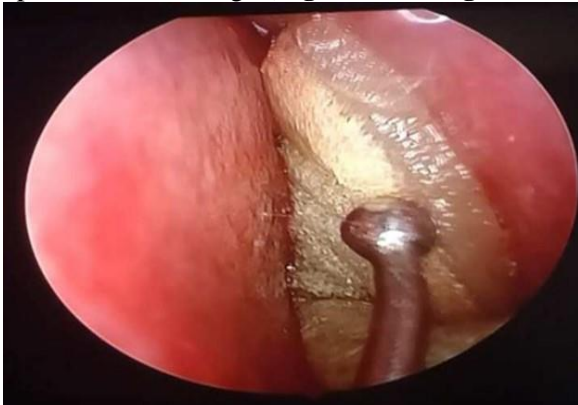

Fig. (1): Hydrocolloid in left middle meatus.



Fig. (2a): Hydrocolloid dressing.

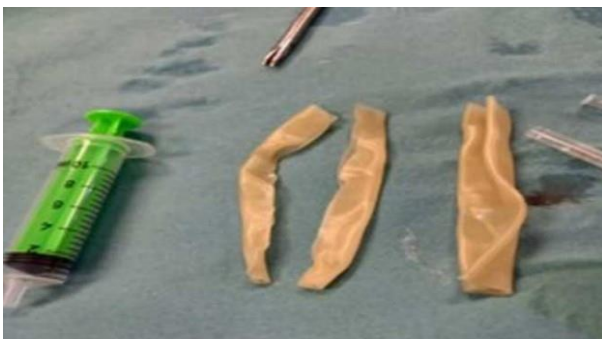

Fig. (2b): Hydrocolloid dressing.

Postoperative care and follow-Up: The nasal pack was removed the day after surgery. Postoperatively, all patients were prescribed oral antibiotics for 7 days and

an alkaline nasal wash for at least one month. Evaluations were scheduled before the removal of the pack, during the removal, and at 1 week, 2 weeks, 4 weeks, 6 weeks, and 12 weeks after surgery. The efficacy of the packs was assessed based on the degree of bleeding, hemostasis, adhesion, infection, pain, and nasal obstruction.

Assessments:

For subjective evaluation, patients compared their symptoms on both sides, rating them on a Visual Analogue Scale (VAS) from 0 to 10, with '0' indicating the absence of symptoms and '10' representing extreme severity. This evaluation covered aspects like pain, nasal blockage, and nasal discharge.

Objectively, patient recovery was assessed through endoscopic examination post-surgery. The evaluation of the surgical site included checking for bleeding, synechiae (whether obstructive or not), crust formation (classified as mild, moderate, or obstructive), and the condition of the mucosa (noting whether it was normal, mildly edematous, or severely edematous). This objective assessment was conducted using the Lund-Kennedy endoscopy scoring system.

Ethical approval:

The research received approval from the ENT Ethical Committee at the Faculty of Medicine, Benha University, and all included participants gave their informed consent prior to the study. The Helsinki Declaration was followed throughout the study's conduct.

Statistical analysis

The management and analysis of data for this study were performed using the SPSS software, version 28.0, developed by IBM in Armonk, New York, USA. The normality of quantitative data was evaluated through the Kolmogorov–Smirnov test. Depending on the distribution, quantitative data were either presented as mean values with standard deviations or as medians with their respective ranges. Categorical data were represented as frequencies and percentages. The comparison of quantitative data across the groups under study was conducted using the Wilcoxon signed-rank test, whereas categorical data comparisons were made using either the sign test or the McNemar test. All statistical evaluations were bidirectional, and P-values below 0.05 were deemed to indicate statistical significance.

RESULTS

The average age of the patients studied was 32 ± 12 years, with approximately two-thirds being females (60%). The most common clinical symptom was facial pain, experienced by 96.7% of patients (**Figure 3**).

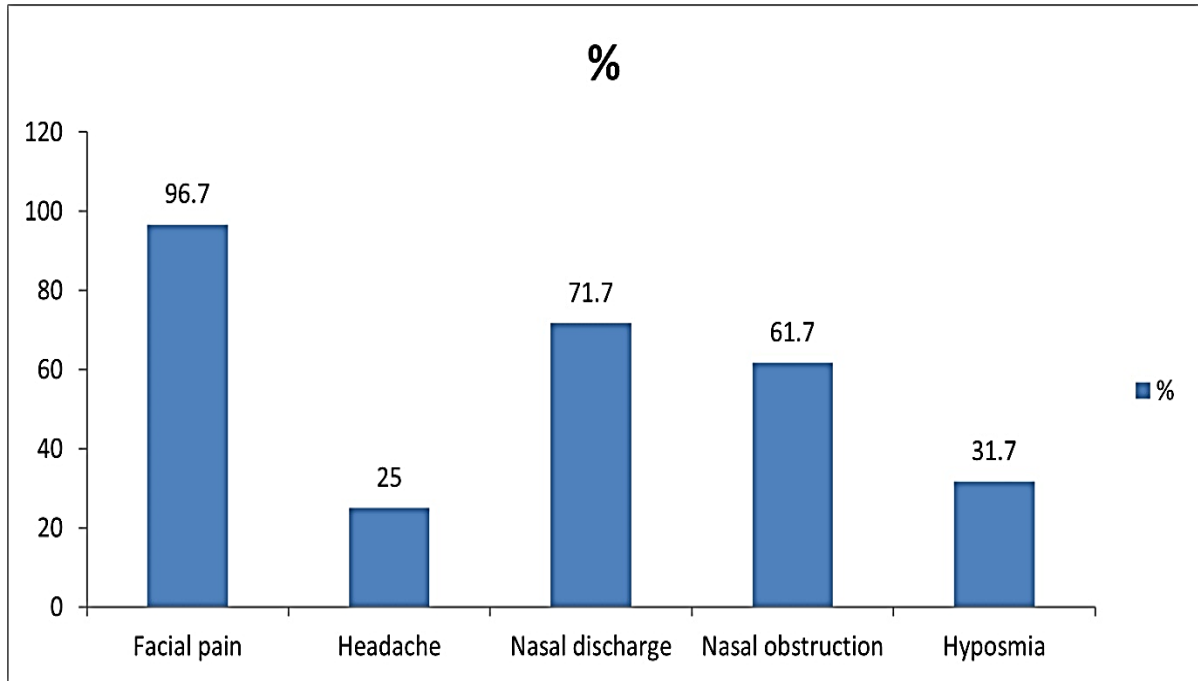


Fig. (3): Clinical presentation of the studied patients.

Group B experienced significantly more pain before removal, during removal, at one week, and at two weeks. However, no significant differences were found at four weeks, six weeks, and twelve weeks (**Table 1**).

Table (1): Pain scores in the studied groups at different follow-up times

	Group A (n = 60 nostrils)	Group B (n = 60 nostrils)	P-value
Before removal	3 (1-6)	6 (1-10)	< 0. 001*
During removal	2 (0-6)	8 (4-10)	< 0. 001*
At 1 week	0 (0-5)	4 (0-6)	< 0. 001*
At 2 weeks	0 (0-6)	2 (0-6)	< 0. 001*
At 4 weeks	0 (0-4)	0 (0-5)	0. 205
At 6 weeks	0 (0-2)	0 (0-2)	1. 0
At 12 weeks	0 (0-2)	0 (0-2)	1. 0

Data were presented as median (range), *: Significant

Nasal obstruction also significantly varied between the groups before pack removal, on the third day, at one week, and at two weeks, with no significant differences at four, six, and twelve weeks. Additionally, nasal discharge was significantly different between the groups at one week and two weeks, with no significant differences at four, six, and twelve weeks (**Table 2**).

Table (2): Nasal obstruction and discharge in the studied groups at different follow-up times

	Nasal obstruction	Group A (n = 60 nostrils)	Group B (n = 60 nostrils)	P-value
Before pack removal	No	0 (0)	0 (0)	<0. 001*
	Mild	50 (83. 3)	0 (0)	
	Moderate	10 (16. 7)	12 (20)	
	Severe	0 (0)	48 (80)	
At 3 rd day	No	4 (6. 7)	0 (0)	<0. 001*
	Mild	54 (90)	18 (30)	
	Moderate	2 (3. 3)	40 (66. 7)	
	Severe	0 (0)	2 (3. 3)	
At 1 week	No	20 (33. 3)	12 (20)	0. 004*
	Mild	40 (66. 7)	32 (53. 3)	
	Moderate	0 (0)	16 (26. 7)	
	Severe	0 (0)	0 (0)	
At 2 weeks	No	40 (66. 7)	30 (50)	0. 018*
	Mild	20 (33. 3)	20 (33. 3)	
	Moderate	0 (0)	10 (16. 7)	
	Severe	0 (0)	0 (0)	
At 4 weeks	No	48 (80)	48 (80)	1. 0
	Mild	12 (20)	8 (13. 3)	
	Moderate	0 (0)	4 (6. 7)	
	Severe	0 (0)	0 (0)	
At 6 weeks	No	50 (83. 3)	50 (83. 3)	1. 0
	Mild	10 (16. 7)	8 (13. 3)	
	Moderate	0 (0)	2 (3. 3)	
	Severe	0 (0)	0 (0)	
At 12 weeks	No	50 (83. 3)	50 (83. 3)	1. 0
	Mild	10 (16. 7)	8 (13. 3)	
	Moderate	0 (0)	2 (3. 3)	
	Severe	0 (0)	0 (0)	
Nasal Discharge				
At 1 week	No	20 (33. 3)	12 (20)	<0. 001*
	Mild	40 (66. 7)	32 (53. 3)	
	Moderate	0 (0)	16 (26. 7)	
	Severe	0 (0)	0 (0)	
At 2 weeks	No	45 (75)	30 (50)	<0. 001*
	Mild	15 (25)	20 (33. 3)	
	Moderate	0 (0)	10 (16. 7)	
	Severe	0 (0)	0 (0)	
At 4 weeks	No	48 (80)	46 (76. 7)	1. 0
	Mild	10 (16. 7)	14 (23. 3)	
	Moderate	2 (3. 3)	0 (0)	
	Severe	0 (0)	0 (0)	
At 6 weeks	No	56 (93. 3)	55 (91. 7)	1. 0
	Mild	2 (3. 3)	2 (3. 3)	
	Moderate	2 (3. 3)	3 (5)	
	Severe	0 (0)	0 (0)	
At 12 weeks	No	56 (93. 3)	56 (93. 3)	1. 0
	Mild	2 (3. 3)	2 (3. 3)	
	Moderate	2 (3. 3)	2 (3. 3)	
	Severe	0 (0)	0 (0)	

Data were presented as number (%), *: Significant.

Bleeding showed significant differences between the groups in the early postoperative period and during removal, with no significant variation at one week (**Table 3**).

Table (3): Bleeding in the studied groups at different follow-up times

	Group A (n = 60 nostrils)	Group B (n = 60 nostrils)	P-value
Early post-operative			
No	8 (13.3)	21 (35)	<0.001*
Minimal	24 (40)	35 (58.3)	
Moderate	26 (43.3)	4 (6.7)	
Severe	2 (3.3)	0 (0)	
During removal			
No	44 (73.3)	7 (11.9)	<0.001*
Minimal	12 (20)	27 (45.8)	
Moderate	4 (6.7)	25 (42.4)	
Severe	0 (0)	0 (0)	
At 1 week			
No	60 (100)	60 (100)	1.0
Minimal	0 (0)	0 (0)	
Moderate	0 (0)	0 (0)	
Severe	0 (0)	0 (0)	

Data were presented as number (%), *: Significant

Crusting significantly differed at one week and two weeks, with no significant differences at four, six, and twelve weeks (**Figure 4**).

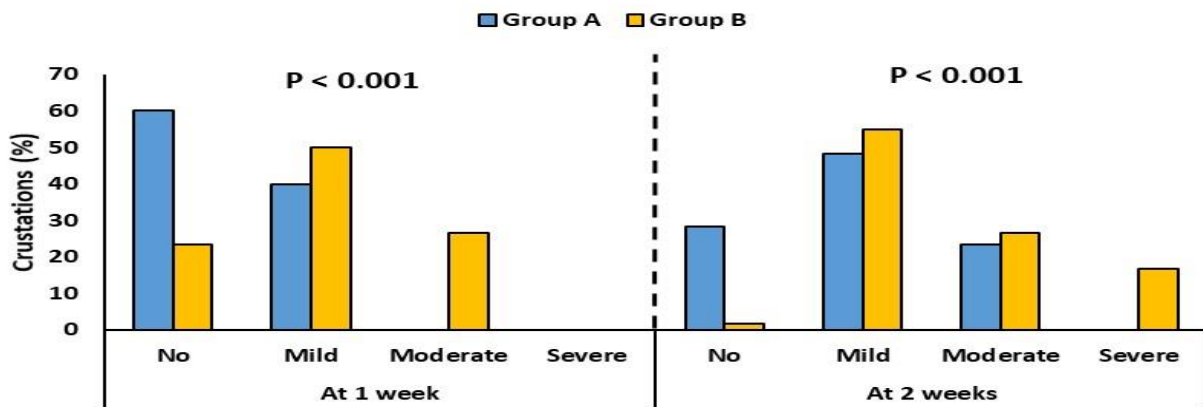


Fig. (4): Crustations in the studied groups at different follow-up times.

Synechia were significantly different at two weeks, four weeks, six weeks, and twelve weeks, with no significant difference at one week (**Figure 5**).

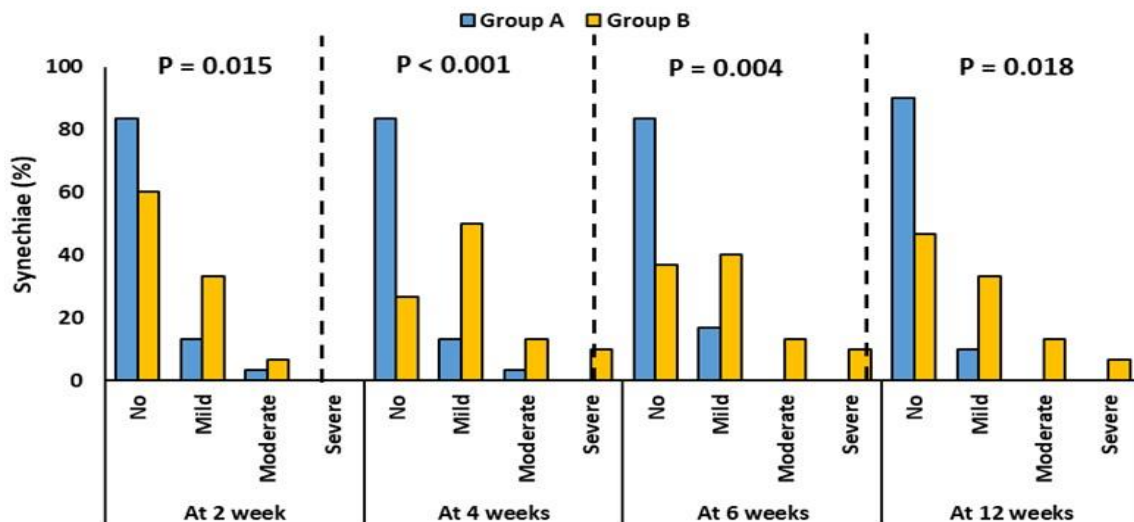


Fig. (5): Synechia in the studied groups at different follow-up times.

Mucosal edema showed significant differences at one week and two weeks, with no significant differences observed at four, six, and twelve weeks. **Table 4**

Table (4): Mucosal edema in the studied groups at different follow-up times

	Group A (n = 60 nostrils)	Group B (n = 60 nostrils)	P-value
At 1 week			
No	22 (36. 7)	13 (21. 7)	0. 004*
Mild	38 (63. 3)	31 (51. 7)	
Moderate	0 (0)	16 (26. 7)	
Severe	0 (0)	0 (0)	
At 2 weeks			
No	46 (76. 7)	30 (50)	<0. 001*
Mild	14 (23. 3)	20 (33. 3)	
Moderate	0 (0)	10 (16. 7)	
Severe	0 (0)	0 (0)	
At 4 weeks			
No	48 (80)	47 (78. 3)	1. 0
Mild	12 (20)	13 (21. 7)	
Moderate	0 (0)	0 (0)	
Severe	0 (0)	0 (0)	
At 6 weeks			
No	56 (93. 3)	55 (91. 7)	1. 0
Mild	3 (5)	3 (5)	
Moderate	1 (1. 7)	2 (3. 3)	
Severe	0 (0)	0 (0)	
At 12 weeks			
No	55 (91. 7)	54 (90)	1. 0
Mild	4 (6. 7)	5 (8. 3)	
Moderate	1 (1. 7)	1 (1. 7)	
Severe	0 (0)	0 (0)	

Data were presented as number (%), *: Significant.

Group B also had a significantly higher presence of granulation tissue at two weeks (50% vs. 20%, $P < 0.001$), four weeks (35% vs. 25%, $P = 0.031$), and twelve weeks (15% vs. 5%, $P = 0.031$) (**Figure 6**).

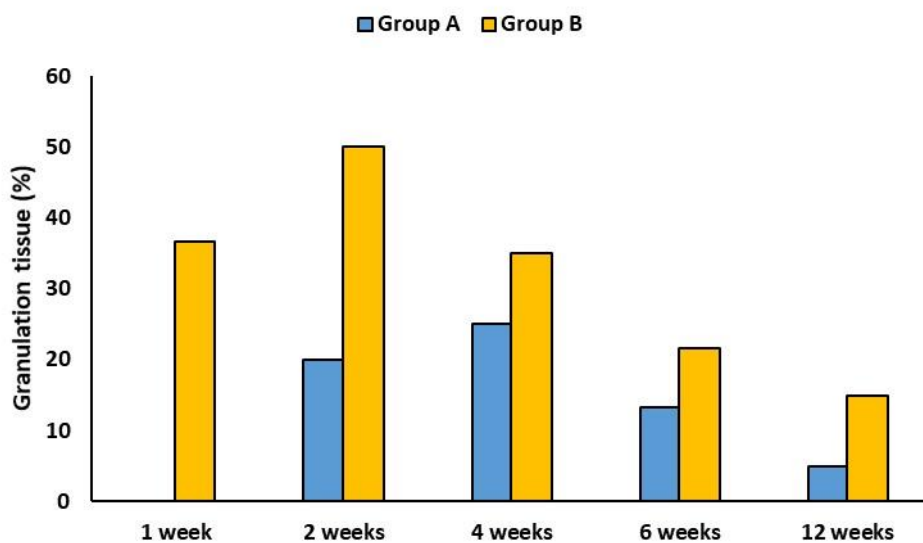


Fig. (6): Granulation tissue in the studied groups at different follow-up times.

DISCUSSION

In our research, the pain scores were notably lower on the side treated with hydrocolloid compared to the Merocele-treated side, likely due to the hydrocolloid dressing maintaining a moist environment. This moisture aids in controlling the wound exudate, supports autolytic debridement, and plays a role in pain reduction.

Similar findings regarding pain scores have been echoed in various studies, which have observed increased discomfort associated with Merocele. For instance, one study contrasted Merocele with Nasopore^[8], while another examined the differences between absorbable and non-absorbable nasal packings following nasal surgeries^[9]. A further study found no significant difference in discomfort between carboxymethylcellulose (CMC) packing and no packing^[10].

Additional research has highlighted the advantages of hydrocolloid as a dressing, noting it as less painful than paraffin gauze and conducive to quicker healing at skin graft donor sites^[11]. Our findings on subjective measures such as mucosal swelling, nasal congestion, and discharge align with a study that found hydrocolloid dressings aid in the healing of diabetic wounds^[12]. Another research applied hydrocolloid dressings to pressure ulcers and discovered they act as effective bacterial barriers while creating favorable conditions for healing and scar formation^[13].

Our analysis also indicated that early postoperative bleeding was more prevalent on the side treated with hydrocolloid (86.6% vs. 65%); however, at the time of pack removal, the Merocele group experienced a higher rate of bleeding compared to the hydrocolloid group (88.2% vs. 26.7%). By one-week post-surgery, there was no significant difference in bleeding rates between the groups. This outcome may be attributed to the absorbent nature of the dressing and its action mechanism. The hydrophilic granules in the dressing absorb wound exudate to form a hydrogel, resulting in minimal mucosal injury and, consequently, a lower incidence of bleeding. This phenomenon is common with most absorbable packs.

In one study, a pack that was pre-mixed with saline demonstrated early postoperative oozing, though it required no further intervention^[14]. Another research piece indicated that the use of biodegradable synthetic polyurethane foam (NasoPore) did not significantly lessen the risk of bleeding or discomfort for patients when compared to traditional nonabsorbable materials in a prospective setting^[15]. Further investigation found that oxidized cellulose powder was superior to polyvinyl alcohol (PVA) in managing bleeding effectively^[16].

A study evaluating the effects of four distinct nasal packing materials post-endoscopic sinus surgery discovered that NasoPore offered benefits such as an excellent hemostatic effect, greater nasal comfort, and minimal bleeding upon removal of the packing^[17].

Another study highlighted that the Cutanplast nasal pack (a gelatin sponge with potent hemostatic properties) led to significantly less pain and bleeding when compared to the use of a Merocele pack^[18].

Conversely, a study identified no significant differences in postoperative bleeding, adhesion formation, or frontal sinus openness between sides treated with fibrin sealant (FS) and those packed with Nasopore^[19]. Similarly, research showed no notable difference in outcomes between groups with Merocele packing and those without any packing^[20].

In terms of the incidence of crust formation, our findings align with a study that reported hydrocolloid dressing not only reduces the risk of infection and phlebitis from venous catheters but also enhances nursing care and patient satisfaction in cardiac surgery^[21]. Additionally, a study on the application of hydrocolloid dressing for pressure ulcers found that it serves as an effective barrier against bacteria, creating favorable conditions for wound healing and scar formation^[13]. Furthermore, another study underscored the beneficial role of hydrocolloid dressings in the healing process of diabetic wounds^[12].

Our findings on the formation of synechiae align with research^[13], which found hydrocolloid dressings were effective in pressure ulcer management, acting as a bacterial barrier and fostering an environment conducive to healing and scar formation. Similarly, another investigation^[12] showed that hydrocolloid dressings aid in the healing process of diabetic wounds.

In terms of granulation tissue development, our observations are in agreement with a study^[22] that highlighted the benefits of hydrocolloid dressing (HCD) in wound management, noting its role in enhancing patient comfort, ease of use, and the subjective improvement of scar aesthetics.

Furthermore, the application of hydrocolloid dressing for pressure ulcers, as detailed in a study^[13], reiterates its utility in creating optimal conditions for wound healing and scar formation by serving as a barrier against bacterial infection.

CONCLUSION

In conclusion, employing hydrocolloid dressing as a nasal pack presents a viable substitute for Merocele, enhancing patient comfort through the reduction of pain, nasal congestion, and discharge. Furthermore, hydrocolloid dressings seem to lessen the occurrence of adhesions, crusting, mucosal swelling, and infections. Such benefits contribute to the swift restoration of the nasal mucosa, aiding in its repair and the restoration of nasal function.

Financial support and sponsorship: Nil.

Conflicts of interest: There are no conflicts of interest.

REFERENCES

- Mandal S, Sharma A (2019):** Effect on quality of life of patients before and after functional endoscopic sinus surgery. *Indian J Otolaryngol Head Neck Surg.*, 71(3):2065-2071.
- Behiry E, Elshazly H, Abdel-Shafy I et al. (2019):** Evaluation of quality of life after Functional Endoscopic Sinus Surgery (FESS) in chronic rhinosinusitis patients in Menoufia Governorate. *EJENTAS*, 20(3):131-136.
- Bunzen D, Campos A, Leão F et al. (2006):** Efficacy of functional endoscopic sinus surgery for symptoms in chronic rhinosinusitis with or without polyposis. *Braz J Otorhinolaryngol.*, 72(2):242-6.
- Khalil H, Nunez D (2006):** Functional endoscopic sinus surgery for chronic rhinosinusitis. *Cochrane Database Syst Rev.*, 19(3):Cd004458. doi: 10.1002/14651858.CD004458.
- Stoica A, Chircov C, Grumezescu A (2020):** Nanomaterials for wound dressings: An up-to-date overview. *Molecules*, 25(11): 2699. doi: 10.3390/molecules25112699.
- Shu W, Wang Y, Zhang X et al. (2021):** Functional hydrogel dressings for treatment of burn wounds. *Front Bioeng Biotechnol.*, 9:788461. doi: 10.3389/fbioe.2021.788461
- Weller C, Team V, Sussman G (2020):** First-line interactive wound dressing update: A comprehensive review of the evidence. *Front Pharmacol.*, 11:155. doi: 10.3389/fphar.2020.00155.
- Wang J, Cai C, Wang S (2014):** Merocel versus Nasopore for nasal packing: a meta-analysis of randomized controlled trials. *PLoS One*, 9(4):e93959. doi: 10.1371/journal.pone.0093959
- Mohamady A, Gad H, El-Hamshary A et al. (2020):** Comparative study between absorbable and non-absorbable nasal packings after nasal surgeries. *Pan Arab Journal of Rhinology*, 10(2):105-117.
- Leunig A, Betz C, Siedek V et al. (2009):** CMC packing in functional endoscopic sinus surgery: does it affect patient comfort? *Rhinology*, 47(1): 36-40.
- Asgari P, Zolfaghari M, Bit-Lian Y et al. (2022):** Comparison of hydrocolloid dressings and silver nanoparticles in treatment of pressure ulcers in patients with spinal cord injuries: A randomized clinical trial. *J Caring Sci.*, 11(1):1-6.
- Takeuchi T, Ito M, Yamaguchi S et al. (2020):** Hydrocolloid dressing improves wound healing by increasing M2 macrophage polarization in mice with diabetes. *Nagoya J Med Sci.*, 82(3):487-498.
- Jin Y, Li J, Wu S et al. (2021):** Comparison of polyurethane foam dressing and hydrocolloid dressing in patients with pressure ulcers: A randomized controlled trial protocol. *Medicine (Baltimore)*, 100(2):e24165. doi: 10.1097/MD.00000000000024165
- Karkos P, Thinakaranarajan T, Goodyear P et al. (2007):** Day-case endoscopic sinus surgery using dissolvable haemostatic nasal packs: a pilot study. *Eur Arch Otorhinolaryngol.*, 264(10):1171-4.
- Shoman N, Gheriani H, Flamer D et al. (2009):** Prospective, double-blind, randomized trial evaluating patient satisfaction, bleeding, and wound healing using biodegradable synthetic polyurethane foam (NasoPore) as a middle meatal spacer in functional endoscopic sinus surgery. *J Otolaryngol Head Neck Surg.*, 38(1):112-18.
- Kastl K, Betz C, Siedek V et al. (2009):** Control of bleeding following functional endoscopic sinus surgery using carboxy-methylated cellulose packing. *Eur Arch Otorhinolaryngol.*, 266(8):1239-43.
- Duan Y, Chen G, Li Y et al. (2016):** Effects of four different nasal packing materials after endoscopic sinus surgery. *Journal of Clinical Otorhinolaryngology, Head, and Neck Surgery*, 30(9):750-753.
- Cho K, Shin S, Lee J et al. (2013):** The efficacy of Cutanplast nasal packing after endoscopic sinus surgery: a prospective, randomized, controlled trial. *Laryngoscope*, 123(3):564-68.
- Jung M, Choi C, Yu M (2017):** Comparison of the effect of aerosolized fibrin sealant and biodegradable synthetic polyurethane foam on hemostasis and wound healing after endoscopic sinus surgery: a prospective randomized study. *Int Forum Allergy Rhinol.*, 7(11):1089-1094.
- Saedi B, Sadeghi M, Farschi S (2012):** Effect of polyvinyl acetal sponge nasal packing on post-operative care of nasal polyposis patients: a randomised, controlled, partly blinded study. *The Journal of Laryngology & Otology*, 126(4):380-384.
- Han X, Li J, Zeng P et al. (2022):** Effect of the Kanghuier transparent hydrocolloid dressing in preventing central venous catheter infection and phlebitis after cardiac surgery. *Comput Math Methods Med.*, 22:4700257. doi: 10.1155/2022/4700257.
- Holmes S, Rivera S, Hooper P et al. (2022):** Hydrocolloid dressing versus conventional wound care after dermatologic surgery. *JAAD Int.*, 6: 37-42.