

CASE REPORT

A Rare Complication of Tuberculosis: Acute Paraplegia

Teoman Aydın¹, Özgür Taşpınar², Yasar Keskin¹, Müge Kepekçi¹, Meryem Güneşer¹, Adil Çamlı³, Hakan Seyithanoğlu⁴, Huriye Kızıltan⁵, Ali Hikmet Eriş⁵

ABSTRACT

BACKGROUND: *Tuberculous radiculomyelitis (TBRM) is one of the complications of neurological tuberculosis and includes cases of arachnoiditis, intradural spinal tuberculoma or granuloma, and spinal cord complications of tuberculous meningitis (TBM). Here, we report a case of TBRM which presented with acute paraplegia.*

CASE DETAILS: *Neurological examination on admission revealed flaccid paralysis, bilateral extensor plantar responses, and exaggerated deep tendon reflexes. Cerebrospinal fluid analysis showed xanthochromic fluid that contained 600 cells/mm³, 98% lymphocytes, protein 318 mg/dl and glucose 51 mg/dl (blood glucose 118 mg/dl). On thorax CT, calcified lymph nodes that were sequelae of primary tuberculosis infection was detected. Antituberculosis and intravenous corticosteroids treatment was started. Seven weeks from the onset, on-control spinal MRI myelomalacia was determined, and there was no leptomeningeal enhancement. After six weeks of rehabilitation, lower limb total motor score was increased from 0/50 to 15/50.*

CONCLUSIONS: *Tuberculous radiculomyelitis is a complication of TBM. It is rarely seen.*

KEYWORDS: *Tuberculosis, Paraplegia, Tuberculous radiculomyelitis*

DOI: <http://dx.doi.org/10.4314/ejhs.v26i4.14>

INTRODUCTION

The incidence of TB is increasing in both developing and developed countries (1). Central nervous system tuberculosis represents about 10% of extra-pulmonary tuberculosis (2). TBM is the most severe complication of tuberculosis and it has results high morbidity and mortality rates (3). TBM affects all age groups but frequently occurs in childhood and in people with untreated HIV infection (4). TBRM is one of the complications of neurological tuberculosis

and includes cases of arachnoiditis, intradural spinal tuberculoma or granuloma, and spinal cord complications of TBM (5). Here, we report a case of TBRM which presented with acute paraplegia.

CASE REPORT

A 44-year-old woman presented to our emergency department in May 2015 because of severe headache and fatigue. Her symptoms had begun a week ago.

¹Department of Physical Medicine and Rehabilitation, Faculty of Medicine, Bezmi Alem Vakıf University, İstanbul

²Department of Physical Medicine and Rehabilitation, Cınarcık State Hospital, Yalova

³Department of Internal Medicine, Faculty of Medicine, Bezmi Alem Vakıf University, İstanbul

⁴Department of Neurosurgery, Faculty of Medicine, Bezmi Alem Vakıf University, İstanbul

⁵Department of Radiation Oncology, Faculty of Medicine, Bezmi Alem Vakıf University, İstanbul

Corresponding Author: Ozgur Taspınar, Email: drozgur82@gmail.com

Her consciousness was confused and there was neck stiffness. There was no orientation and cooperation. Neurological examination on admission revealed flaccid paralysis, bilateral extensor plantar responses, and exaggerated deep tendon reflexes. There was fecal and urinary incontinence. Her condition was classified as Grade C based on American Spinal Injury Association (ASIA). Cerebrospinal fluid analysis showed xanthochromic fluid that contained 600 cells/mm³, 98% lymphocytes, protein 318 mg/dl and glucose 51 mg/dl (blood glucose 118 mg/dl). Cranial Computed Tomography (CT) scan was normal. In cranial and spinal Magnetic Resonance Imaging (MRI) with contrast, there was a leptomeningeal enhancement in the brain stem and spinal cord (Figure 1,2). HIV serology was negative. On thorax CT, calcified lymph nodes that were sequelae of primary tuberculosis infection were detected.

Antituberculosis and intravenous corticosteroids treatment was started. Seven weeks from the onset, on-control spinal MRI myelomalacia was determined, and there was no leptomeningeal enhancement. After six weeks of rehabilitation, lower limb total motor score was increased from 0/50 to 15/50.

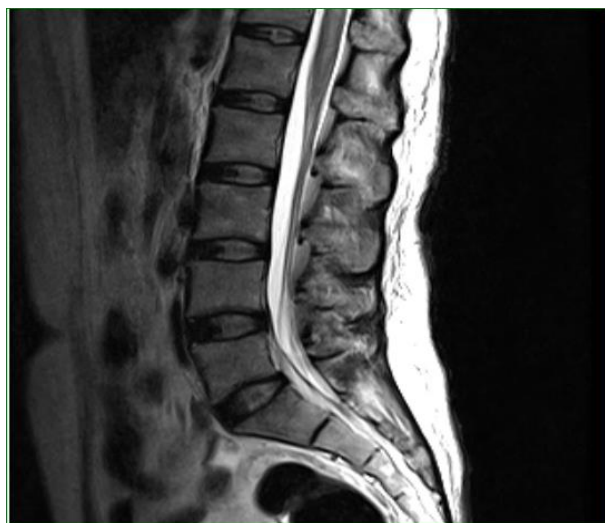

Figure 1: MRI image of lumbar spine tuberculosis myelitis

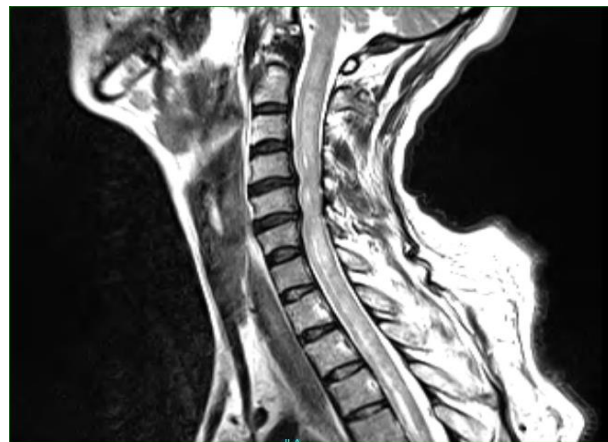


Figure 2: MRI image of cervical spine tuberculosis myelitis

DISCUSSION

Tuberculous meningitis is very important although it represents approximately 1% of all cases of tuberculosis. This is because it kills or severely disables about half of the affected people (4). Although tuberculous meningitis occurs in persons of all ages, in developed countries, it affects elderly people due to reactivated disease. However patients from areas where the prevalence of TB is still high are much younger, and meningitis is usually associated with primary infection. An increase in the incidence of extrapulmonary TB, including meningitis, is seen especially in HIV epidemic areas (6).

Patients present symptoms and signs like headache, fever, neck stiffness, seizures, cranial nerve palsies, and altered mental status. Some of the most frequent complications are hyponatraemia, hydrocephalus, stroke, cranial nerve palsies, epileptic seizures, diabetes insipidus, tuberculoma and myeloradiculopathy (7). TBRM is a rare life-threatening complication of neurological TB.

TBRM may develop in 3 different ways: a primary tuberculous lesion, a downward extension of TBM and a secondary extension from vertebral tuberculosis (1-3).

For definition of the similar clinical and pathological features of spinal tuberculosis,

patients with paraplegia, Wadia and Dastur and Wadia have suggested that the designation TBRM be used as a generic term to include cases of arachnoiditis, intradural spinal tuberculoma, granuloma and spinal cord complications of tuberculous meningitis (8).

The various pathological forms of spinal TB can cause paraplegia. In developing countries, Pott's disease is a common cause of myelopathy, causing spinal cord compression due to abscess and granulomatous tissue. The other forms of myelopathy secondary to TB include tuberculomas within the spinal cord, as well as in intra- and extradural locations, and encasing granulomatous arachnoiditis (radiculomyelopathy) with cord compression and vasculitis of spinal cord vessels (9). Vasculitis can lead to ischaemic changes as a result of arteritic occlusion of the larger arteries. Microscopically granulomatous reaction of the spinal leptomeninges are the main pathological features of the root lesions. Spinal cord atrophy, root demyelination and secondary axonal injury are the results of this pathological process (10). These forms are less common than Pott's disease (6).

In the present case, acute paraplegia was formed as a result of TBRM. Arachnoiditis (radiculomyelitis) is reported rarely, and paraplegia due to TB is often secondary to Pott's disease.

REFERENCES

1. Feng Y, Guo N, Huang F, et al. Radiculomyelitis due to atypical tuberculous infection: 4 cases report. *J Neurol Neurosurg Psychiatry*. 2011;82:585-7
2. Poon TL, Ho WS, Pang KY, et al. Tuberculous meningitis with spinal tuberculous arachnoiditis. *Hong Kong Med J*. 2003;9:59-61.
3. van Well GT, Paes BF, Terwee CB, et al. Twenty Years of Pediatric Tuberculous Meningitis: A Retrospective Cohort Study in the Western Cape of South Africa. *Pediatrics*. 2009;123:1-8.
4. Thwaites GE, van Toorn R, Schoeman J. Tuberculous meningitis: more questions, still too few answers. *Lancet Neurol*. 2013;12:999-1010.
5. Hernández-Albújar S, Arribas JR, Royo A, et al. Tuberculous Radiculomyelitis Complicating Tuberculous Meningitis: Case Report and Review. *Clin Infect Dis*. 2000;30:915-21.
6. Hristea A, Constantinescu RV, Exergian F, et al. Paraplegia due to non-osseous spinal tuberculosis: report of three cases and review of the literature. *Int J Infect Dis*. 2008;12:425-9.
7. Anderson NE, Somaratne J, Mason DF, et al. Neurological and systemic complications of tuberculous meningitis and its treatment at Auckland City Hospital, New Zealand. *J Clin Neurosci*. 2010;17:1114-8.
8. Freilich D, Swash M. Diagnosis and management of tuberculous paraplegia with special reference to tuberculous radiculomyelitis. *J Neurol Neurosurg Psychiatry*. 1979;42:12-8.
9. Pande A. Pulmonary tuberculosis presenting acutely as paraplegia: an unusual presentation. *J Family Med Prim Care*. 2013;2:294-5.
10. Moghtaderi A, Alavi Naini R. Tuberculous radiculomyelitis: review and presentation of five patients. *Int J Tuberc Lung Dis*. 2003;7:1186-90.