

Inferior vena cava injury: survival of a rare case

Isaac Okyere¹ Joseph Yorke² Eseenam A. Agbeko² Paa K. Forson³ and Joseph Bonney³

Ghana Med J 2019; 53(2): 181-183 doi: <http://dx.doi.org/10.4314/gmj.v53i2.14>

¹Cardiovascular and Thoracic Surgery Unit, Department of Surgery, School of Medicine and Dentistry, College of Health Sciences, Kwame Nkrumah University of Science and Technology/Komfo Anokye Teaching Hospital, Kumasi, Ghana

²Department of Surgery, School of Medicine and Dentistry, College of Health Sciences, Kwame Nkrumah University of Science and Technology/Komfo Anokye Teaching Hospital, Kumasi, Ghana

³Emergency Medicine Directorate, Komfo Anokye Teaching Hospital, Kumasi, Ghana

Corresponding author: Isaac Okyere

E-mail: drokyere@yahoo.com

Conflict of interest: None declared

SUMMARY

The inferior vena cava is the most commonly injured abdominal vessel and accounts for about 25% of abdominal vascular injuries. Despite improved preoperative care and operative techniques, the mortality rates for the inferior vena cava injuries are still high due to delayed presentation, inadequate or delayed fluid resuscitation, difficulty of diagnosis and technical problems in repair. A case of the inferior vena cava injury encountered after abdominal stab injury with about 4cm vertical tear of infrarenal vena cava, survived due to immediate transportation, appropriate and successful perioperative fluid and blood resuscitation, prompt surgical management with a team approach and critical post-operative surgical management.

Keywords: The inferior vena cava (IVC), stab wound, venorrhaphy, haemoperitoneum

INTRODUCTION

Traumatic injuries of the inferior Vena Cava (IVC) are quite rare because of its retroperitoneal position and the protection by several intra-abdominal structures.¹ However, the inferior vena cava is the most commonly injured abdominal vessel and accounts for about 25% of abdominal vascular injuries.² Despite improved preoperative care and operative techniques, the mortality rates for the inferior vena cava injuries are still high due to inadequate or delayed fluid resuscitation, location of the injury, difficulty of diagnosis and technical problems in repair. IVC injuries still carry a high overall mortality of up to 65%.^{3,4} Most publications on traumatic IVC injuries from Africa have been published from South Africa with no reported case from West Africa and Ghana as far as we know. We report a successfully treated infra-renal IVC Injury from a knife stab wound.

CASE REPORT

A 46-year old man presented to the Accident and Emergency Centre of Komfo Anokye Teaching Hospital (KATH) six hours after he was allegedly stabbed with a knife by armed robbers. On examination, he looked stable, conscious and alert but moderately pale, not jaundiced with SPO₂ of 92% on room air, respiratory rate of 20 breaths/min, pulse rate of 100 beats/min which was regular and of moderate volume, and a blood pressure of

90/63mmHg. He had a GCS score of 15/15. The chest was clinically clear and other systemic evaluation except the abdomen were insignificant. The abdomen was full, moderately and diffusely guarded and tender with eviscerated and bleeding small bowel through a 3cm stab wound on the left upper quadrant of the anterior abdomen wall about 2cm above and lateral to the umbilicus. In spite of initial intravenous fluid resuscitation over the first 1 hour 45 minutes on admission with 2.5L crystalloids and 1 unit of blood, the systolic blood pressure remained at 90mmHg with a urine output of 70mls, but normal urea/creatinine and electrolytes levels and a haemoglobin of 9.2g/dl. The patient was wheeled to the operating room for an emergency exploratory laparotomy.

At the operating theatre, the intraoperative findings included a 4cm vertical laceration on the infrarenal segment of the IVC with the laceration being contained within the surrounding tissue by a huge retroperitoneal hematoma, a traumatic perforation of 0.5 cm diameter on the anterior surface of the third part of the duodenum, eviscerated jejunum about 30cm in length with four (4) traumatic perforations on the anti-mesenteric border of the bowel with the most proximal perforation being 40 cm from the ligament of Trietz, and one litre haemoperitoneum with clots.

Case Report

Application of digital pressure control of the proximal and distal ends of the Infra-renal Inferior Vena Cava after opening the retroperitoneal hematoma secured control of bleeding, allowing a direct closure (Venorrhaphy) with Prolene 5/0 in a two-layered continuous repair. The duodenal perforation was repaired in a single layer with vicryl 2/0 and a jejunal resection of the traumatic jejunal perforations with end to end jejuno-jejunal anastomosis with vicryl 2/0 in a single layer were carried out.

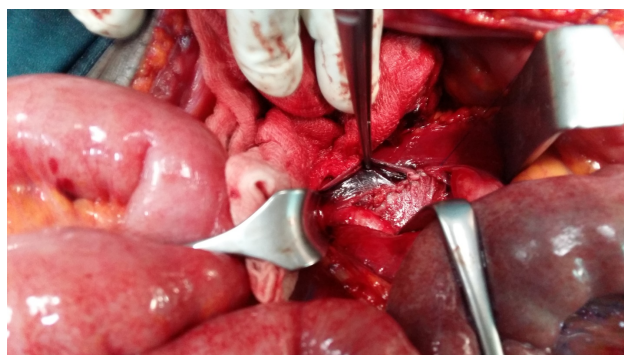


Figure 1 Infra-renal IVC repair

The post-operative period was uneventful. He received four units of blood in total within the first 12 hours on admission, one unit preoperatively and three units intraoperatively. He spent the first four postoperative days in the intensive care unit. On post-operative day two, we performed an abdominal ultrasound that revealed continuity of the IVC wall with no intraluminal thrombus (Figures 2a and 2b). The patient was anticoagulated with the low molecular weight heparin (LMWH), Enoxaparin (Clexane) 40mg daily for the first four days postoperatively and he was discharged on post-operative day 10. He has no postoperative complications eight months after surgery.

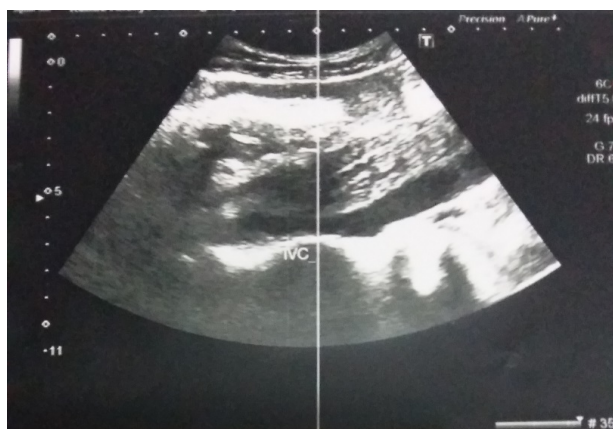

Figure 2a Ultrasonographic image of the patent Inferior vena cava

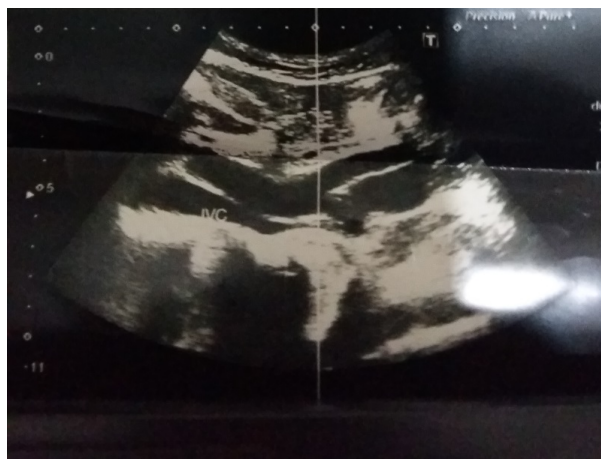

Figure 2b Ultrasonographic image of Inferior vena cava including proximal parts of common iliac veins

DISCUSSION

Anatomically, the most frequently injured segment of the IVC is the infra-renal segment (IRIVC) (39%), then the retro-hepatic segment (RHIVC) (19%), the supra-renal segment (SRIVC) (18%), the para-renal segment (PRIVC) (17%) and the supra-hepatic segment (SHIVC) (7%).^{2,5} While 30-50% of patients with IVC injury will die before getting to the hospital, another 30-50% of those who make it to the hospital will die despite surgery and efforts at resuscitation.⁶ Factors associated with high risk of mortality from traumatic IVC injury include a higher level or site of IVC injury, increasing number of associated injuries, hypotension on arrival, severe blood loss, increased transfusion requirements, a low Glasgow coma score on arrival, and the type of procedure at surgery.^{2,5,7,12} In the case of our patient, he presented with hypotension, anaemia requiring multiple transfusions and a GCS of 15/15. His survival, among other factors as noted above, may have been due to a good GCS since GCS is an independent risk for mortality in IVC injury.¹²

Operative management of IVC injuries include ligation, primary suture repair-venorrhaphy and patch cavaplasty using saphenous vein graft, autogenous peritoneo-fascial (APF) graft, synthetic graft such as Gore-Tex and Dacron.^{6,8} However every case should be evaluated on its own merit and in all circumstances the ultimate aim must be to stop the bleeding.^{8,9} Hence in the presence of a tamponade or a contained haematoma a conservative approach to management has been advocated and found to have improved survival.^{7,9} Van Rooyen et al suggest that some IVC injuries are mostly missed, never operated without any consequence.⁹ Thus, a stable haematoma may be inevitably dislodged at surgery to reveal an IVC injury that was not initially anticipated and this is the major cause of mortality during surgery, due to the inability to control the torrential haemorrhage in such situations.

Sathiamurthy and Tan report such an instance where mobilization of the duodenum in a patient with a stab wound revealed a suprarenal IVC tear that had been tamponaded by a haematoma.¹¹ Similarly, a retroperitoneal clot had tamponaded the IVC tear and was dislodged while mobilizing the third part of the duodenum to repair the perforation in our patient. Considering the size of the laceration (4cm), the nature of bleeding when the clot dislodged, the tamponade most likely prevented the patient from exsanguinating before reaching the operating room. Therefore, a good vascular access, good theatre lighting system, the use of surgical loupes and careful and efficient surgical control of bleeding under these circumstances is crucial to patient survival. In our case, we controlled the bleeding by finger pressure and a venorrhaphy.⁶ Very high survival rates have been reported for venorrhaphy, especially for infrarenal injuries probably because of the ease of access to the injury site as happened in this case.^{5,9} Outcome for injuries managed by vena cava ligation have however been mixed.^{7,12}

IVC repair with direct suturing technique can lead to narrowing of the IVC and deep vein thrombosis.¹¹ However, if the laceration is small and not extensive, direct repair is good enough and causes minimal narrowing of the IVC. Our patient sustained concomitant injuries of the duodenum and the jejunum from the penetrating injury. This correlates with the findings from Kumah and Buckman that vena cava injuries caused by penetrating mechanism are invariably associated with other intraabdominal injuries that necessitate operative management such as perforation of other hollow viscus and injury to other solid organs.^{6,10}

Longterm anticoagulation is not an absolute indication unless in a more extensive injury, when a patch repair or graft is used depending on the hemodynamic stability of the patient.² Our patient was put on venous thromboprophylaxis for the first 4 days after surgery and discontinued without any adverse events.

CONCLUSION

Penetrating injury of the inferior vena cava remains a challenging problem. High index of suspicion, early diagnosis, efficient resuscitation and prompt surgical intervention by skilled team personnel improve survival.

REFERENCES

1. Navsaria P, De Bruyn P, Nicol A. Penetrating abdominal vena cava injuries. *European journal of vascular and endovascular surgery*. 2005;30(5):499-503.
2. Kudsk K, Bongard F, Lim Jr R. Determinants of survival after vena caval injury. Analysis of a 14-year experience. *Archives of surgery*. 1984;119(9):1009-12.
3. Paul JS, Webb TP, Aprahamian C, Weigelt JA. Intraabdominal vascular injury: are we getting any better? *Journal of Trauma and Acute Care Surgery*. 2010;69(6):1393-7.
4. Hansen CJ, Bernadas C, West MA, Ney AL, Muehlstedt S, Cohen M, et al. Abdominal vena caval injuries: outcomes remain dismal. *Surgery*. 2000;128(4):572-8.
5. Huerta S, Bui TD, Nguyen TH, Banimahd FN, Porral D, Dolich MO. Predictors of mortality and management of patients with traumatic inferior vena cava injuries. *The American Surgeon*. 2006;72(4):290-6.
6. Buckman RF, Pathak AS, Badellino MM, Bradley KM. Injuries of the inferior vena cava. *Surgical clinics of North America*. 2001;81(6):1431-47.
7. Kuehne J, Frankhouse J, Modrall G, Golshani S. Determinants of survival after inferior vena cava trauma. *The American surgeon*. 1999;65(10):976.
8. Emmiler M, Kocogullari CU, Yilmaz S, Cekirdekci A. Repair of the inferior vena cava with autogenous peritoneo-fascial patch graft following abdominal trauma: a case report. *Vascular and endovascular surgery*. 2008;42(3):272-5.
9. Van Rooyen P, Mokoena T. Inferior vena cava injuries: A case series and review of the South African experience. *Injury*. 2015;46(1):71-5.
10. Kumar B, Sharma G. Traumatic rupture of the inferior vena cava: report of a case. *Australian and New Zealand Journal of Surgery*. 1973;42(4):391-3.
11. Sathiamurthy N, Tan WJ. Abdominal Stab Wound with Inferior Vena Cava Injury: *A. Med J Malaysia*. 2014;69(6):291.
12. Cudworth M, Fulle A, Ramos JP, Arriagada I. GCS as a predictor of mortality in patients with traumatic inferior vena cava injuries: a retrospective review of 16 cases. *World Journal of Emergency Surgery: WJES*. 2013;8:59. doi:10.1186/1749-7922-8-59.