

## ORIGINAL ARTICLE

# Total abdominal hysterectomy in a Tertiary Hospital in Kumasi: Indication, Histopathological Findings and Clinicopathological Correlation

N. A. Titiloye<sup>1</sup>, B. M. Duduyemi<sup>1</sup>, E. A. Asiamah<sup>2</sup>, I. Okai<sup>3</sup>, P. P. S. Ossei<sup>1</sup>, T. O. Konney<sup>4</sup>, and P. K. Fefemwole<sup>1</sup>

<sup>1</sup>Department of Pathology, <sup>3</sup>Department of Anatomy, <sup>4</sup>Department of Obstetrics and Gynaecology, Kwame Nkrumah University of Science and Technology, Kumasi. <sup>2</sup>Department of Medical Laboratory Science, University of Health and Allied Sciences, Ho, Ghana.

Hysterectomy is the commonest gynaecological surgery worldwide. Hysterectomy is commonly performed in our centre with request for post-surgical histological confirmation of pathologies. The aim of this study was to review all the hysterectomy specimens sent to our department between 2008 and 2016 and analyse the histological diagnosis in them and clinically correlate with the indications for the surgery. We reviewed retrospectively request forms, histological reports and slides generated for all cases of hysterectomies sent to our department for histological assessment between 2008 and 2016 totalling 1086. All the data obtained were analysed using SPSS 21. A total number of 1086 cases of hysterectomies with or without salpingo-oophorectomy were received in our department. The age range was 15 to 85 years with age group 40 to 49 years constituting 57.7% of cases. The commonest indication for surgery was uterine mass which constituted 722 cases (66.42%) and an obvious uterine mass was found at grossing in 737 cases (66.48%) while histology revealed uterine leiomyoma in 861 cases (79.28%) constituting the largest proportion of histological diagnosis. Other indications for surgery include dysfunctional uterine bleeding, suspected ovarian and cervical malignancy and peri-partum haemorrhage. Histological diagnoses confirmed wide range of lesions within the endometrium, cervix, fallopian tubes and ovaries. There was correlation between clinical indication and histological diagnosis up to 90.2% of all cases. Our data confirmed hysterectomy specimens with or without salpingo-oophorectomy as a common histological specimen in our laboratory, with peak age of patients in the fifth decade. Leiomyoma was the commonest histological finding and other wide ranges of pathologies were seen with strong positive ( $r = 0.98$ ) correlation between pre-operative indication and the final diagnosis.

*Journal of Medical and Biomedical Sciences (2018) 7(1), 22 - 28*

**Keywords:** Hysterectomy, gynaecological, histological, pathologies, salpingo-oophorectomy.

## INTRODUCTION

The commonest gynaecological surgery worldwide is hysterectomy, and it is also the second most common surgical procedure in USA (Wu *et al.*, 2007; Graves 1990). The hallmark for diagnosis of lesions from hysterectomy specimen is histology therefore hysterectomy specimen forms a significant proportion of all surgical specimen submitted for histopathological analysis in various tertiary teaching

hospitals worldwide including West Africa (Adelusola and Ogunniyi 2001; Samaila *et al.*, 2009).

Previous study conducted at a tertiary teaching hospital in Ghana put the prevalence rate of hysterectomy at the Department of Obstetrics and Gynaecology in the Institution as 7.8% with uterine fibroid as the leading indication (Takyi 2013). Severe uterine bleeding from uterine rupture was the cause of peripartum hysterectomy in a study from same institution in Ghana (Kwame-Aryee *et al.*, 2007).

Our hospital is a tertiary medical institution serving the Northern part of Ghana and there has not been

Correspondence: Dr Nicholas Akinwale Titiloye, Department of Pathology, KNUST, Kumasi, Ghana.

E-mail: [Waleht2000@yahoo.com](mailto:Waleht2000@yahoo.com), or [nicholastitiloye.sms@knust.edu.gh](mailto:nicholastitiloye.sms@knust.edu.gh)

## Abdominal hysterectomy in a tertiary hospital

Titiloye *et al.*,

a previous study on hysterectomy specimens from our centre.

This study reviewed all cases of hysterectomy received at the Pathology Department of our hospital between 2008 and 2016 for histological analysis, with the aim of determining the indication for surgery, the pattern of lesions in the specimen and clinical correlation of these lesions with the indication.

### MATERIALS AND METHODS

#### Study design

The design of the study was a retrospective study. We abstracted all cases of Hysterectomy with or without salpingo-oophorectomy received at the Department of Pathology of our hospital over a period of 9 years (2008-2016).

#### Data collection

The histology case identification numbers were used to retrieve the histology request forms, histology reports and slides from the department archive. Clinical demographic details were abstracted from the request forms and histopathological diagnoses from the reports. A review of the histopathological diagnoses was done using the retrieved slides. Where the slides were not available, sections were cut from archival blocks.

The Department received hysterectomy specimens from the in-patients within the hospital and other health facilities within the Northern part of Ghana during the study period. Specimens were transferred to the Department in 10% neutral buffered formalin (NBF) and Haematoxylin and Eosin (H & E) stained sections from the sampled specimens were produced for histological diagnosis by pathologists.

Cases whose request forms, histological reports and slides could not be retrieved were excluded from the study.

#### Statistical analysis

Data obtained were analysed using SPSS 21. Data was presented as chart, mean (standard deviation), number and percentage. Pearson correlation coefficient were used for association between gross mor-

phology and histology with clinical indication. P-value < 0.05 was considered statistically significant.

### RESULTS

A total number of 1086 Hysterectomy specimens were studied. This is 2.68% of all histological cases within the study period. The cases were performed on patients from age range of 15-85 years with a mean age of 45.96 (SD 9.24).

Most of our cases (57.7) were in the age range 40 – 49 years; while age range of 30 -39 years and 50 -59 years recorded 16.3% and 19.43% respectively. The frequency at ages lower than 30 and ages above 60 were low (Figure 1).

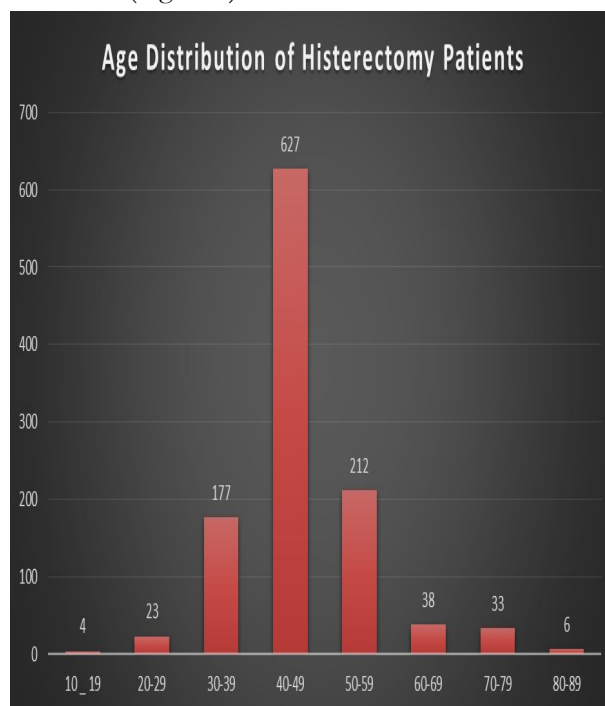


Figure 1: Age distribution of Hysterectomies

Total abdominal hysterectomy with bilateral salpingo-oophorectomy have the highest frequency of occurrence accounting for 434 cases (39.96%) while hysterectomy without removal of adnexa structures were seen in 380 cases (34.99%). Hysterectomy with unilateral adnexa structures were seen in 272 cases; with left salpingo-oophorectomy constituting 166 cases (15.29%) and right salpingo-oophorectomy constituting 106 cases (9.76%).

The commonest indication for hysterectomy was uterine mass which constituted 722cases (66.48%). Dysfunctional uterine bleeding was the indication in 101 cases (9.3%) while ovarian tumours and cervical tumours were indication in 109 cases (10.03%) and 31 cases (2.85%) respectively. Other indications including peripartum haemorrhage, post- partum haemorrhage and placenta disorders as documented in table 1.

**Table 1: Clinical indications for Hysterectomy**

Indication for Removal	Frequency (%)
Dysfunctional Uterine Bleeding	101 (9.3%)
Uterine mass	722 (66.42%)
Perforation	5 (0.46%)
Post-Partum Haemorrhage	9 (0.86%)
Utero Vagina Prolapse	23 (2.11%)
Ovarian Tumours	109 (10.03%)
Adenomyosis/ Endometriosis	15 (1.38%)
Cervical Tumours	31 (2.85%)
Ectopic Gestation & Other Fallo- pian Tube pathologies	6 (0.56%)
Placenta disorders	7 (0.64%)
Non specific	15 (1.38%)
Not Stated	43 (39.59%)

**Data presented as frequency (percentage)**

Findings from gross morphology of Hysterectomy specimens showed that majority of the cases presented with macroscopically obvious lesions in various tissues of the specimen. Masses were seen in the uterus in 737 cases (67.87%), while 283 cases (26.06%) appeared normal morphologically. Lesions seen in the endometrium, cervix, left and right fallopian tubes and ovaries were as depicted in Table 2.

The histological diagnosis from various structures of the hysterectomy specimens were as depicted in tables 3.1-3.4. Uterine leiomyoma is seen in 861 cases (75.41%). In many of the cases it co-existed with other lesions; Leiomyoma co-existing with Adenomyosis were seen in 83 cases (7.64%). Adenomyosis without leiomyoma and malignant tumours of the endometrium were seen in 33 cases (3.03%) and 41 cases (3.78%) respectively. The frequencies of other lesions in the endometrium were as listed in table 3.

The histological diagnosis from various structures of the hysterectomy specimens were as depicted in

**Table 2: Gross morphology description of lesions in Hysterectomy specimens**

Organ part	Mass	Other lesions (No Mass)	Normal	Rupture/others	Missing Data
Uterus	737 (67.9%)	41 (3.8%)	283 (26.1%)	9 (0.8%)	16 (1.5%)
Endometrium	86 (7.9%)	88 (8.1%)	745 (68.6%)	0 (0.0%)	167 (15.4%)
Cervix	54 (5.0%)	13 (1.2%)	934 (86.0%)	3 (0.3%)	82 (7.6%)
Left Fallopian Tube	18 (3.0%)	5 (0.8%)	546 (92.5%)	0 (0.0%)	31 (5.3%)
Left Ovary	127 (21.2%)	7 (1.2%)	422 (70.3%)	0 (0.0%)	44 (7.3%)
Right Fallopian Tube	12 (2.2%)	6 (1.1%)	507 (95.7%)	1 (0.2%)	14 (2.6%)
Right Ovary	110 (20.4%)	26 (4.8%)	372 (68.9%)	0 (0.0%)	32 (5.9%)

**Data presented as frequency (percentage)**

## Abdominal hysterectomy in a tertiary hospital

Titiloye *et al.*,

tables 3.1-3.4. Uterine leiomyoma is seen in 861 cases (75.41%). In many of the cases it co-existed with other lesions; Leiomyoma co-existing with Adenomyosis were seen in 83 cases (7.64%). Adenomyosis without leiomyoma and malignant tumours of the endometrium were seen in 33 cases (3.03%) and 41 cases (3.78%) respectively. The frequencies of other lesions in the endometrium were as listed in table 3.

**Table 3: Histology and frequency of lesion in the corpus uteri and endometrium**

Variants	Frequency
Normal	125(11.51%)
Leiomyoma	736(67.77%)
Adenomyosis + Leiomyoma	83(7.64%)
Adenomyosis	33(3.04%)
Endometrial Adenocarcinoma	43(3.96%)
Utero-Vaginal Prolapse	4(0.37%)
Placenta Accreta	3(0.28%)
Chronic Endometritis	12(1.10%)
Uterine Ruptured	2(0.18%)
Perforated Uterus	2(0.18%)
Endometrial Hyperplasia	26(2.39%)
Product of Conception	11(1.01%)
Endometrial Polyp	6(0.55%)
Total	1086(100%)

### Data presented as frequency (percentage)

In the cervix squamous cell carcinoma were seen in 12 cases (1.1%). The frequencies of other lesions of the cervix were listed in table 4.

**Table 4: Histology and frequency of lesion in the cervix**

Variants	Frequency
Normal	600(54.95%)
Cervicitis	273(25%)
Leiomyoma	1(0.09%)
Squamous Metaplasia	43(3.94%)
Squamous cell carcinoma	12(1.10%)
Cervical Polyp	5(0.46%)
Metastasis	3(0.27%)
Adenocarcinoma	2(0.18%)
UV Prolapse	4(0.37%)
CIN-1 with HPV	4(0.37%)
CIN-II	2(0.18%)
CIN-III	4(0.37%)
Not removed surgically or not reported	139(12.73%)

### Data presented as frequency (percentage)

One thousand and eight seven (1087) cases (95.35%) of left and right fallopian tubes were normal while salpingitis was seen in 38 cases (3.33%). The frequency of other fallopian tubes lesions which include product of conception, metastasis and primary lymphoma were as depicted in table 5.

**Table 5: Histology and frequency of lesion in the fallopian tubes**

Variants	Left Fallopian Tube	Right Fallopian Tube
Total	600(100%)	540(100%)
No lesion	568(94.67%)	519(96.11%)
Salpingitis	23(3.83%)	15(2.78%)
Fibrosis	1(0.17%)	1(0.19%)
Metastasis	6(1%)	2(0.37%)
Product of conception	1(0.17%)	2(0.37%)

### Data presented as frequency (percentage)

Seven hundred and twenty-nine (729) cases (63.95%) of left and right ovaries had no lesion in them. Corpus luteum and other benign cysts of the ovaries were seen in 313 cases (27.46%). Primary tumours of the ovary which is composed of benign

**Table 6: Histology and frequency of lesion in the ovaries**

Variants	Left Ovary	Right Ovary
Total	600(100%)	540(100%)
No lesion	376(62.7%)	353(65.4%)
Corpus luteum cyst	84(14%)	60(11.11%)
Cyst (Uncategorized)	91(15.17%)	78(14.44%)
Endometriosis	2(0.33%)	1(0.19%)
Metastatic tumour	5(0.83%)	5(0.93%)
Ovarian abscess	2(0.33%)	0(0%)
Primary tumours	40(6.67%)	43(7.96%)
Primary tumours		
Benign		
Mature teratoma	7	6
Fibroma	4	5
Brenner tumour	5	4
Mucinous cystadenoma	2	0
Malignant		
Granuloma cell tumour	7	5
Serous adenocarcinoma	14	15
Lymphoma	1	2
Malignant mixed tumour	0	1
Mucinous adenocarcinoma	0	5

### Data presented as frequency (percentage)

## Abdominal hysterectomy in a tertiary hospital

Titiloye *et al.*,

and malignant tumours were seen in 51 cases (4.9%) and 50 cases (4.80%) respectively. The commonest benign tumour is mature teratoma with 11 cases (0.96%) and serous adenocarcinoma was the commonest malignant tumour with 29 cases (2.54%). Metastases to the ovary were seen in 10 cases (0.88%). Other tumours were as depicted in table 6.

As shown in table 7, data from the gross morphology and histology showed strong correlation with clinical indication in 0.98 and 0.99 of the cases respectively.

in contrast to 30 to 60 years age group in other studies (Orji *et al.*, 2002; Samaila *et al.*, 2009).

Various clinical indications for hysterectomies in the current study include dysfunctional uterine bleeding, uterine mass, uterine perforation and ovarian tumours. Uterine mass as the commonest clinical indication (66.42%) in our study was similar to most other studies worldwide. Yadav *et al* in a series from India found a pre-operative diagnosis of uterine mass in 48.57% of cases while Samaila *et al.* (2009) found uterine fibroid to be 61.8% of cas-

**Table 7: Correlations of gross morphology and histology with clinical indication**

		Histological Diagnosis	Clinical Indication	Gross Morphology
Histological Diagnosis	Pearson Correlation	1	0.983**	0.980**
	Sig. (2-tailed)		0.000	0.000
	N	1082	1082	1082
Clinical Indication	Pearson Correlation	0.983**	1	0.994**
	Sig. (2-tailed)	0.000		0.000
	N	1082	1082	1082
Gross Morphology	Pearson Correlation	0.980**	0.994**	1
	Sig. (2-tailed)	0.000	0.000	
	N	1082	1082	1082

**\*\* Correlation is significant at the 0.01 level (2-tailed)**

## DISCUSSION

Despite the unfavourable cultural disposition to hysterectomy in our environment, hysterectomy specimens still remain one of the major sources of specimens submitted for histological appraisal in most pathology department as seen worldwide (Wu *et al.*, 2007; Ezem and Otubu 1981). This current study showed about 3% which is comparable to previous studies (Samaila *et al.*, 2009). The fifth decade peak age for patients and the other patterns seen in other age groups in our study have been documented in many previous studies (Suad *et al.*, 2017; Khunte *et al.*, 2017).

Women offered hysterectomy more often have completed their family and have uterus related disorder in which hysterectomy is therapeutic. In our series, hysterectomy was not performed for any woman as a form of family planning. Our study showed patient age spectrum of 15-85 years suggesting that hysterectomies were done for reproductive and non-reproductive age groups based on wide indications

as in Zaria. This is in agreement with many other studies conducted on black Africans (Roberts and Okunlola 2005; Onwuhafua *et al.*, 2005; Gupta *et al.*, 2009). The lesions from gross morphologic appearance showed uterine mass as the predominant lesion similar to histological diagnosis. It is of note that adenomyosis was seen more in association with uterine fibroid than occurring alone. Most of our patients were multiparous with large percentage at the reproductive age groups and studies have shown that unlike endometriosis which has been strongly associated with a form of sub-fertility, adenomyosis seen in hysterectomy specimen of patients in the fifth decade lack such association (Campo *et al.*, 2012; De Ziegler *et al.*, 2010; Lee *et al.*, 1984).

Endometrial carcinoma was the histological diagnosis in 43 cases constituting the second largest histological lesions in the uterus. Our study also found other variable diagnosis which may have been indication for the hysterectomy or co-exist with other

## Abdominal hysterectomy in a tertiary hospital

Titiloye *et al.*,

lesions in the hysterectomy specimen. However, 125 cases of the uterus were considered normal. Though the uterus may not contain lesions, malignancies seen in the ovary, cervix and rarely the fallopian tubes may warrant hysterectomy. In our series, primary ovarian malignancies were seen in 28 cases and metastases to the ovaries were seen in 5 cases. Cervical malignancies were seen in 17 cases with 15 cases being squamous cell carcinoma, 2 cases of adenocarcinoma and 3 were direct spread and metastasis from the endometrium.

Other non-neoplastic conditions including UV prolapse and complications of obstetrics procedure which include uterine perforation, placenta accreta and uterine rupture were histological diagnoses for hysterectomies in this series. Also this series documented a wide array of lesions which were accidental findings co-existing with the main pathology. Few hysterectomy specimens constituting less than 10% had no pathology in them. Our data on the cases with pathologies and without pathology were similar to other studies by Adelusola and Ogunniyi (2001) and Samaila *et al.* (2009).

Our study showed a strong correlation between clinical impression and pathological diagnoses similar to previous studies (Gupta *et al.*, 2010; Khunte *et al.*, 2017; Rather *et al.*, 2013).

### CONCLUSION

Hysterectomies with or without salpingo-oophorectomy were common histological specimen in our laboratory, often done for women in the fifth decade. The commonest indication and pathological diagnosis was leiomyoma. Our histopathological diagnoses showed strong correlation with clinical indication in most of the cases.

### COMPETING INTERESTS

The authors declare that they have no competing interests.

### ACKNOWLEDGEMENTS

We acknowledge the staff of Department of Pathology, Komfo Anokye Teaching Hospital, Kumasi for their assistance in this study and we appreciate

Messrs William Ayibor and Flynt Ntim; and Miss Henrietta Somuah-Frempong for assisting in data collection.

### REFERENCES

- Adelusola K. and Ogunniyi S. (2001) Hysterectomies in Nigerians: histopathological analysis of cases seen in Ile-Ife. *The Nigerian post-graduate medical journal* 8(1), 37-40.
- Campo S, Campo V, Benangiano G (2012). Adenomyosis and infertility; Review article. *Obstetrics and Gynaecology International*. Article ID 786132, 8 pages
- De Ziegler D, Borghese B, Chapron C. Endometriosis and infertility : Pathophysiology and management. *The Lancet*. 2010; vol 376, no 9742, pp. 730-738
- Ezem BU, Otubu JA. Hysterectomy in the Hausa/fulani population in Nigeria. *Int J Gynecol Obstet* 1981;19:145-9.
- Graves, EJ. National Center for Health Statistics, National Hospital discharge survey: annual summary, 1990. *Vital Health stat* (13). 1992, No.112. DHHS Publication PHS 92-1773.
- Gupta G., Kotasthane D. and Kotasthane V. (2010) Hysterectomy: a clinico-pathological correlation of 500 cases. *The Internet Journal of Gynaecology and Obstetrics* 14(1), 1-5.
- Khunte V., Kulkarni V., Gahine R. and Indoria C. (2017) Spectrum of Lesions in Hysterectomy Specimens and their Preoperative Correlation. *J Cont Med A Dent*. 5(3), 29-33.
- Kwame-Aryee RA, Kwakye AK, Seffah JD. Peripartum Hysterectomy at Korle – Bu Teaching Hospital: A review of 182 consecutive cases. *Ghana Med J*. 2007 Sep; 41 (3); 133-138
- Lee NC, Dicker RC, Rubin GL, Ory HW. Confirmation of the pre-operative diagnosis of hysterectomy. *American Journal of Obstetrics and Gynaecology*. 1984; Vol 150, no 3, pp. 283-287
- Onwuhafua PI, Oguntayo A, Adesiyun G, Obineche I, Akuse JT. Audit of hysterectomies in a group of private hospitals in Ka-

## Abdominal hysterectomy in a tertiary hospital

Titiloye *et al.*,

- duna City, Northern Nigeria. *Trop J Obstet* 2005; 22:16-20
- Orji EO, Ndububa VI, Ajenifuja KO. Elective Hysterectomy in Obafemi Awolowo University Teaching Hospitals Complex, Ile-Ife. *Sahel Med J* 2002;5:125-8.
- Rather GR, Gupta Y, Bardhwaj S. Pattern of lesions in Hysterectomy specimens: a prospective study. *JK Science*. 2013; vol 15, no 2.
- Roberts OA, Okunlola MA. Abdominal hysterectomy for benign gynaecological conditions at Ibadan, Nigeria. *Trop J Obstet Gynaecol* 2005; 22:125
- Samaila MO , Adesiyun AG , Agunbiade OA , Mohammed-Duro A. Clinico-Pathological assessment of hysterectomies in Zaria. *European Journal of General Medicine*, Vol. 6, No. 3, July-September, 2009, pp. 150-153
- Suad MO. Zaid, Mazen Abood Ben Thabet. Histopathological findings in hysterectomy specimens: A retrospective study. *Middle East Journal of Internal Medicine*. 2017; Vol 10, issue 3
- Takyi C. Indications and outcome of Hysterectomy at Korle Bu: A five year review. Thesis (MPH) – University of Ghana. 2013; [Http://197.255.68.203/handle/123456789/5249](http://197.255.68.203/handle/123456789/5249)
- Wu J.M., Wechter M.E., Geller E.J., Nguyen T.V. and Visco A.G. (2007) Hysterectomy rates in the United States, 2003. *Obstetrics & Gynecology* 110(5), 1091-1095.



ISSN 2026-6294

