

Solitary Giant Neurofibroma of the Scalp with Calvarial Defect in a Child

N. J. Ismail, B. B. Shehu, A. Lasseini, I. Hassan, D. J. Shilong, J. O. Obande, S. M. Sahabi¹

Department of Neurosurgery, Regional Center for Neurosurgery and ¹Department of Pathology, Usmanu Dan Fodiyo University, Teaching Hospital Sokoto, Nigeria

INTRODUCTION

Neurofibromas are tumors of nerve sheath origin and may arise from Schwann cells, perineural cells^[1] or fibroblasts.^[2] They present as individual tumors or in syndromic forms with multiple skin nodules, as in neurofibromatosis and other phakomatosis. They have many similarities with schwannomas. The differentiating features include the presence of neurofibromatosis, nerve fibers, and more myxoid tissue (Antoni B tissue) in the neurofibromas, while schwannomas are well capsulated, have a more compact matrix, a fascicular formation, and the presence of Antoni A cells. In the head and scalp, they are more common in the intracranial compartment, or are present as plexiform neurofibromas. Malignant degeneration with skull erosion is more common in intracranial lesions and those with background neurofibromatosis.^[2] Giant forms of neurofibromas of the scalp with erosion of the skull have been documented in adults, and most have been in patients with neurofibromatosis or pre-existing plexiform neurofibromas. Such an occurrence is rare in children. We report a case of a five-year-old boy, managed in our center, with a giant frontal neurofibroma with an extensive calvarial defect.

CASE REPORT

A five-year-old boy presented with seven weeks' history of a progressive and painless swelling on the right side of the forehead and temporal region [Figure 1]. There was no headache, vomiting, visual impairment or seizures. Examination revealed a young boy who was not pale, not febrile, had no lymphadenopathy, and there were no other features of neurofibromatosis or phakomatosis. He had a huge irregular right frontal swelling, which was painless,

Address for correspondence: Dr. N. J. Ismail, Department of Neurosurgery, Regional Center for Neurosurgery, Usmanu Dan Fodiyo University Teaching Hospital Sokoto Nigeria. P. M. B. 2370 Sokoto, Nigeria. E-mail: nasirujismail@yahoo.co.uk

ABSTRACT

Neurofibroma of the scalp are mostly multiple as part of neurofibromatosis or other phakomatosis. *De novo* solitary types are less common and rarely erode the skull, unlike the intracranial counterpart. Skull erosion has been reported in adults with longstanding plexiform neurofibromas. We report a giant neurofibroma on the scalp of a five-year-old boy, managed in our center. Although this condition is a rare entity, it should be anticipated and the treatment strategy should include repair of the skull defect.

Key words: Calvarial defect, scalp neurofibroma, solitary giant

DOI: 10.4103/2006-8808.63718

with no skin discoloration over it; it measured 16 × 12 cm. It was multinodular with cystic and solid components, not tender, but fixed to the underlying skull [Figure 1]. The Glasgow coma score was 15, there were no cranial nerve deficits; the motor and sensory systems were also normal.

Laboratory investigations, which included hemogram, electrolytes, and urea, were all within normal limits. A preoperative brain CT scan showed a huge right frontal extradural, which was enhanced with contrast administration. It had a central cystic component and a

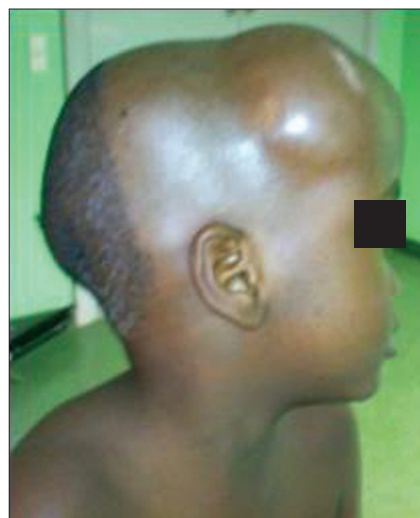

Figure 1: Preoperative picture of the patient showing a large right frontal swelling

large right frontotemporal skull defect [Figure 2].

The surgical plan was tumor excision and cranioplasty. The finding at the surgery was a huge soft yellowish extradural tumor, with a cystic (necrotic) center. The tumor invaded the frontotemporal bone and extended to the right ethmoidal sinus and the right temporalis muscle. The area of bony defect measured 10 cm in the widest diameter. Most of the tumor was, however, adherent to parts of the frontal bone. The patient had a one-stage bifrontal craniectomy, with complete tumor excision, and frontal cranioplasty with antibiotic impregnated methyl methacrylate [Figure 3]. He required blood transfusion intraoperatively. Postoperative treatment included intravenous ceftriaxone 100 mg/Kg

daily, intravenous Phenobarbitone 5 mg/Kg eight hourly, and intramuscular pentazocine 1 mg/Kg eight hourly, for 48 hours. He had an uneventful recovery and was discharged home 11 days after surgery.

The histology report was consistent with neurofibroma [Figure 4]. Brain C T scan at eight weeks post surgery showed no residual tumor [Figure 5]. His neurological status remained normal.

DISCUSSION

Giant solitary neurofibroma of the scalp without neurofibromatosis is rare. Only three cases have been reported thus far. All were adults, with a slow rate of tumor growth, over decades.^[3] To our knowledge no case

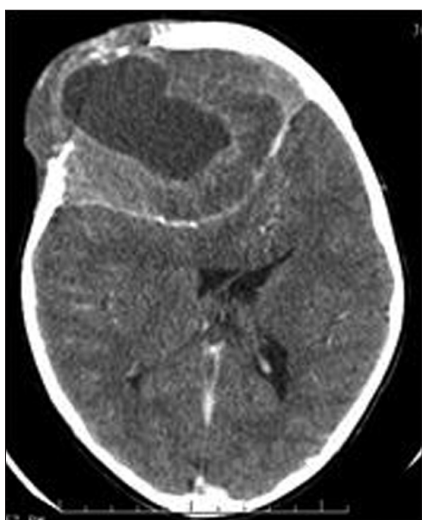


Figure 2: Preoperative contrast brain CT scan showing a huge extra axial tumor in the right fronto-temporal area, destroying the frontal bone with intra- and extracranial components. There is effacement of the ventricles



Figure 3: Intraoperative image of the patient. After removal of the pathological bone, cranioplasty with molded methyl methacrylate was carried out. The implant was kept in place with a Nylon 1 suture

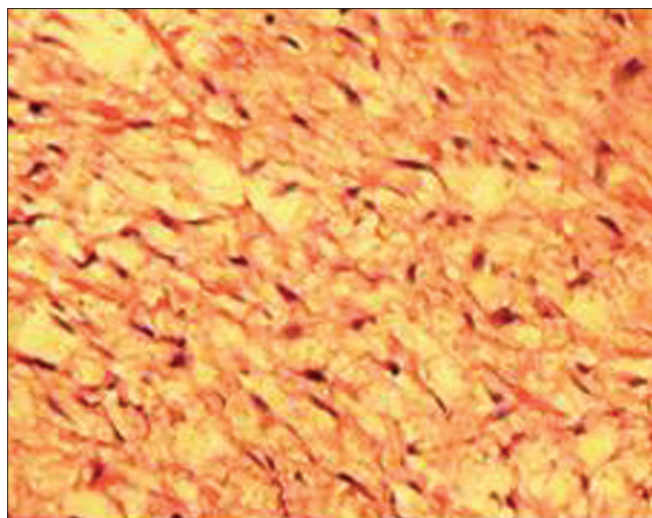


Figure 4: Photomicrograph of the excised tumor, showing neurofibroma composed of proliferating spindle-shaped cells, with dark nuclei, disposed in a loose myxoid background. The cells have wavy to comma-shaped nuclei and moderate cytoplasm. *H and E stain, x400*

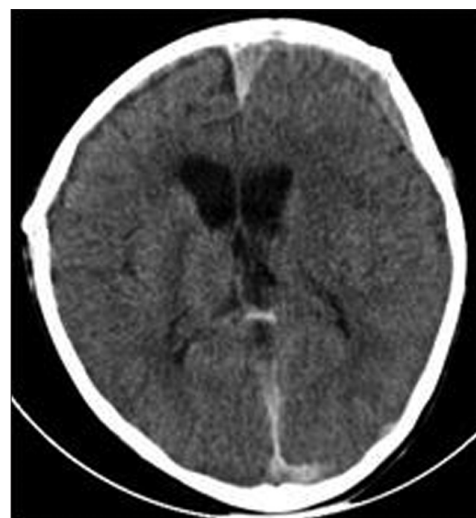

Figure 5: Postoperative contrast CT at eight weeks. There was re-expansion of the right frontal lobe

has been reported in children. The rapidity of growth and site of occurrence were the other peculiarities of this case. Fibrous dysplasia was a differential because of the patient's age and location of the tumor. It was reported that rapid growth could have been because of acute, severe bleeding into the tumor^[4] or malignant transformation, but that was not the case in this patient. Most reported cases of giant scalp neurofibroma were in Japanese literature.^[3-5] The reason for this was not clear because of the relatively small number of cases reported.

Skull defect with sclerotic margins was more suggestive of an underlying neurogenic tumor;^[6] this patient had a rather osteolytic bony lesion. Bone defects were more common in neurofibroma associated with neurofibromatosis.^[3-5] The patient did not present with any stigmata of neurofibromatosis. The extent of the tumor and involved parts of the brain could be assessed with a contrast CT scan and magnetic resonance imaging. The clinical diagnosis might still be difficult and could only be confirmed by histology.

The aim of the surgery was a one-stage complete tumor excision together with the involved bony margins, and cranioplasty, to protect the brain in areas of bone loss. The cosmetic outcome was also important, as the child had reached school age. There may be a need for a second surgery in the future, to put an appropriately sized implant, when the child has reached adulthood. This is because the methyl methacrylate implant has a fixed size and will not adapt with the changing morphology of the child's skull as the brain grows. Other materials that have been used

to close the skull defects include split autogenous calvarial bone, rib grafts, and titanium plates.

The single stage procedure allowed the patient to undergo only one procedure rather than two or more staged operations and avoided several weeks with a substantial bony defect. One potential problem was the possibility of tumor regrowth in the presence of an implant. This was avoided by obtaining a good margin of resection. Regular follow up with imaging studies was necessary to identify any early recurrence.

Solitary giant neurofibroma of the scalp is rare in children. Clinical diagnosis may be difficult, and surgical treatment must be individualized. Regular radiological studies during follow-up visits are necessary to detect early recurrence.

REFERENCES

1. Claus EB, Persing JA. Scalp tumors. Youman's neurological surgery. Philadelphia: Saunders; 2004. p. 1409-18.
2. Kenneth WL, Bone I. Intracranial tumors-pathological classification. Neurology and neurosurgery illustrated. Edinburgh: Churchill Livingstone; 2004. p. 301.
3. Aya T, Mitsuo H, Tadashi O, Hideyuki T, Masamitsu K, Aiko S. Giant neurofibroma of the scalp: case report. *Jpn J Plast Reconstr Surg* 1999;42:413-7.
4. Tsutsumi M, Kazekawa K, Tanaka A, Ueno Y, Nomoto Y, Nii K, *et al.* Rapid expansion of benign scalp neurofibroma caused by massive intratumoral haemorrhage: Case report. *Neurol Med Chir (Tokyo)* 2002;42:338-40.
5. Nakasu S, Nakasu Y, Natsuda I, Handa J. Giant neurofibroma of the occipital scalp associated with lambda defect. *No To Shinkei* 1981;33:181-5.

Source of Support: Nil, Conflict of Interest: None declared.