

Case Article

# Diagnostic Imaging of Non-Accidental Injury and Percutaneous Foreign Bodies: A Case Report from Zambia

Ernest Chanda<sup>1</sup>, Oswald Bwanga<sup>2</sup>, Suzyo Mutambo<sup>3</sup>, Mike Chisha<sup>3</sup>, Mulewa Mulenga<sup>4</sup>, John Musuku<sup>5</sup>

<sup>1</sup>Cancer Diseases Hospital, Radiotherapy Department, Lusaka, Zambia

<sup>2</sup>Midland University Hospital Tullamore, Radiology Department, Co. Offaly, Ireland

<sup>3</sup>University Teaching Hospital, Radiology Department, Lusaka, Zambia

<sup>4</sup>Surgery Department, Arthur Davison Children's Hospital, Ndola, Zambia

<sup>5</sup>University Teaching Hospitals (UTH) Children Hospital, Lusaka, Zambia.

## ABSTRACT

This case report presents the role imaging played in the diagnosis and surgical removal of multiple percutaneous foreign bodies in a 5-year-old child who presented with non-accidental injuries (NAI) to medical facilities in Zambia. Children are commonly referred for imaging with suspected accidental foreign bodies, but percutaneous foreign bodies due to NAI are rare. NAI is caused due to child physical abuse and therefore, imaging plays a major role in the diagnosis and provision of legal evidence. In this case report, conventional radiography (plain film) of a skeletal survey was the first imaging requested. This was supplemented with a computed tomography (CT) scan of the thorax and abdomen. Lastly, foreign bodies were removed under the guidance of the image intensifier. Although, the cases of NAI reported and presented in medical facilities in Zambia are rare, this case shows that physical child abuse is practiced in our communities. Thus, radiographers and radiologists should pay attention to such cases during imaging and reporting, respectively.

## INTRODUCTION

Medical imaging plays an important role in the diagnosis of non-accidental injuries (NAI) to abused children. The World Health Organization (WHO) <sup>1</sup>defines child abuse as all forms of physical and emotional ill-treatment, sexual abuse, neglect, and exploitation that results in actual or potential harm to the child's health, development, or dignity. The Juveniles Act of the Laws of Zambia <sup>2</sup> defines a "child" as "a person who has not attained the age of sixteen years". Child abuse is a global problem that is deeply rooted in cultural, economic, and social practices.<sup>3</sup> Research shows that child abuse is most likely to occur in communities with high rates of poverty and no or less systems that support child protection. <sup>3</sup> Globally, 300 million children aged between 2 and 4 years suffer from physical punishment and/or physiological violence at the hands of their parents, relatives, or caregivers.<sup>1</sup> NAI remains the leading cause of morbidity and mortality in children.<sup>4</sup> Therefore, it is important to protect children from such forms of abuse to maintain their wellbeing.

There are two responsibilities of radiographers regarding NAI: diagnostic imaging and the protection of children.<sup>5-7</sup> Radiographers provide imaging services for clinical evidential purposes in NAI cases. This role is well documented in the

**Keywords:** Child abuse, Foreign body, Fracture, Imaging, Non-accidental injury, Zambia

---

### Corresponding author:

Ernest Chanda,  
Cancer Diseases Hospital, Radiotherapy Department,  
Lusaka, Zambia  
E-mail: e.chanda75@gmail.com

literature.<sup>5,7,8</sup> However, the second role of child protection is less documented.<sup>5</sup> Literature also shows that the knowledge of radiographers regarding child protection is inadequate.<sup>5,7</sup> It should be mentioned that radiographers may be the first healthcare professionals to suspect child abuse. For example, during imaging whilst the child is undressed, inappropriate bruising may be noted which may be inconsistent with the clinical history presented to the medical practitioner and written on the radiology request form. Image appearance also may give a clue to suspected child abuse. Therefore, the knowledge of radiographic features of NAI amongst radiographers is essential to help in the diagnosis and prevention of a child from further abuse. This is even more important in Zambia where there is a critical shortage of radiologists;<sup>9</sup> radiographers may be the first to notice NAI on radiographic images. It is a duty of radiographers to report any suspected child abuse to relevant authorities.

The Zambian radiography education system includes diagnostic imaging of non-accidental injuries and foreign bodies in the undergraduate curriculum to equip radiographers with knowledge and skills in paediatric radiography. This is undertaken in radiographic technique subject using Clark's positioning in the radiography textbook.<sup>8</sup> Radiography students have good clinical exposure to accidental foreign bodies such as ingested coins but limited clinical exposures to NAI imaging due to the rare cases reported and presented to medical facilities in the country. There is also a lack of simulation to expose radiography students to imaging of NAI during training.

Research on child abuse is still in its infancy with limited data in Zambia. The first survey conducted in 2014 on the Violence Against Children in Zambia revealed that, amongst the 18-24 years olds, 33.8% of females and 40.1% of males experienced physical abuse before the age of 18.<sup>10</sup> In Zambia, children are commonly referred for imaging with suspected accidental foreign bodies, but percutaneous foreign

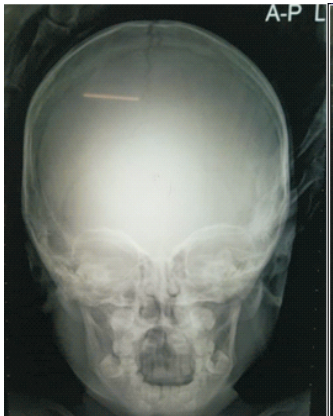bodies are very rare. This paper reports the role imaging played in the diagnosis of a rare case of multiple percutaneous foreign bodies in a 5-year-old child presented with NAI to medical facilities in Zambia. The case report also brings awareness to radiographers and radiologists on the need to pay attention to suspected cases of NAI during imaging and reporting, respectively.

## IMAGING CASE PRESENTATION

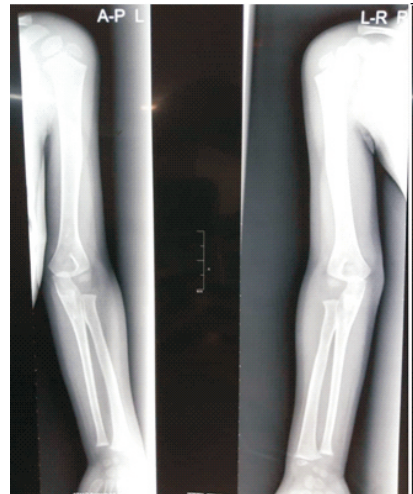A five-year-old child was presented to our radiology department for imaging. The first imaging and removal of some foreign bodies took place at the local hospital before being referred to our teaching hospital for further imaging and surgical removal of remaining foreign bodies. The child was referred from the children ward for plain X-ray imaging accompanied by his grandmother, a paediatrician, nursing staff, a social welfare officer and a counsellor. The clinical details on the radiology request form read "suspected NAI, known multiple percutaneous foreign bodies, locations to aid surgery" for a skeletal survey.

The radiology department was informed in advance about this case. This allowed the Head of Radiology to constitute a team of imaging professionals which consisted of two radiographers, a consultant radiologist, a darkroom technician, and a radiology nurse. This team was tasked to prepare the imaging room before the patient arrived. This included assembling all necessary equipment and accessories such as permanent anatomical side markers (ASM), immobilization devices and personnel radiation protection devices. Two experienced radiographers in paediatric radiography were allocated to X-ray the child. After explaining the procedure to the child, the grandmother, and other clinical staff, a series of images were undertaken to assess the whole skeleton. This comprised of anteroposterior (AP) and lateral projections of the skull, chest, abdomen, and AP projections of upper and lower limbs (Figures 1-7). After assessing the quality of radiographic images and completion of the skeletal survey imaging examination, the patient was sent back to the ward. The radiographic images were

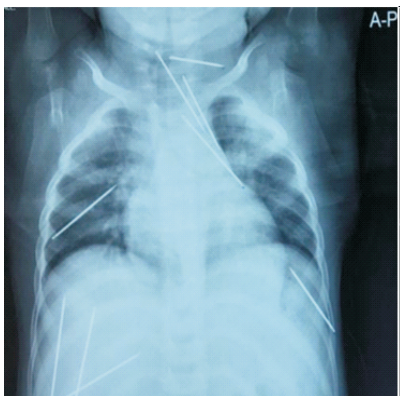
reported by a Consultant Radiologist and diagnostic report sent to the referring medical practitioner.



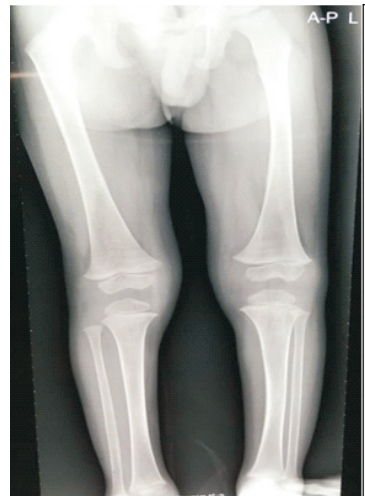**Figure 1:** AP projection of the skull showing a wire on the right side



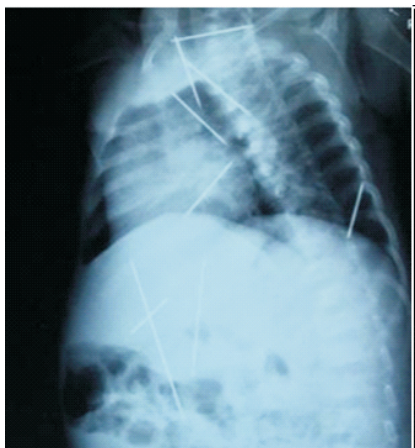
**Figure 6:** Plain images of the upper limb



**Figure 2:** AP projection of the chest showing needles and wires

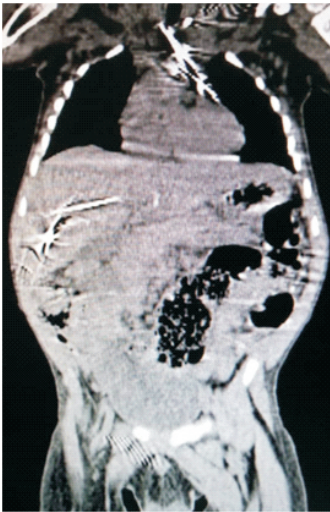


**Figure 7:** Plain images of the lower limb

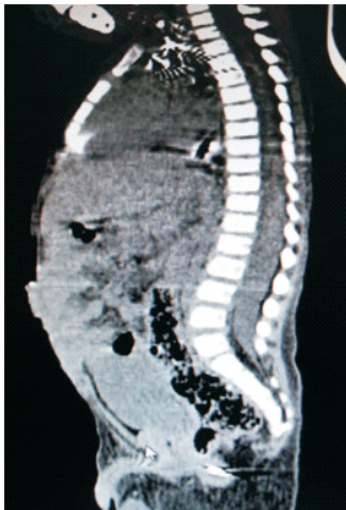

**Figure 3:** Lateral projection of the chest showing needles and wires

After analysing plain film radiographs and the final diagnostic report, the attending medical and surgical

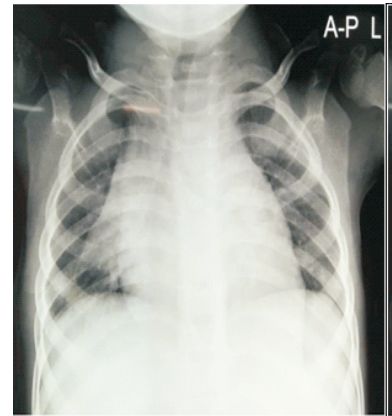


**Figure 8:** CT coronal image of the chest and abdomen

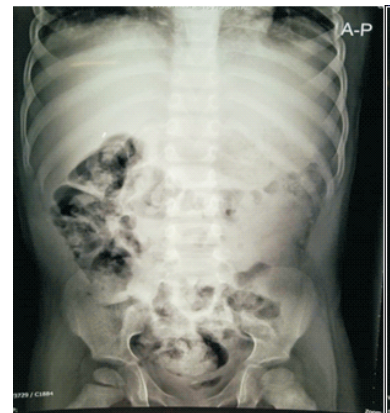

**Figure 9:** CT sagittal image of the chest and abdomen

After imaging, a multi disciplinary team was constituted consisting of radiographers, radiologists, paediatric surgeons, paediatricians, nurses, and anaesthetists to remove the remaining needles in the chest, and abdomen. After careful planning, the remaining foreign bodies were removed by the surgeons under image intensification operated by imaging professionals. Figures 10 and 11 show post-surgery images of the chest and abdomen.



**Figure 10:** Post-surgery AP projection of the chest



**Figure 11:** Post-surgery AP projection of the abdomen

## DISCUSSION

In this case report, conventional radiography (plain film) was the first-line imaging method used to X-ray the child with multiple percutaneous foreign bodies. This matches with the Royal College of Radiologists (RCR) <sup>6</sup> who reported that conventional radiography is the main imaging of choice in the investigation of suspected NAI. A skeletal survey for suspected NAI was performed which comprised of a series of radiographic images: bilateral AP of upper and lower limbs, chest, abdomen, pelvis including AP and lateral of the skull (Figures 1 to 7). This concurs with the literature which reports a skeletal survey as the main

radiological investigation for suspected NAI.<sup>6, 8,11</sup> In babies, the entire body can be imaged in one view. This is referred to as a babygram. However, Hogg et al.<sup>5</sup> does not support this technique because of poor image quality and the whole-body radiation dose is two to three times higher than individual image series. The purpose of undertaking a skeletal survey is to identify occult fractures, exclude underlying skeletal dysplasia or metabolic conditions, and aid in fracture dating which is vital in providing legal arguments.<sup>5,8</sup>

The second-line imaging method used in this case report was computed tomography (CT) to supplement the conventional radiography findings (Figures 8 and 9). CT is an imaging modality or method which uses X-radiation to produce cross-sectional images of the body.<sup>12</sup> It should be mentioned that physically abused children may suffer chest and abdominal injuries and CT plays an important role in this case. In addition, CT has also got greater sensitivity than conventional radiography for the detection of rib (vertebral and scapular) fractures.<sup>6</sup> In Zambia, CT imaging services became available in 1994 when the first scanner was installed at Nkana Mine Hospital (now Sinozam Hospital).<sup>13</sup> There are currently 21 CT scanners in Zambia, with equal number between public and private. The availability of CT services in the country have played a great role in the diagnosis and treatment of diseases and injuries.

In this case report, fluoroscopy guided the removal of foreign bodies. Whitley and others<sup>8</sup> define fluoroscopy as a method of image acquisition which employs an image intensifier or digital flat panel detector to capture images, which are then displayed in real time or as static images on a monitor. Generally, fluoroscopy examinations are performed by radiologists with the assistance of radiographers. It should be mentioned that fluoroscopy is part of both radiologists and radiographers training programmes. The equipment permits imaging professionals to review and record radiographic images in motion in real time.<sup>8,14</sup> Spot films can also

be undertaken during fluoroscopy to record images of interest as seen on the computer monitor.<sup>14,15</sup> Fluoroscopy is used for gastro-international radiology, vascular radiology, reproductive system radiology, urological radiology, drainage and biopsy procedures, and in operating theatre. As highlighted, fluoroscopy is a useful medical imaging tool. However, an audit conducted by Mbewe and others<sup>16</sup> found that fluoroscopy is only available in six provinces (Copperbelt, Eastern, Lusaka, Northern, North-Western and Western), and none in the remaining four provinces of Zambia. This represents 4% of the public-sector imaging equipment with more than one-third (35%) of the population without direct access to public fluoroscopic services.

Figures 1-7 shows radiographic images with multiple percutaneous foreign bodies in the head, neck, chest, abdomen, and pelvis. Foreign bodies (FBs) are rare findings of NAI; the most common findings are fractures.<sup>4,6,8,11</sup> Many different objects may enter the body tissue and cavities via five routes or methods that include percutaneous, ingestion, inhalation, insertion and transocular.<sup>8</sup> This paper reports on the percutaneous foreign bodies of sewing needles and wires which were alleged to have been inserted percutaneously. To facilitate identification of partially opaque foreign bodies and demonstration of any gas in the tissues associated with the entry of the FB or at a late presentation with infection reaction to the FB, exposure technique should be able to demonstrate both bone and soft tissues.<sup>8</sup> This is achieved by selection of appropriate exposure factors.

It should be mentioned that radiographers are among the healthcare professionals who are at the first point of care and often only communicate with a radiologist after an imaging examination is performed.<sup>17</sup> This means that they should be aware of the radiographic features of suspected NAI. The knowledge and skills can be acquired by undertaking an image interpretation course or continuous professional development (CPD). Specific fractures have been recognized for NAI.

These include rib fractures, metaphyseal fractures (bucket handle or corner fractures), skull fractures, scapular fractures, sternal fractures, and post-traumatic periosteal reactions.<sup>4,8,17</sup> Radiographers should, therefore, use good radiographic technique and appropriate exposure factors to best demonstrate these fractures.

The resultant radiographic images (Figures 1-7, 9 and 10) show permanent anatomical side markers (ASM) placed before the X-ray exposure. This is considered the best radiography practice. Anatomical side markers help to identify the anatomical right and left side on a radiographic image. In NAI imaging, digital (electronic) anatomical side markers available with digital radiography (DR) must not be used because it lowers the credibility of the evidence in the court of law.<sup>18</sup> This is a reminder to all radiographers to always use pre-exposure ASM to maintain the standards of the profession.

NAI imaging involves children who are even more vulnerable to ionising radiation. According to the International Commission on Radiation Protection (ICRP),<sup>19</sup> paediatric patients have a higher average risk of developing radiation-induced cancer compared with adults receiving the same radiation dose. The longer life expectancy in children allows more time for any harmful effects of radiation to manifest.<sup>19,20</sup> Besides, the developing organs and tissues in children are more sensitive to radiation.<sup>19,20</sup> Therefore, radiographers should pay more attention to minimise the radiation dose whilst maintaining the quality of images. The radiation protection measures include close collimation of the X-ray beam, effective communication, immobilisation of the child, use of appropriate exposure factors, and gonadal shielding. However, in this case report of NAI, gonad shielding was not used to avoid obscuring important structures. Traditionally, gonadal shielding devices are used on patients during diagnostic X-ray examinations to protect the reproductive organs from exposure.<sup>20</sup> Recent evidence also shows that contact shielding provides minimal or no benefits.<sup>21</sup> The Royal

College of Radiologists (RCR) and others<sup>21</sup> recommends the cease use of contact shielding during imaging.

On the other hand, literature reports that the undergraduate radiography education and training are not sufficient for radiographers involved in imaging of NAI but suggest that postgraduate specialisation is required. For example, in a study conducted in the Republic of Ireland by Rigney and Davis,<sup>7</sup> most (70%) of the radiographers admitted having limited knowledge and skills on imaging of NAI. This is because imaging of NAI goes beyond the production of images; it also includes the understanding of the social, emotional, and legal aspects of physical child abuse. In this Irish research study, postgraduate education and training in specialised paediatric imaging were suggested. This concurs with the Royal College of Radiologists (RCR),<sup>6</sup> who states that radiographers with specialised training in imaging of suspected physical abuse and forensic radiography should perform NAI imaging examinations. This ensures that the imaging examination is performed efficiently and effectively to provide accurate diagnosis and evidence in case of legal proceedings against the perpetrator (s).

## CONCLUSION

This case report highlights that NAI do exist in Zambia. Percutaneous foreign bodies in NAI are rare, the most common findings are fractures due to physical child abuse. Radiographers and radiologists should pay attention to suspected cases of NAI during imaging and reporting, respectively. In addition, NAI cases should be reported to relevant authorities. The literature search found scarcity of research on this subject in Zambia. It is recommended that research is conducted on the awareness of radiographers and radiologists on physical child abuse and NAI in Zambia.

## CONSENT

Permission to use radiographic images was obtained from the Senior Medical Superintendent of our

teaching hospital who was the legal guardian and an ethical waiver obtained from the Lusaka Apex Medical University Bio-Medical Research Ethics Committee (reference number 00097-21).

## REFERENCES

1. World Health Organization. Child maltreatment; 2020. [room/fact-sheets/detail/child-maltreatment](https://www.who.int/child-maltreatment) (Accessed 25 October 2020)
2. Republic of Zambia. Juveniles Act of the Laws of Zambia (Amended). Lusaka: Government Printers; 2011.
3. World Health Organization. Child abuse and neglect; 2002. From [https://www.who.int/violence\\_injury\\_prevention/violence/world\\_report/factsheets/en/childabusefacts.pdf?ua=1](https://www.who.int/violence_injury_prevention/violence/world_report/factsheets/en/childabusefacts.pdf?ua=1) (Accessed 25 October 2020)
4. Nguyen A, Hart R. Imaging of non-accidental injury; what is clinical best practice?. *J Med Radiat Sci.* 2018;65(2):123-130.
5. Hogg P, Hogg D, Eaton C, Sudbery J. Child protection in radiographic practice. *Radiography.* 1999; 5, 127-129.
6. Royal College of Radiologists. The radiological investigation of suspected physical abuse in children. London: RCR; 2018.
7. Rigney D, Davis M. Radiographers and non-accidental injury in children-an Irish perspective. *Radiography.* 2004;10: 7-13.
8. Whitley AS, Jefferson G, Sloane KHC, Anderson G, Hoadley G. Clark's positioning in radiography. 13<sup>th</sup> ed. London: CRC Press Ltd; 2015.
9. Bwanga O, Mulenga J, Chanda E. Need for image reporting by radiographers in Zambia. *Medical Journal of Zambia.* 2019; 46(3): 215-220.
10. Ministry of Youth, Sport and Child Development. Violence against children in Zambia: findings from a national survey, 2014. Ministry of Youth, Sport and Child Development, Lusaka, 2018.
11. Kraft JK. Imaging of non-accidental injury. *Orthop Trauma.* 2011; 25: 109–118
12. Bwanga O, Chanda E, Mwale A, Maliti BK. Radiology nursing: a little-known speciality in Zambia. *South Asian Research Journal of Nursing and Healthcare.* 2020; 2(4): 79-85.
13. Bwanga O, Mwansa E, Sichone J, Kafwimbi S. Establishment of postgraduate education and training in the specialised areas of diagnostic imaging in Zambia. *African Journal of Health, Nursing and Midwifery.* 3(4):55-64.
14. Jones S, Taylor E J. Imaging for nurses. Oxford: Blackwell Publishing Ltd; 2006.
15. Ehrlich RA, Coakes DM. Patient care in radiography: with an introduction to medical imaging. 10th ed. London: Elsevier; 2020.
16. Mbewe C, Kapata PC, Sunkutu VS, Lambwe N, Yakovlyeva N, Chirwa M, et al. An audit of licenced Zambian diagnostic imaging equipment and personnel. *Pan African Medical Journal.* 2020; 1-14.
17. Janssen TL, Van Dijk MI, Malki AI, Van As AB. Management of physical child abuse in South Africa: literature review and children's hospital data analysis. *Paediatrics and International Child Health.* 2013; 33 (4): 216-227.
18. College of Radiographers. Use of anatomical side markers; 2020. From <https://www.rcr.ac.uk/clinical-research-and-quality/clinical-research-and-quality-reports/clinical-research-and-quality-reports> (Accessed 30 November 2020)
19. International Commission on Radiation Protection. Radiological protection in paediatric diagnostic and interventional radiology. London: SAGE Publication Ltd; 2013.
20. Sherer MAS, Visconti PJ, Ritenour ER, Haynes KW. Radiation protection in medical radiography. 8<sup>th</sup> ed. St. Louis: Mosby Elsevier; 2018.
21. British Institute of Radiology (BIR), Institute of Physics and Engineering in Medicine (IPEM), Public Health England (PHE), Royal College of Radiologists (RCR), Society and College of Radiographers (SCoR), the Society for Radiological Protection (SRP). Guidance on using shielding on patients for diagnostic radiology applications. British Institute of Radiology; 2020.