

Histopathological profile of childhood thyroid carcinoma in Ibadan, Southwestern Nigeria

Mustapha A. Ajani^{1,2*}, Sebastian A. Omenai³, John I. Nwadiokwu¹, Ayodeji A. Salami^{1,2}

1. Department of Pathology, University College Hospital, Ibadan, Oyo state, Nigeria

2. Department of Pathology, College of Medicine, University of Ibadan, Ibadan, Oyo state, Nigeria

3. Department of Anatomical Pathology, Edo University, Iyamho, Edo state, Nigeria

*Correspondence: Dr Mustapha A. Ajani (ajanimustapha42@gmail.com)

Abstract

Background

Thyroid carcinoma is a common endocrine malignancy. It is however rare in childhood and often occurs as a result of radiation exposure or inherited genetic mutations. Most childhood thyroid carcinomas are well differentiated. There are very few epidemiological studies of this disease in Nigeria and our study aimed to determine the frequency in a subset of our population. The study aimed to determine the prevalence and histopathological characteristics of childhood thyroid carcinoma in our environment.

Methods

This was a retrospective review of histopathologically diagnosed thyroid carcinoma in children less than 18 years of age in the Department of Pathology, University College Hospital, Ibadan over a 40-year period. Histopathological diagnosis, age, sex and other relevant clinical information were extracted from the hospital records and surgical pathology records of the department. All cases of patients under 18 years old had their slides re-examined and reclassified by two pathologists according to the World Health Organization histopathological classification of thyroid tumours.

Results

There were 25 cases of thyroid carcinomas seen in children within the study period. Papillary thyroid carcinoma was the most common, accounting for 80% of the cases. Follicular carcinoma accounted for 12%, and medullary and anaplastic carcinoma accounted for 4% each. The mean age at presentation was 13 years. There was a female preponderance with females accounting for 60% of cases. Tumours with distant metastasis made up 20% of the cases.

Conclusion

Childhood thyroid carcinomas are rare in our environment, with a minority of cases presenting with metastases.

Key Words; Childhood thyroid carcinoma, papillary thyroid carcinoma, thyroid cancer, metastasis

Introduction

Thyroid carcinoma is one of the most common endocrine malignancies. It is most commonly seen in adults and is rare in childhood¹. Studies have shown an increase in the incidence of thyroid carcinoma in both adults and children all over the world and it has been suggested that this may be due to an increase in exposure to radiation^{2,3}. This is thought to be from prophylactic therapy for other head and neck tumours or radiation accidents^{2,3}. The incidence of thyroid carcinoma in Nigeria is less than 2% and is seen more in adults^{4,5}. The carcinomas are mainly of follicular cell origin, but medullary carcinomas, which constitute a small percentage of the variants, arise from the calcitonin-producing cells^{3,6,7}.

Thyroid carcinomas can present with a varied spectrum of degree of differentiation, from well-differentiated to undifferentiated and anaplastic variants⁸. Well-differentiated tumours are more common in childhood, whereas moderately to poorly differentiated tumours are seen in adults⁸. Papillary thyroid carcinoma (PTC), which is a well-differentiated variant of thyroid tumours, is the most common histological type of thyroid cancer in childhood and has been shown to have a good prognosis^{9,10,11}. Studies have shown a 5-year survival rate of 100% for childhood thyroid cancer following surgical management and radioactive ablation^{12,13,14}. However, other authors have suggested increased aggressiveness of paediatric thyroid tumours due to their biology, resulting from the genetic mutations inherent in the lesion¹⁵. These

genetic mutations are particularly frequent in PTC, with the most common being the RET/PTC rearrangement, while BRAF mutation is seen relatively more common in radiation-induced thyroid carcinoma⁹.

Thyroid carcinoma can present with metastases at presentation and this may be the first symptom the patient sees¹⁶. The most frequent site of secondary metastases includes the cervical lymph node and lungs³. Thyroid cancers may present either as a solitary nodule or a dominant nodule in a multinodular thyroid lesion. Thyroid nodules are not very common in children, but when present, a significant proportion are malignant⁶. Pre-operative work up including use of fine-needle aspiration, ultrasound, scintigraphy, and molecular studies need to be done to improve pre-operative diagnosis⁷. Thyroid scans are very useful in selecting suspected cases for fine-needle aspiration biopsy⁹. Fine-needle aspiration biopsies, when done properly, have a diagnostic accuracy of about 90% and are used to select patients for surgery⁹.

A search of the literature showed that although many studies have been done on the epidemiology of thyroid cancers in African subpopulations, studies in our environment examining the histopathologic profiles of paediatric thyroid cancers appear to be rare. This may be due to the uncommon nature of this group of tumours. This study was conducted to determine the prevalence and histopathological characteristics of childhood thyroid carcinomas.

Materials and methods

This was a 40-year retrospective study of histopathologically diagnosed thyroid carcinomas in patients under the age of 18 years managed in our institution.

Histopathology records and summarized clinical notes in the Department of Pathology, University College Hospital, Ibadan from January 1980 to December 2019 were reviewed and those that met the inclusion criteria were included. The inclusion criteria included age of less than 18 years, diagnosis of a thyroid carcinoma, and presence/adequacy of archival formalin-fixed paraffin-embedded tissue blocks and/or histopathology slides. Cases of patients of 18 years and above and those whose archived slides and/or paraffin blocks were missing were excluded from the study. The University College Hospital is an 850-bed hospital and the premier tertiary health facility in the Southwestern region of Nigeria. It is a referral centre for other public and private hospitals in Ibadan and its environs.

This study was conducted in accordance with the Helsinki declaration, maintaining confidentiality and dignity of patients. Patient names or other unique identifiers were not used in this study. Histopathological diagnosis, age, sex and other relevant clinical information were extracted from the clinical and surgical records of the patients. All the haematoxylin and eosin (H&E) stained sections were reviewed and histologically classified by two pathologists according to the World Health Organization histological classification of thyroid tumours (4th edition, 2017)¹⁷.

The data were analysed using the Statistical Package for the Social Sciences Chicago, Illinois State (SPSS) software version 23 (IBM Corporation, SPSS Statistics Inc., USA, 2014).

Chi square was used for categorical variables. $P \leq 0.05$ was considered significant.

Ethical approval

Ethical approval was not required for this study as there were no ethical issues related to patients' information or diagnosis.

Results

There were 25 cases of childhood thyroid carcinoma from 320 cases of thyroid carcinomas diagnosed in our institution during this study period constituting 7.8% of thyroid cancers. The patients were between the ages of 2 and less than 18 years. The mean age at presentation was 13 years. There was gradual increase in the incidence of childhood thyroid carcinoma, with increasing age peaking at ages between 15 and less than 18 years with 48% of the cases (Table 1). There was a female preponderance, with females accounting for 60% of cases. The majority (80%) of cases were PTC (Figures 1 and 2, Table 2) closely followed by follicular thyroid carcinoma (FTC) (Figure 3). The conventional variant not otherwise specified (NOS) of PTC was the most common variant with 60% of cases, followed by the encapsulated and follicular variants with 15% each. The oncocytic and sclerosing variants were also seen accounting for 5% each. Twenty percent of cases presented with metastatic disease. The five cases that presented with metastases were all PTC, four of which were of papillary carcinoma NOS type that metastasized to cervical lymph nodes, while one case was a follicular variant of PTC that metastasized to the humeral bone causing pathological fracture (Table 3). Single cases of medullary thyroid carcinoma (Figure 4) and

Table 1. Age distribution of childhood thyroid carcinomas

Age group (years)	Frequency	Percentage
0-4	1	4
5-9	3	12
10-14	9	36
15-<18	12	48

Table 2. Frequency table showing histological types of thyroid carcinoma seen in childhood

A. Histological types	Frequency: n (%)
Anaplastic carcinoma	1 (4)
Follicular carcinoma	3 (12)
Medullary thyroid carcinoma	1 (4)
Papillary thyroid carcinoma (PTC)	20 (80)
B. Variants of PTC	
Encapsulated	3 (15)
Follicular	3 (15)
PTC NOS	12 (60)
Oncocytic	1 (5)

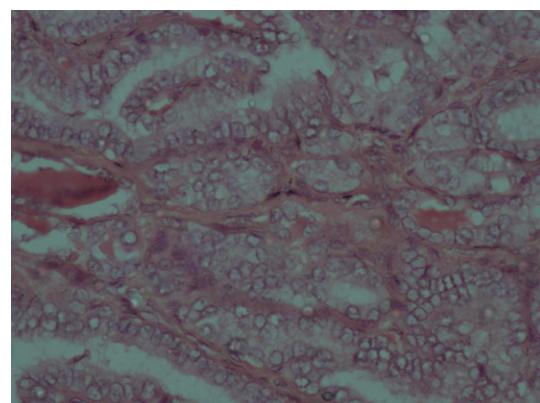


Figure 1. Photomicrograph showing childhood papillary thyroid carcinoma (not otherwise specified variant) (haematoxylin and eosin stains, $\times 100$).

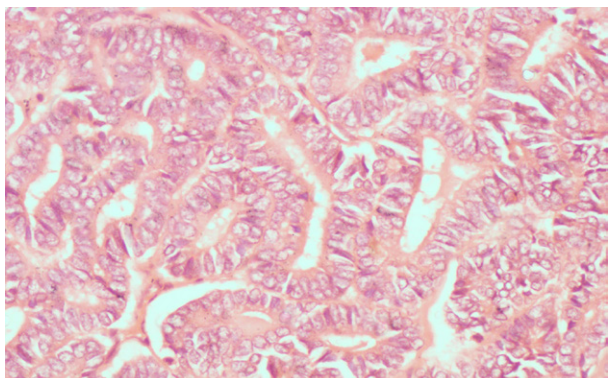


Figure 2. Photomicrograph showing childhood papillary thyroid carcinoma (follicular variant) (haematoxylin and eosin stains, ×400).

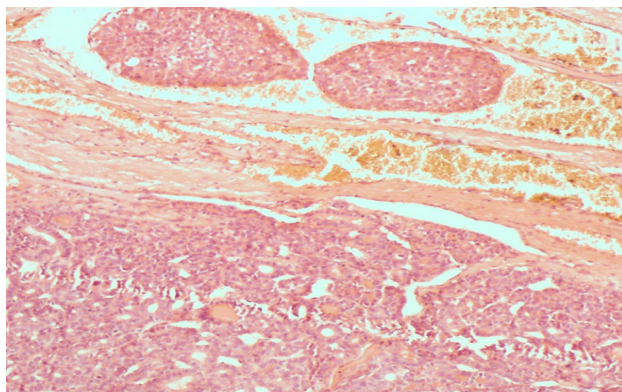


Figure 3. Photomicrograph showing childhood follicular thyroid carcinoma with vascular invasion (arrow) (haematoxylin and eosin stains, ×100).

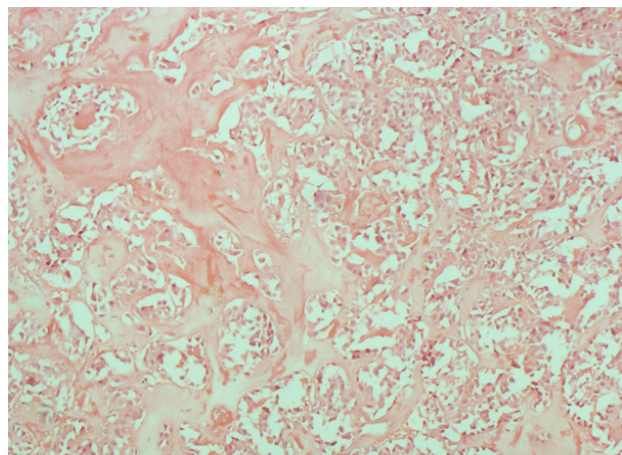


Figure 4. Photomicrograph showing childhood medullary thyroid carcinoma with area of amyloid deposits (arrow) (haematoxylin and eosin stains, ×100).

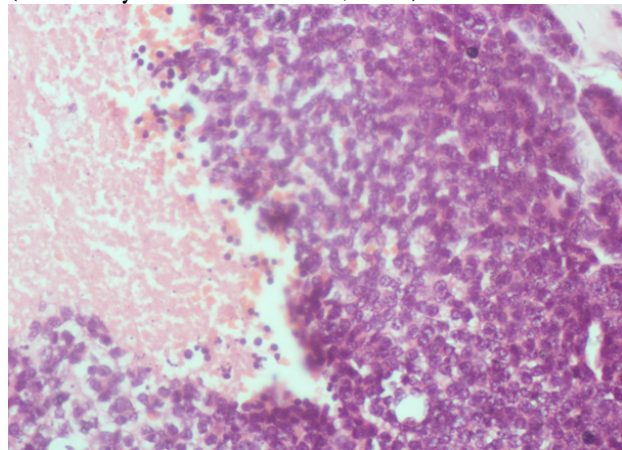


Figure 5. Photomicrograph showing childhood anaplastic thyroid carcinoma with area of necrosis (star) (haematoxylin and eosin stains, ×400).

Table 3. Frequency distribution of metastatic thyroid cancer

	Presence of metastatic disease	
	Yes (n)	No (n)
A. Histological diagnosis		
Anaplastic carcinoma	0	1
Follicular carcinoma	0	3
Medullary carcinoma	0	1
Papillary thyroid carcinoma	5	15
B. Age group (years)		
0–4	1	0
5–9	1	2
10–14	2	7
15–19	1	11

Table 4. Sex distribution of childhood thyroid carcinoma.

	Histopathological diagnosis			
	Anaplastic carcinoma	Follicular carcinoma	Medullary carcinoma	Papillary thyroid carcinoma
Sex of patients				
Female	0 (0%)	2 (66.7%)	0 (0%)	13 (65%)
Male	1 (100%)	1 (33.3%)	1 (100%)	7 (35%)

anaplastic carcinoma (Figure 5) were seen in males. The other histological types of childhood thyroid cancers all had female preponderance (Table 4).

Discussion

Thyroid cancer is not common in childhood, and this study found only 25 cases over a 40-year review period^{11,12}. The age-standardized rate for childhood thyroid cancer in an Indian study by Nandakumar et al. was 0.9%¹². Tsegaye et al. examined thyroid lesions in the general population and reported a prevalence of 9.8% of thyroid cancers amongst thyroid lesions¹⁸. In our study, childhood thyroid cancer constituted only 7.8% of all thyroid cancers during the review period.

In childhood, although incidence of thyroid nodules is rare, the rate of discovery of cancers is as high as 50%⁶. The most common histological type of thyroid cancer in our study was PTC. This is very similar to the pattern in the general population as well as most studies that reviewed thyroid neoplasms in childhood^{10,11}. A study from Port-Harcourt, Nigeria found that FTC was the most common and did not report cancer in anyone less than 18 years of age⁴. Well-differentiated carcinomas (PTC and FTC) accounted for majority of cancers seen in this study, and this is consistent with the report by Buckwalter et al. that well-differentiated cancers form the majority of childhood thyroid cancers and are more likely to arise from follicular cells¹⁹. Other types of cancers that can be seen in childhood include medullary carcinoma, Hurthle cell carcinoma, and insular carcinoma^{11,20}. PTC and FTC were found to be more common in females than males in our study, which is similar to studies done by Rahbari et al.²¹ and Sousa et al.²² We found a case of anaplastic carcinoma in a 13-year-old male. However, the gender distribution of the more aggressive histological types of thyroid carcinoma (medullary thyroid carcinoma and anaplastic carcinoma) is similar to papillary thyroid carcinoma and follicular thyroid carcinoma.^{21,22} Anaplastic carcinomas of thyroid are very rare in childhood, but a higher incidence of anaplastic carcinoma has been reported among African Americans compared with Whites^{14,19}.

The most common histological variant of PTC in our study was the conventional NOS variant, and this is similar to findings by Millman et al.^{2,10}. Of the special variants, follicular and encapsulated variants formed the majority in this study, similar to studies by Shirahige et al.² and Millman et al.¹⁰. The mean age at presentation was 13 years, which is similar to a report by Desjardins et al. that showed an average age of childhood thyroid cancer patients of 13.6 years²³. There was a steady rise in frequency of thyroid cancers with increasing age, and about 84% of cases were patients between the ages of 10 and 18 years. This is similar to findings from a previous review of head and neck cancers in children in our institution that reported that the majority of thyroid cancers were recorded in patients between 11 and 18 years old⁵. Also, Ashraf et al. reported that malignant thyroid neoplasms presents most often in late childhood²⁴. Consistent with other studies, 60% of cases in our series were female^{5,23}.

Metastatic disease was seen in 20% of cases in this series. This is relatively low compared to 88% reported by Harness et al.³ and 46.2% by Millman et al.¹⁰ Metastases were seen almost exclusively in PTC in this series, similar to the review done by Millman et al. where 10 of the 12 metastatic cancers were PTC¹⁰. Metastases did not show a relationship with age group; we found metastatic disease in both early and late childhood.

Conclusion

Childhood thyroid cancer is rare in our environment, with a minority presenting with metastatic disease. The incidence of childhood thyroid cancers increases gradually with increasing age. PTC is the most common histopathological type of cancer in children. Undifferentiated and poorly differentiated thyroid cancers are very rare.

Limitation

This study has some limitations. Firstly, due to loss of patients to follow up, there was no follow-up data on the children managed for thyroid carcinoma. This would have provided prognostic information on childhood thyroid cancers. Secondly, we were unable to determine the presence or absence of exposure to radiation from our records of clinical history. So, this was not explored further, as a definitive statement on potential exposure to radioactive substance was lacking in all our cases. Despite these limitations, this study provides epidemiological data that supports the rarity of childhood thyroid carcinomas.

Authors' contributions

MAA conceived, designed the study, and reported H&E-stained slides. SAO designed the study, and acquired, analysed, and interpreted the data. JIN designed the study, acquired the data, and reported the H&E-stained slides. AAS designed and interpreted the data. All authors drafted, revised, read, and approved the manuscript.

Funding

This study was funded by the authors.

Competing interests

Authors declare that they have no competing interests.

References

- Monga T, Kuka AS, Singh N. Histopathological profile of solid tumours of childhood and infancy in Northwest Punjab, India. *Indian J Pathol Oncol.* 2017;4(2):166-73.
- Shirahige Y, Ito M, Ashizawa K, Motomura T, Yokoyama N, Namba H, et al. Thyroid cancer : comparison of Japan and Belarus. *Endocr J.* 1998;45(2):203-9.
- Harness JK, Thompson NW, Nishiyama RH, Arbor A. Childhood thyroid carcinoma. *Arch Surg.* 1971;102:278-84.
- Dodiya-Manuel A, Athanasius BP. Thyroid carcinoma in University of Port Harcourt Teaching Hospital. *Br J Med Med Res.* 2017;20(9):1-5.
- Adeyemo AA, Okolo CA. Pediatric head and neck malignancies in sub-Saharan Africa. *J Pediatr Sci.* 2012;4(4):e162.
- Dinauer CA, Breuer C, Rivkees SA. Differentiated thyroid cancer in children: diagnosis and management. *Curr Opin Oncol.* 2008;20:59-65.
- Niedziela M. Pathogenesis, diagnosis and management of thyroid nodules in children. *Endocr Relat Cancer.* 2006;13(2):427-53.
- Buckwalter JA. Childhood thyroid carcinoma: pathologic considerations and their therapeutic implications. *J Clin Endocr Metabol.* 1955;15:1437-52.
- Corrias A, Mussa A. Thyroid nodules in pediatrics: which ones can be left alone, which ones must be investigated, when and how. *J Clin Res Ped Endocr.* 2013;5:57-69.
- Millman B, Pelliteri PK. Thyroid carcinoma in children and adolescents. *Arch Otolaryngol Head Neck Surg.* 1995;121:1261-4.
- Mussa A, Andrea M De, Motta M, Mormile A, Palestini N, Corrias A. Predictors of malignancy in children with thyroid nodules. *J Pediatr.* 2015;167(4):886-92.

12. Nandakumar A, Anantha N, Appaji L, Swamy K, Mukherjee G, Venugopal T, et al. Descriptive epidemiology of childhood cancers in Bangalore, India. *Cancer auses Control*. 1996;7:405-10.
13. Guille JT, Opoku-Boateng A, Thibeault SL, Chen H. Evaluation and management of the pediatric thyroid nodule. *Oncologist*. 2015;20:19-27.
14. Hollenbeak CS, Wang L, Schneider P, Goldenberg D. Outcomes of thyroid cancer in African Americans. *Ethn Dis*. 2011;21:210-5.
15. Paulson VA, Rudzinski ER, Hawkins DS. Thyroid cancer in the pediatric population. *Genes (Basel)*. 2019;10(9):723. doi:10.3390/genes10090723.
16. Ajani MA, Awosusi BL, Fatunla EO, Adegoke OO, Salami AA. Fracture of the humeral bone as the first clinical presentation of metastatic papillary thyroid carcinoma in Ibadan. *AJMAH*. 2019;16(4):1-7
17. Lloyd RV, Osamura RY, Klöppel G, Rosai J, editors. WHO classification of tumours of endocrine organs. 4th ed. Lyon, France; IARC; 2017. p. 209-16.
18. Tsegaye B, Ergete W. Histopathologic pattern of thyroid disease. *East Afr Med J*. 2003;80(10):525-8. doi:10.4314/eamj.v80i10.8755.
19. Buckwalter JA, Thomas CG, Freeman JB. Is childhood thyroid cancer a lethal disease? *Ann Surg*. 1975;181(5):632-8.
20. Rijhwani A, Satish GN. Insular carcinoma of the thyroid in a 10-year-old child. *J Pediatr Surg*. 2003;38:1083-5.
21. Rahbari R, Zhang L, Kebebew E. Thyroid gender disparity. *Future Oncol*. 2010;6(11):1771-9
22. Sousa A, Ferreira M, Oliveira C, Ferreira PG. Gender differential transcriptome in gastric and thyroid cancers. *Front Genet*. 2020;11:808. doi: 10.3389/fgene.2020.00808.
23. Desjardins BJG, Bass J, Leboeuf G, Lorenzo M Di, Letarte J, Khan AH, et al. A Twenty-Year Experience With Thyroid Carcinoma in Children. *J Pediatr Surg*. 1988;23(8):709-713.
24. Ashraf M, Kumar P, Reza MA, Ragesh KP. Neoplastic diseases of the head and neck in children. *Indian J Otolaryngol Head Neck Surg*. 2006;58(4):343-346.