



vascularised fibular graft.. Furo Orupabo -ISSN 1597-4292

Vascularised Fibular Graft for a Radial Defect following Tumour Excision in a Tertiary Institution in Nigeria

Furo Orupabo

Department of Orthopaedics, University of Port Harcourt Teaching Hospital, PMB 6173, Port Harcourt, Nigeria.

Corresponding: E-mail: orupsd1st@yahoo.com

ABSTRACT

Background: Options for bridging large segmental bone defects following trauma or surgical resection are numerous. Various methods have been described and tried out, each having its advantages and drawbacks. In developing countries, the choices are limited due to unavailability and high cost of sophisticated implants and materials, and the relative lack of expertise to carry out some of these procedures. This case report highlights the feasibility of the use of a free vascularised fibular graft to bridge a large radial bony defect following tumour resection at a tertiary hospital in Nigeria.

Case report: Mr J. A, a 30 year old businessman, had an excision biopsy of a mass originating from his distal right radius. The histopathology report confirmed it to be an aneurismal bone cyst. He was however left with a large (approximately 10cm) radial defect, which was subsequently bridged with a vascularised fibular graft. Post operatively, his hand and wrist functions were satisfactory.

Conclusion: Free vascularised fibular graft is a viable option for bridging large bone defects in developing countries. As long as the expertise is available, it is less complicated and more economical than other advanced methods. It has fewer drawbacks when compared with the methods currently in use in our environment.

Keywords: Bone graft, Bone defects, Vascularised Graft, Fibular.

Introduction

Various methods have been described for reconstruction of large segmental bone defects following trauma or surgical treatment of bone infections and tumours.

The use of endoprosthesis, allografts, allograft- prosthetic composites, autogenous non vascularized strut graft, and distraction osteogenesis have all had various levels of success¹. However, reported rates of complications, limitations in the defect size that can be bridged, and prolonged periods of treatment outline some of the short comings of the above procedures.

Vascularized autogenous bone graft for long bone reconstruction has been a viable option for large intercalary bone defects for over 30years, following resection for bone tumours or infection.²⁻⁵

The fibula is the only expendable long bone in the body, with up to 25 cm of available bone. The pedicle length averages 6 cm, with a vessel diameter of 2 to 3 mm. It is vascularized through an



Vascularised fibular graft.. Furo Orupabo -ISSN 1597-4292

endosteal and periosteal blood supply. The nutrient artery enters in the upper middle third of the fibula and supplies the endosteal circulation. The periosteal blood supply is through four to six peroneal perforators that are 3 to 5 cm apart and allow for multiple osteotomies. Although the fibula can survive on either the endosteal or the periosteal blood supply, it is best to preserve both supplies if possible to maximize the vascularity of the fibula.⁴

Although some authors have reported the use of non-vascularized fibular graft transfers in Nigeria, the relative lack of expertise and facilities for microvascular surgery, ultimately limits the use of vascularized bone grafts as an option for the reconstruction of large defects.⁶⁻⁸

This case report highlights the possibility of the use of a vascularized fibular graft as a viable option for bone defect reconstruction in developing countries.

Case Report

Mr J. A, a 30-year old businessman presented with a six month history of a swelling of the right forearm close to the wrist joint. The mass was located on the radial aspect of the distal right forearm and was noticed a week after a trivial trauma to the right wrist. There was a gradual progressive increase in the size of the mass with associated mild to moderate pain over it and distal paraesthesia. Hand motor function was intact. However, he was unable to use the hand optimally because of the pain. There was no history of similar previous or concurrent swelling. There was also no fever, weight loss, chronic cough or night sweats.

He visited some traditional bonesetters where scarifications were made over the mass into which local concoctions were applied. These concoctions led to worsening of his pain and festering of the mass hence his decision to come to the hospital. He was not a known hypertensive or diabetic and had no previous admissions or surgeries. He also had no known drug allergies.

Clinical examination showed a large mass on the radial aspect of distal right forearm, extending to the wrist, measuring about 10cm x 8cm x 4cm. There were obvious scarification marks with some areas of hyperpigmentation and crisscrossing of large superficial veins over the mass. The mass originated from the radius and had varied consistencies from soft to firm to hard at different areas. The distal ulna was found to be dislocated. The radial pulse was palpable over the mass and distal sensation was intact. The handgrip power was 3 over 5. Chest and abdominal examinations were unremarkable.

Radiographs of right forearm revealed a right distal radial tumour, extending from the wrist to the junction of the distal and middle third of the bone, approximately 8 x 6 x 4cm. There were multiple cystic/lytic areas within the mass, the cortex was intact. The ulna was displaced laterally and dorsally (Figs 1, 2).

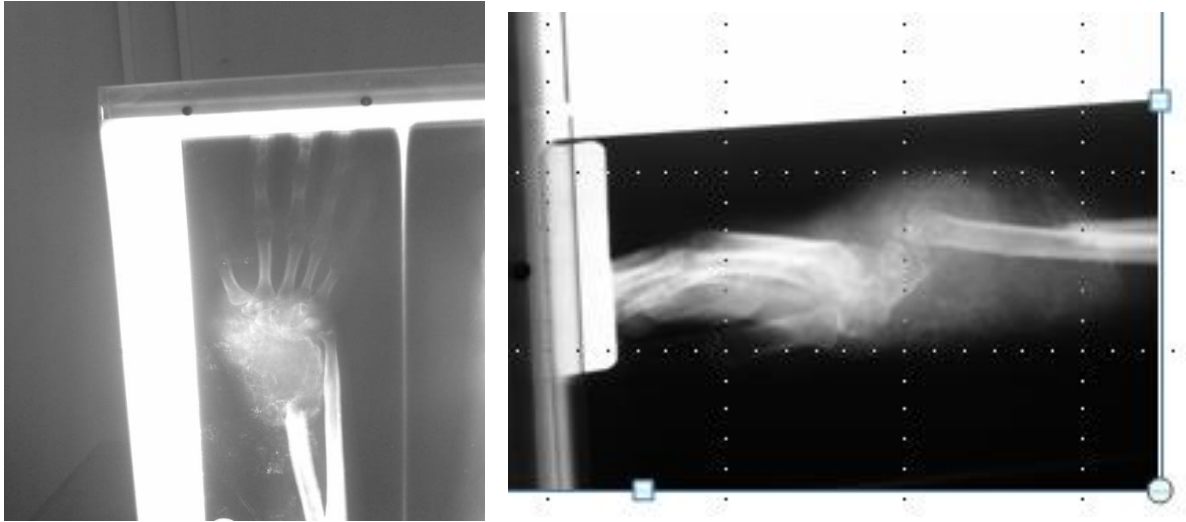


Figure 1 and Figure 2. Pre operative Xrays

An incisional biopsy was done and the histopathology report came back as an aneurismal bone cyst. The mass was subsequently marginally excised and a repeat histopathology was done, which confirmed the diagnosis. The patient was however left with a right radial defect of about 10cm, with associated wrist instability and radial deviation.

At a definitive operation, the right fibula was harvested with its blood supply (Fig 3) and the bone was placed in the defect and fixed proximally and distally with a dynamic compression plate and a t-plate respectively. The nutrient vessels were anastomosed end to side with the radial artery and vein using an operating loupe. Post operatively antibiotics, analgesia, and anticoagulants were given. He was discharged a week later.

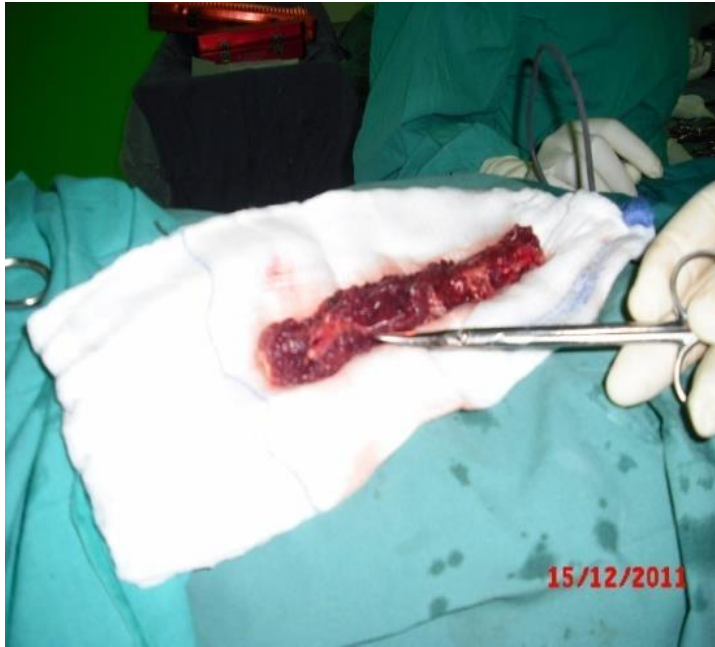

Figure 3. Free Fibular Graft

On follow-up at 6 months, wound had healed completely, the wrist was stable and flexible, and function was good. A check radiograph showed good callous formation at the proximal and distal fixation (Figures 4, 5, 6 and 7).

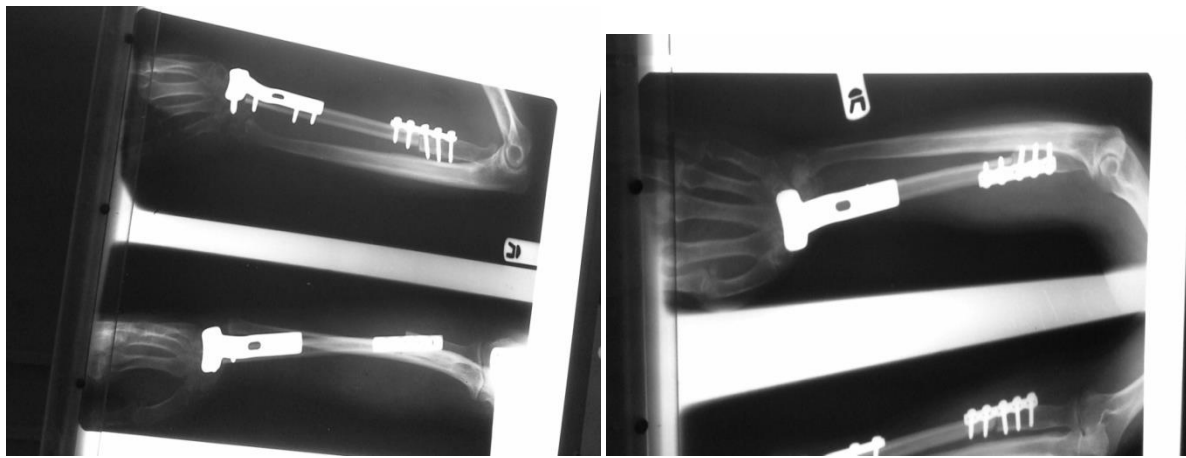
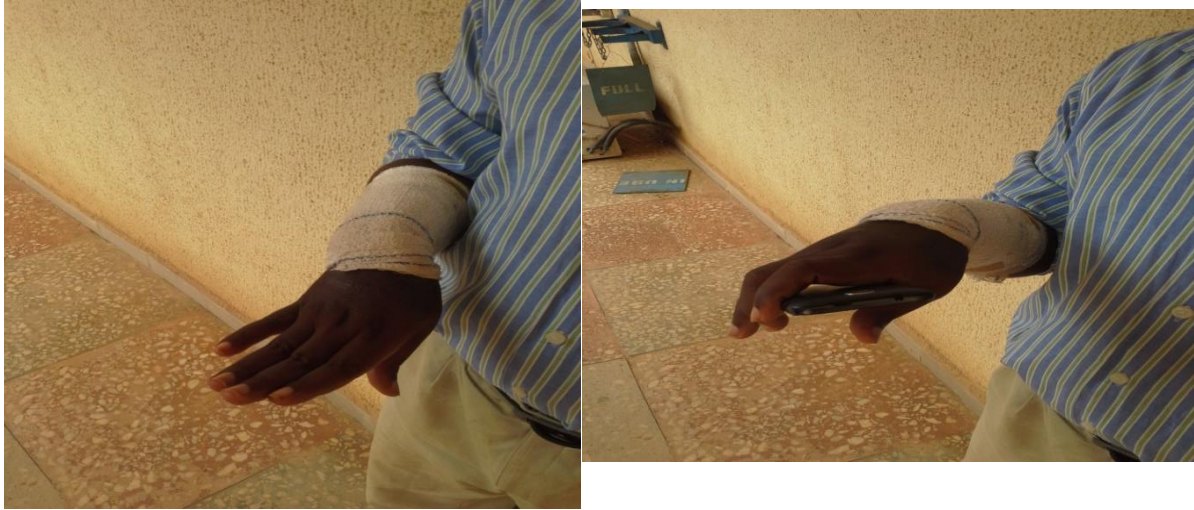

Figure 4. Immediate post-operative radiographs Figure 5. Six months follow-up



Figures 6 and 7 showing post operative hand and wrist function

Discussion

Reconstruction of large bone defects has been a major challenge for Orthopaedic Surgeons worldwide, more so in the West African Sub-region, and especially in Nigeria. As outlined previously, the major challenges include lack of availability of endoprosthesis and bone graft substitutes. Even when these items can be sourced, the immense cost to the patient makes them unviable options.¹

The use of bone transport and non-vascularized fibula strut graft for replacing large bone defects has been reported in literature with varying degrees of success.^{1,6,7} These have come to be acceptable methods of bridging such defects in the absence of other more sophisticated capital intensive options for which the expertise may not be available. However, the drawbacks, limitations, and possible complications associated with these methods have also been recorded.⁴

The advantage of using an autogenous graft instead of allografts or artificial implants cannot be over emphasized. In addition, the cost implications are greatly reduced, limited to the costs of the vascular surgery instruments, sutures and holding plates. This of course does not include the cost of the surgeon's training.

Unstable large bony defects in the upper extremity remain difficult to treat. Common treatment options for forearm instability may be inadequate, including functional bracing and activity modification, internal or external fixation with bone grafting, structural grafts of allogenic or autogenous cortical bone, large-volume autogenous cancellous bone grafts, or distraction



osteogenesis. Although amputation is an option, poor results from upper extremity prosthetics are well known.

Our index case report demonstrates that free vascularized fibular graft transfer is a feasible option for bridging large bone defects even in our environment, provided the expertise is available. The advantages of vascularized fibula grafting for large segmental bony defects include immediate structural support, the potential for graft hypertrophy, relative resistance to infection by virtue of the preserved blood supply, and a reduced reliance on the envelope of surrounding soft tissue for graft incorporation and healing. It is the procedure of choice when the recipient site has been previously infected, is larger than 6 cm, or has not responded to conventional treatment.^{4,9}

Conclusion

Free vascularized fibula grafting is the procedure of choice for bridging large bone defects. It is advantageous in terms of surgical outcome and cost. In view of the fact that only few surgeons with experience in vascular surgery are available in the country, there is the need to train more surgeons in vascular surgery and free vascularized tissue transfers.

References

1. Getty PJ, Peabody TD. Complications and functional outcomes of reconstruction with an osteoarticular allograft after intra-articular resection of the proximal part of the humerus. *J Bone Joint Surg Am* 1999;81A:1138-1146.
2. Yuan Sun, Changqing Zhang, Dongxu Jin, Jiagen Sheng, Xiangguo Cheng, Xudong Liu, Shengbao Chen, Bingfang Zeng, Free vascularised fibular grafting in the treatment of large skeletal defects due to osteomyelitis *international orthopaedics*, 2010; 34(3): 425-430.
3. Gebert C, Hillmann A, Schwappach A, Hoffmann C, Harges J, Kleinheinz J, Gosheger G Free vascularised fibular grafting for reconstruction after tumour resection in the upper extremity. *J Surg Oncol* 2006;94:114-127.
4. Alexander B. Dagum, MD, FRCS(C) *Skeletal Reconstruction of the Upper Extremity With a Vascularised Fibula Graft: Clinical Applications, Techniques, and Results. Plastic Surgery Pulse News*, 2011; 2(4)
5. Innocenti M, Delcroix L, Manfrini M, Ceruso M, Capanna R. Vascularised proximal fibular epiphyseal transfer for distal radial reconstruction. *J Bone Joint Surg Am* 2004;86A:1504-1511.
6. Y. Z. Lawal, E. S. Garba, M. O. Ogirima, I. L. Dahiru, M. I. Maitama, K. Abubakar², F. S. Ejagwulu; Use of non-vascularized autologous fibula strut graft in the treatment of segmental bone loss, *Annals of African Medicine*, 2011; 10,(1):25-8.
7. B. Omololu, S. O. Ogunlade, T. O. Alonge; Limb conservation using non vascularised fibular grafts, *West African Journal of Medicine*, 2002; 21:347-349.
8. OC Nwokike, JE Onuminya, E Esezobor, E Edomwonyi, DO Olomu; Management of Bone Gaps with Intramedullary Autologous Fibular Strut Graft, *Nigerian Journal of Orthopaedics and Trauma*, 2013; 12 (1): 24-29.
9. Collin T, Sugden P, Ahmed O, et al. Technical considerations of fibular osteocutaneous flap dissection. *J Plast Reconstr Aesthet Surg* 2008; 61:1503-1506.