

# Abdominal Tuberculosis Mimicking Intra-abdominal Malignancy: A case report.

Type of Article: **Case Report**

**Emmanuel Auchi Edafe, Datonye Dennis Alasia, Maclean Rumokere Akpa**

*Department of Internal Medicine, University of Port Harcourt Teaching Hospital, Port Harcourt, Nigeria.*

## **ABSTRACT**

### **BACKGROUND**

*Abdominal TB usually presents with nonspecific findings and may thus mimic a multitude of gastrointestinal disorders. Abdominal tuberculosis may therefore present as large and palpable intra-abdominal masses usually arising from lymphadenopathy which may mimic lymphomas and other malignancies. We present the report of a patient with suspected abdominal malignancy diagnosed with abdominal tuberculosis.*

### **METHODS**

*The case records of a patient who presented at the university of Port Harcourt Teaching hospital, medical unit with an abdominal mass diagnosed with abdominal Tb and a review of the literature utilizing google, PubMed, medline and existing literature was utilized.*

### **RESULTS**

*Abdominal Tb is a major contributor to the burden of EPTb with reports of increasing incidence. Based on the wide spectrum of symptoms and signs originating from various parts of the abdomen the disease may be misdiagnosed.*

### **CONCLUSION**

*In conclusion abdominal Tb still remains a disease which should be kept in mind and considered by clinicians in Nigeria as it is a great mimic and may be hard-to-*

*diagnose. A high index of suspicion and the use of ancillary, radiologic and surgical techniques should be employed in order to make a correct and prompt diagnosis.*

### **KEYWORDS**

*Abdominal Tuberculosis; Intraabdominal Mass; Nigeria.*

*Correspondence: Dr D.D. Alasia*

*Email: datonye.alasia@uniport.edu.ng*

### **INTRODUCTION**

With the recent resurgence of tuberculosis (Tb) infections<sup>1</sup> and its combination with HIV/AIDs; the interest in extra-pulmonary tuberculosis (EPTb) disease such as abdominal (Tb) has been revived.<sup>1-4</sup>

Abdominal Tb is a major contributor to the burden of EPTb as it has been shown to account for 11% of all cases of EPTb<sup>2</sup>. The increasing prevalence of extra-pulmonary and abdominal Tb in high burden countries like Nigeria is illustrated by the report of a study<sup>4</sup> in Enugu Nigeria which documented a fourfold increase in the cases of EPTb from 2000-2004 to 2005-2009. The contribution of HIV/AIDs to the rising prevalence of EPTb is also demonstrated in a study<sup>5</sup> from Benin South-South Nigeria which found a TB HIV prevalence of 33.9% and a 21.4% incidence of EPTb in HIV patients.

Abdominal TB usually presents with nonspecific findings and may thus mimic a multitude of gastrointestinal disorders; as

patients with the disease have a wide spectrum of symptoms and signs originating from various parts of the abdomen, such as the peritoneum, lymph nodes, intestines and organs like the liver.<sup>2,6,7</sup>

Abdominal tuberculosis may therefore present as large and palpable intra-abdominal masses usually arising from lymphadenopathy which may mimic lymphomas and other malignancies.<sup>8-11</sup>

This scenario therefore makes the diagnosis of abdominal tuberculosis difficult especially in the absence of bacteriologic evidence. Therefore in such situations surgical, radiologic and histologic techniques may become the major tools to aid diagnoses.<sup>8-11</sup>

The following report highlights a case of abdominal tuberculosis which was initially thought to be intrabdominal malignant process. The importance of good clinical history, bacteriological evidence and abdominal imaging in the management of abdominal tuberculosis is also highlighted.

### CASE PRESENTATION

A 58yrs old male (O.A) presented with complaints of progressively increasing abdominal swelling of 7 month duration and progressive weight loss. The above symptoms were associated with, low grade fever, drenching night sweat and dizziness. There was no history of contact with any person with chronic cough but the patient admitted to the use of unpasteurized milk got from cattle raisers. He had also been diagnosed with diabetes mellitus one year before presentation and was poorly adherent with his oral hypoglycaemic drugs.

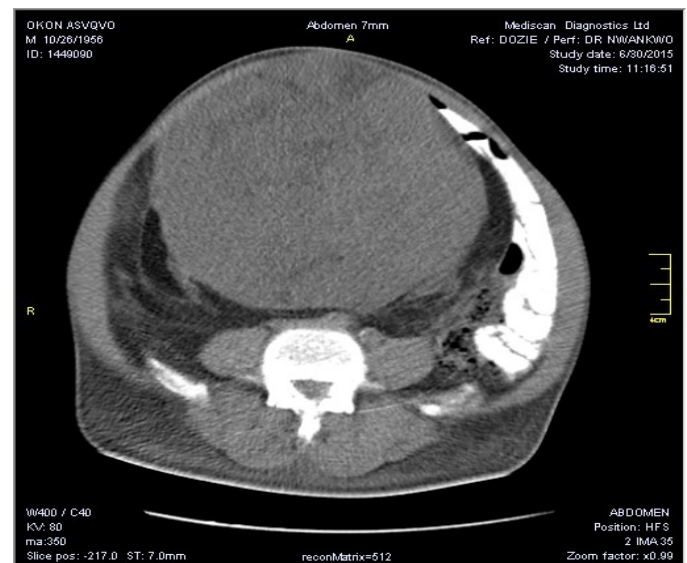
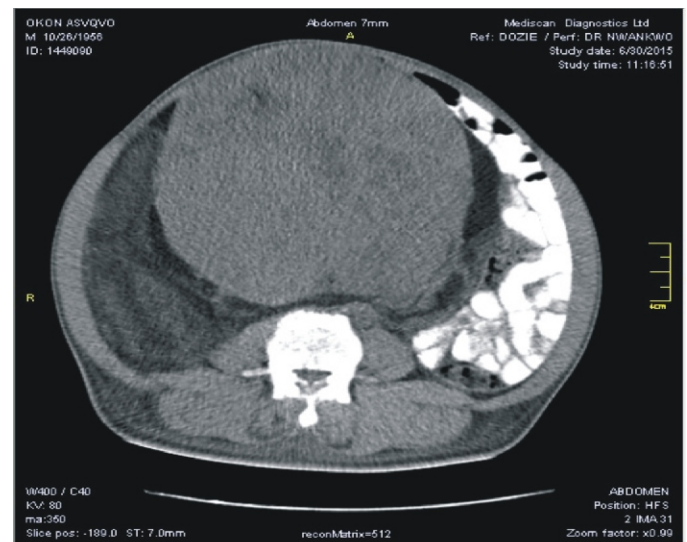
On examination at presentation, he was chronically ill-looking and pale with a weight of 48kg and bilateral pitting pedal edema. His blood pressure (BP) was 150/80mmHg, while his pulse and respiratory rates were 112bpm and 20cpm respectively.

His abdomen was distended with an obvious

intra-abdominal mass that was firm in consistency measuring about 30cm by 36 cm in widest diameters. The mass was not a hepatic, splenic or renal mass. There was associated ascites.

There were no significant findings on respiratory examination and other systems findings were essentially normal.

A diagnostic paracentesis revealed straw colored peritoneal fluid which was AFB smear test was positive. The abdominal ultrasound showed well circumscribed homogenous intra-abdominal mass measuring 32 by 38 cm in widest diameters while the Abdominal CT scan (Figure 1 & 2) showed a large abdominal mass likely matted lymph node with omental oedema and right sided hydronephrosis due to extrinsic pressure.



## Figures 1 and 2. Abdominal CT Scan showing the intraabdominal mass

The chest X-ray was a normal study. The patient's erythrocyte sedimentation rate (ESR) was >150mm/h, while Hemoglobin was 8g/dl with a lymphocytosis on blood count. He was HIV 1 & 11- Seronegative. His fasting blood sugar was 14mmol/l.

A diagnosis of abdominal Tuberculosis with abdominal lymphadenopathy was made. The patient was commenced on first line anti tuberculosis regimen of rifampicin, isoniazid, pyrazinamide and ethambutol in line with the National guidelines for tuberculosis treatment<sup>12</sup> with a 2 months intensive phase and 4 months continuation phase with isoniazid and rifampicin under DOTs supervision at the DOTs centre in our hospital. Patient's diabetes mellitus was controlled with insulin.

The treatment was monitored with abdominal girth, repeat ultrasonography, Hemoglobin, ESR and weight trends. Within the first four weeks of treatment the patient's weight improved from 48kg to 56kg, abdominal girth reduced from 106cm to 84cm while ESR reduced from >150mm/hr to 48mm/hr. A repeat abdominal scan revealed a reduction in abdominal mass. The patient completed the treatment regimen under DOTs and was declared cured.

## DISCUSSION

In spite of the global reduction in prevalence of abdominal Tb there has been a recent increase in the incidence of Abdominal Tb in developing countries.<sup>1-3</sup> This recent upsurge which has been reported by numerous studies,<sup>2,4,5</sup> has been associated with HIV infection which increases the risk of extra-pulmonary Tb.<sup>1,4,5,9</sup>

Other risks for the observed upsurge is the increasing number of multidrug-resistant strains of *M. Tuberculosis*<sup>1</sup> and the use of unpasteurized milk in some low resource countries<sup>13</sup>. The patient in this report took unpasteurized milk and this may be the major

risk for the development of abdominal tuberculosis from *M Bovis* in the patient as he was HIV negative.

Other risk factors for abdominal Tb which have been reported in other studies<sup>6,14</sup> include diabetes mellitus, liver cirrhosis and end stage renal disease. Chou et al<sup>6</sup> in Taiwan reported diabetes as the risk factor in 8.8% of patients their study. They<sup>6</sup> also noted that patients with diabetes had more positive AFB from their abdominal samples. The patient in this report was diabetic and had a positive AFB test from his ascitic fluid in keeping with the observations of Chou et al.

The presence of diabetes mellitus which is an immunosuppressive state in this patient may have been the major risk for the development of the disease as the features occurred after his diabetic diagnosis.

Abdominal Tb can be seen in all ages and socio-economic groups with an equal sex incidence, in spite of reports of higher female prevalence.<sup>2,15</sup> It is however thought to be more common in young adults between ages 21-40 yrs and at age 50-55yrs for white patients.<sup>2,15</sup> This view has been supported by the reports of Ohanaka et al<sup>16</sup> in Benin Nigeria who reported an age range of 20-55 years, mean age of 30yrs and a female to male ratio of 7:1. Akinkuolie et al<sup>17</sup> from south west Nigeria reported a mean age of 28 years and female to male ratio of 1.22:1; while Chou et al<sup>6</sup> in Taiwan reported a mean age 55years and a female to male ratio of 1.26:1. The patient in this study was a middle aged man.

The presentation of abdominal tuberculosis varies as it can affect any structure in the abdomen from the peritoneum, lymph nodes, intestines and organs like the liver or spleen.<sup>2,15</sup> Abdominal Tb is thus considered as a great mimic for many abdominal conditions and can therefore result in misdiagnosis if not suspected.<sup>2,7,8,15</sup> A variety of studies<sup>2,6, 15-18</sup> have shown that Abdominal pain, abdominal fullness, anorexia, ascites, fever and weight loss are the common symptoms in abdominal

tuberculosis. Other features which may be present are symptoms of an acute abdomen, chronic diarrhoea, abdominal distention and large intraabdominal mass.<sup>2,6,11,18</sup> Our patient presented with progressively increasing abdominal swelling, weight loss, low grade fever and night sweat which are some of the key features in abdominal Tb.

The challenge in making an accurate clinical diagnosis of abdominal Tb may result in delayed diagnosis with the attendant consequences of morbidity and mortality.<sup>2,6,8,15</sup> Therefore a high index of suspicion, good clinical evaluation and the use of surgical<sup>9,18,19</sup> radiologic<sup>10,20</sup> microbiological and histologic<sup>2,9,17</sup> tools should be utilized to arrive at the diagnosis when it is suspected.

The patient in this report had key elements in his history such as the use of unpasteurized milk in addition to the clinical features of fever, weight loss and night sweats which increased the suspicion. The use unpasteurized milk was the key etiologic factor in this patient especially in the absence of any pulmonary involvement to suggest a secondary infection process. It has been found that many patients with abdominal Tuberculosis may have coexisting pulmonary disease, however the presence of abnormal chest radiographs are not always indicative of active disease as has been shown in many studies. A report by Nail<sup>14</sup> indicated that while abnormal chest radiograph was found in 48% of cases only 14% of the subjects had active pulmonary tuberculosis. Akinkuolie et al<sup>17</sup> in Nigeria also reported that though 25% of patients in their series had abnormal chest x-rays only 14.3% had active pulmonary disease; a similar trend was also documented by Chou et al<sup>6</sup> in Taiwan where 47% had abnormal chest xrays while only 23% had active disease. Abdominal tuberculosis may thus occur in the absence of active pulmonary disease as seen in our patient.

The history, aetiologic factors and the pattern of presentation of our patient with large conglomerate of lymphodal masses explains

the absence of any pulmonary involvement as the presence of hypertrophic tubercular lymphadenopathy suggests drainage to the mesenteric and omental nodes as a result of primary ingestion of mycobacterium bovis from unpasteurized milk.<sup>10</sup>

Other ancillary investigations such as full blood count, ESR and serum albumin which may show anaemia, lymphocytosis and hypoalbuminemia may also give a non specific pointer to the presence of Tb. The patient in this case had anaemia, lymphocytosis and markedly elevated ESR. The elevation of ESR in abdominal Tb patients has also been reported in a series from Nigeria<sup>17</sup> where 89% of the subjects had elevated ESR. An elevated ESR may therefore be an supplementary pointer to the presence of abdominal tuberculosis in patient with abdominal features of uncertain etiology.

Radiologic evaluation is also important in making a diagnosis of abdominal tuberculosis.<sup>10</sup> A management algorithm<sup>10,21</sup> for abdominal Tb suggest the use of abdominal ultrasound as an initial screening test followed by contrast enhanced CT scan when ultrasound does not indicate a significant finding<sup>10,20</sup> The simple abdominal ultrasound can show ascites, peritoneal involvement and the presence of enlarged lymph nodes and masses or enlargement from other organs while the CT Scan can give more detail to ultrasound findings and even identify abnormalities that ultrasound may miss. The patient in this case had abdominal ultrasound and CT scan which identified a mass of lymphoid origin with complicating hydronephrosis. Other investigations such as contrast barium studies are also useful for intestinal tract disease.<sup>10</sup> Imaging studies also provide a guide for surgical procedures such as fine needle aspiration cytology(FNAC) and tissue biopsies which are needed to obtain tissue for bacteriologic and histological diagnosis. It is therefore advocated that radiologic modalities should be utilized optimally in cases where abdominal Tb is suspected in order to achieve a diagnosis.

Though ancillary and radiologic test are important in the diagnosis of abdominal tuberculosis they are not the gold standard or conclusive diagnostic tools, as it is important to employ bacteriological and histological tests which will identify the presence of AFB, Mycobacterium and the classic granuloma pattern of mycobacterium infection.<sup>2,10,15,17</sup> It is recommended that when samples are required for histologic and bacteriologic diagnosis methods which are less invasive should be utilized in order to avoid needless laparotomy.<sup>2,9,10,15</sup> The non invasive procedures might include a diagnostic paracentesis of ascitic fluid for macroscopic, chemical and bacteriologic analysis. Tubercular ascitic fluid usually has protein more than 3 g/dL, with a total cell count of 150-4000/ $\mu$ L and consists predominantly of lymphocytes.<sup>10</sup> The ascitic fluid to blood glucose ratio is less than 0.96 and serum ascitic albumin gradient is less than 1.1 g/dL.<sup>10</sup> The identification of AFB in ascitic fluid on smear and culture is low as staining for acid fast bacilli is positive in less than 3% of cases and a positive culture is seen in only 20% of cases.<sup>10</sup> The patient in this report had positive AFB smear of his ascitic fluid indicating the presence of mycobacteria. The fact that the patient was diabetic may also have increased the chance of a positive AFB smear as reported in another study<sup>6</sup> where diabetes was a positive factor for the identification of AFB in ascitic fluid. Another study in Nigeria<sup>17</sup> also reported a higher rate of 29% positive AFB sample in ascitic fluid for patients with abdominal tuberculosis. These results indicate that ascitic fluid analysis should be performed in all patients with abdominal Tb and ascites.

A culture of the ascitic fluid was not done in this study due to absence of a functional Tb culture reference laboratory at our center and the average turnaround time culture results which is 8-12 weeks<sup>12</sup>. Other tests which can be performed on ascitic fluid include adenosine deaminase (ADA) levels which are elevated in tubercular ascites with serum ADA level above 54 U/L, ascitic fluid ADA level above 36 U/L and an ascitic fluid to serum ADA ratio more

than 0.98.<sup>10</sup> It should however be noted that in cases of co-infection with HIV, ascitic ADA levels can be normal or low and falsely high values can be seen in malignant ascites. There was no capacity to perform ADA in our center.

Other tests which can be carried out to obtain tissue and samples in abdominal Tb include a peritoneoscopy, laparoscopy, peritoneal biopsy and FNAC of lymph nodes or masses. The histology from these samples is expected to show the classic caseous granuloma of tuberculosis. The above methods are useful as the identification of AFB and histological patterns suggestive of Tb granuloma provide some certainty as to the bacterial etiology especially in low resource settings like ours where the capacity for culture and other genetic based testing to identify Tb is limited. This therefore makes it imperative for the use of other diagnostic tools which include genetic testing like gene Xpert-RIF and LPA in Nigeria beyond the current limited use of these tools for sputum samples in pulmonary Tb. We therefore advocate that testing for Xpert-RIF in Nigeria should be expanded to include other biologic samples like ascitic fluid in order to improve the diagnostic yield and capacity in abdominal Tb.

Once abdominal Tb is diagnosed early treatment should be commenced in order to prevent complications and reduce mortality. Treatment should be commenced using the standard regimen for susceptible extrapulmonary tuberculosis in the country<sup>12</sup> consisting of rifampicin, isoniazid, ethambutol, and pyrazinamide in the intensive phase and a continuation phase of isoniazid and rifampicin. Patients with drug resistant abdominal Tb should be managed in line with the regimen for drug resistant tuberculosis in the country.<sup>22</sup> All patients should be under Directly observed therapy (DOT) as it ensures good treatment outcome.

In conclusion abdominal Tb still remains a disease which should be kept in mind and considered by clinicians in Nigeria as it is a great mimic and may be hard-to-diagnose. A

high index of suspicion and the use of ancillary, radiologic and surgical techniques should be employed in order to make a correct and prompt diagnosis.

## REFERENCES

1. WHO. Global tuberculosis report 2014. WHO/HTM/TB/2014.08
2. Kapoor VK. Abdominal tuberculosis. *Postgrad Med J* 1998;74:459-467
3. Amber AG, Unsup K. The Reappearance of abdominal tuberculosis. *Surg. Gynecol. Obstet.* 1991;172:432-6
4. Dim CC, Dim NR. Trends of tuberculosis prevalence and treatment outcome in an under-resourced setting: The case of Enugu state, South East Nigeria *Niger Med J.* 2013;54(6): 392–397.
5. Affusim CC, Kesieme E, Abah VO. The Pattern of Presentation and Prevalence of Tuberculosis in HIV-Seropositive Patients Seen at Benin City, Nigeria. *ISRN Pulmonology* 2012;Article ID 326572:6pagesdoi:10.5402/2012/326572
6. Chou C-H, Ho M-W, Ho C-M, Lin P-C, Weng C-Y, Chen T-C, et al. Abdominal Tuberculosis in Adult: 10-Year Experience in a Teaching Hospital in Central Taiwan. *J Microbiol Immunol Infect* 2010;43(5):395–400.
7. Hossein J, Mindelzun RE, Olcott W, Levitt D.B. Still the great mimicker: Abdominal tuberculosis. *AJR* 1997; 168:1455-60.
8. Mbata GC, Chukwuocha C, Nwadike VU, Egejuru RO, Nweke IG, Ibiam FA. Abdominal tuberculosis: Often an eluded diagnosis. *Global Advanced Research Journal of Medicine and Medical Sciences* 2013; 2(9): 204-206.
9. Samaila MOA, Oluwale OP. Extrapulmonary tuberculosis: Fine needle aspiration cytology diagnosis. *Nigerian Journal of Clinical Practice* 2011;14(3):297-299.
10. Debi U, Ravisankar V, Prasad KK, Sinha SK, Sharma AK. Abdominal tuberculosis of the gastrointestinal tract: Revisited. *World J Gastroenterology* 2014;20(40): 14831-14840.
11. Yağmurlu A, Tolasa G, Yağmurlu B, Gökçora HI, Dinda H. Abdominal Tuberculosis Mimicking Malignancy: A Case Report. *Journal Of Ankara Medical School* 2002;24(2):91-94.
12. FMOH:NTBLCP. Guidelines for the Management and Control of Tuberculosis in Nigeria. FMOH 2011
13. CDC. Human Tuberculosis caused by *Mycobacterium bovis*. National Centre for HIV/AIDS, STD and TB prevention. CDC.<http://www.cdc.gov.tblink/tboffices>. Accessed August 2015.
14. Niall O.A. Abdominal tuberculosis. *World J. Surg.* 1997;21:492-9.
15. Sharma MP, Bhatia V. Abdominal Tuberculosis. *Indian J Med Res* 2004;120: 305-315.
16. Ohanaka CE, Egbagbe EE. Adult Abdominal Tuberculosis in Benin City Nigeria. *Sahel Medical Journal* 2004; 7(4): 126-128.
17. Akinkuolie AA, Adisa AO, Agbakwuru EA, Egharevba PA, Adesunkanmi AR. Abdominal tuberculosis in a Nigerian teaching hospital. *Afr J Med Med Sci* 2008; 37(3):225-9.
18. Dauda MM, Ahmed A, Okpapi JU, Ahmed SA, Randawa AJ, Mukhtar HM. Abdominal Tuberculosis in Surgical Practice in Northern Nigeria. *Nigerian Journal of Medicine* 2010;19(4):415-418.
19. Clifford YK, Schmit PJ, Petrie B, Thompson JE. Abdominal tuberculosis: The surgical perspective. *The American Surgeon* 1996;62(10):8658.
20. Ab Del Bagi M, Karawi AA. Ultrasound diagnosis of “Dry Type” ileocecal tuberculosis: A case report. *Hepatogastroenterol* 1997:1033-6.
21. Sood R, Sethu Madhavan M. Diagnostic approach to abdominal tuberculosis. In: Agarwal AK, Jain DG, editors. *Clinical Medicine: A Practical manual for students and practitioners*. India: Jaypee Brothers Medical Publishers (P) Ltd, 2007: 249.
22. FMOH:NTBLCP. Guidelines for the Clinical and programmatic Management and Control of Drug Resistant Tuberculosis in Nigeria. FMOH 2011