

Pectus Excavatum in an 18 Month Old Male

Type of Article: **Case Report**

Dr Lucy Eberechukwu. Yaguo Ide, Dr Tochi Ada Uchenwa-Onyenegecha

Department of Paediatrics and Child Health, University of Port Harcourt Teaching Hospital. Port Harcourt, Rivers State, Nigeria.

ABSTRACT

BACKGROUND

Pectusexcavatum is uncommon in children; with an incidence of 1 in 400-1000. It is also a rare presentation of pulmonary tuberculosis in children. There is paucity of reports on cases of pulmonary tuberculosis in children presenting with pectusexcavatum in our environment. It is on this background that we report a case of pulmonary tuberculosis with pectusexcavatum in an 18month old male.

METHODS

The case records of an 18 month old male and a review of the literature on the subject, through google, Medline and PubMed search was utilised.

RESULT

An 18month old male presented with chest in-drawing, and pectusexcavatum of 6month duration. Investigations done revealed that he had pulmonary tuberculosis. He was commenced on anti TB drugs and made remarkable improvement.

CONCLUSION

Cases of pulmonary tuberculosis with pectusexcavatum are not common in children. A high index of suspicion will be needed to make an early diagnosis. Pulmonary Tuberculosis should be considered in children presenting with pectusexcavatum.

KEYWORDS: *Pectusexcavatum; Pulmonary Tuberculosis; Children.*

Correspondence: *Dr L.E. Yaguo Ide*
Email: *lucyaguolucy@gmail.com*

INTRODUCTION

Pectusexcavatum is a depression of the anterior chest wall of variable severity, which may be mild moderate or severe¹. All variations of depth, symmetry and breadth of the deformity may be seen. It may be small in diameter and deep, cup shaped or of large diameter and shallow, saucer shaped or eccentric.¹ It is uncommon in children, and occurs in approximately 1 of every 1000 children.¹ It has been reported to be rare in African population^{1,2}, and is five times commoner in males than females². Patients with pectusexcavatum are often dismissed by physicians as having an inconsequential problem, however it can be more than a cosmetic deformity. Severe cases can cause cardiopulmonary impairment and physiologic limitations. Pectusexcavatum is a rare presentation of pulmonary tuberculosis and there is a paucity of information on cases of children with pectusexcavatum and pulmonary tuberculosis. We report this case of a young boy with pulmonary tuberculosis and pectusexcavatum to highlight that pulmonary tuberculosis should be considered in children presenting with pectusexcavatum in our environment.

CASE REPORT

An 18month old male presented to our hospital with chest in-drawing of 6month duration. No

history of trauma to the chest, no history of chest pain or discomfort as child still went about his daily activities, with no history of cough, fever or weight loss.

Examination findings at presentation revealed a pectusexcavatum deformity with intercostal and subcostal recession (Figure 1). The respiratory rate was 32cycles per minute. Other physical examination findings were normal.

A diagnosis of pectusexcavatum of unknown cause with a probability of Vitamin D deficiency with Harrison's sulcus was made. The result of serum calcium (2.5mmol/l), serum magnesium (1.1mmol/l) and inorganic phosphate (1.6mmol/l) were all within normal limits making Vitamin D deficiency an unlikely cause.

The report of the patient's Chest X ray showed perihilar and bibasal mottled opacity, soft tissue density mass with a lobulated outer margin at the right hilum suggestive of bronchopneumonia and hilar lymphadenopathy. (Figure 2). Full blood count done revealed packed cell volume of 32%, leucocytosis of $13.1 \times 10^9/L$ with Absolute lymphocytosis of 86%, neutrophil count of 10%, Eosinophil count of 03%, blast of 01% and a raised ESR of 20mm/hr. Blood film showed reactive Lymphocytosis secondary to a chronic inflammation probably viral infection. The Mantoux test was 15mm positive.

A diagnosis of Pulmonary Tuberculosis was then made based on TB Scoring of 10 in this child – positive mantoux score 3, duration of illness of over 4weeks score 3, chest x-ray with presence of hilar lymphadenopathy score 3, and a father with positive mantoux stillbeing investigated 1. (TB score of 7 and above indicates a high likely hood of tuberculosis in children). An acid fast bacilli was not done as this 18month old child cannot produce sputum, in addition the yield is also known to be low (less than 20%) even in the older children who are able to produce sputum³. The patient was then commenced on anti-

Tuberculous drugs regimen consisting of Rifampicin at a dose of 10mg/kg/day, isoniazid at 10mg/kg/day and pyrazinamide at 25mg/kg/day. Pyrazinamide was stopped after two months. Following the diagnosis of pectusexcavatum in a child with tuberculosis he was referred to the orthopedic unit where he was seen and repeat chest x-ray, 2D Echocardiogram and Electrocardiogram requested. The investigations were done and reports were normal (Figure 3). Contact tracing was also initiated as all adult family members were asked to do mantoux test and chest x-ray. The father's mantoux test result was 11mm positive, he was then referred to the DOTs unit for further evaluation and care.

The patient has completed 9 months of intensive and continuation phase of anti-tuberculosis therapy with rifampicin and isoniazid. The repeat and interval repeat chest x-rays done at three months showed significant interval change indicating resolution of the tuberculous pneumonia (Figure 4). The child weight and other anthropometric and haematological parameters also indicate a resolution. No significant change has been observed in the pectusexcavatum. The patient did not experience any significant drug adverse effects in the course of treatment. He is still undergoing regular follow up at the paediatric and orthopedic clinic.



Figure 1: Showing Pectus Excavatum deformity

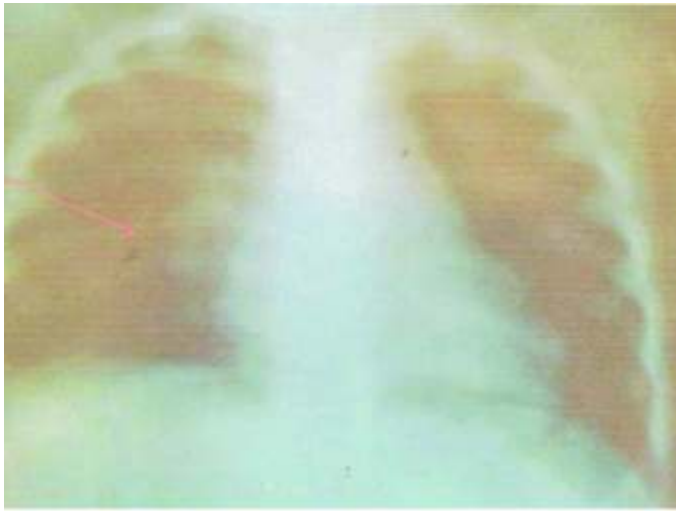


Figure 2: Chest Radiograph, showing hilar adenopathy and opacities

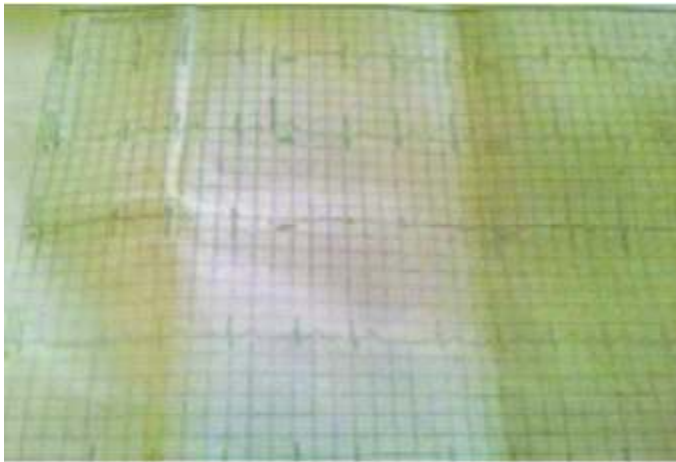


Figure 3: ECG showing normal study

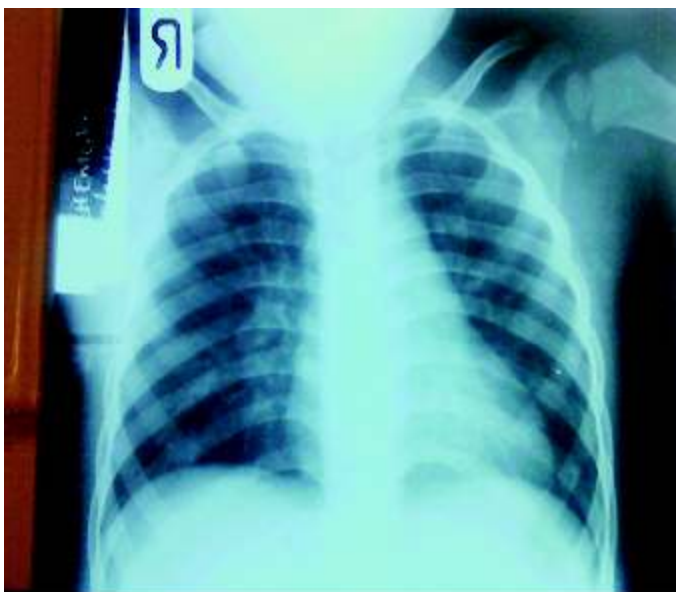

Figure 4: Chest X-Ray Taken After 3 months Of Treatment

DISCUSSION

Pectusexcavatum with pulmonary tuberculosis in children is uncommon. In a case series reported by Iseman et al⁴ among 67 patients with Pulmonary Mycobacterium AviumComplex(MAC) and 55 patients with Pulmonary Mycobacterium Tuberculosis(M.Tb), pectusexcavatum was present in 27% of those with MAC while only 5% of those with M.Tb had pectusexcavatum. Pectusexcavatum is typically noticed at birth and more than 90% of cases are diagnosed within the first year of life and usually progresses as the child grows.⁵Our patient's case was noticed at 12months of age. Pectusexcavatum has been documented to be more common in males than females.^{1,2} Our patient was a male.

The aetiology of Pectusexcavatum is uncertain but familial tendencies have been found in clinical experience where it may be seen in more than one sibling,⁵ it is commonly associated with connective tissue disorders such as Marfan syndrome and Ehlers Danlos syndrome and can also occur as an only abnormality⁵.In a Pedigree analysis of 34 families by Creswick et al⁵, there was evidence that pectusexcavatum is an inherited disorder possibly of connective tissue, although some families demonstrated apparent Mendelian inheritance , most appeared to be multifactorial. Our patient however did not have any associated syndrome or family history of Pectusexcavatum.

Patients with pectusexcavatum may present with signs and symptoms with varying severity.^{1,2,6} The most consistently experienced symptoms are dyspnoea with exercise and loss of endurance, other symptoms may include chest pain with activity, progressive fatigue, palpitations, tachycardia, exercise induced wheezing, frequent upper respiratory tract infection, fainting, exercise intolerance, dizziness etc^{1,2,6}. Many patients are however asymptomatic at a younger age but start experiencing symptoms as they enter their teens^{1,2,6}.Our patient was dyspnoeic (had intercostal and subcostal recession) at

presentation. Studies have shown that common physiological effects of Pectusexcavatum include pulmonary and cardiac effects.^{7,8} Some authors have shown significant compromise of cardiac and pulmonary function^{6,7}, whereas others have not been able to demonstrate any change.⁹

Pulmonary effects include restrictive lung disease caused by decreased intra-thoracic capacity, atelectasis caused by cardiac displacement causing left lung compression, and paradoxical respiration in severe cases caused by disturbed mechanical forces⁶.

Cardiac effects include reduced cardiac output, mitral prolapse, murmurs and arrhythmias⁶.

Psychosocial issues surrounding body image among patients with pectusexcavatum can be significant and occasionally life threatening^{6,10}; this makes the need to evaluate these patients properly and correct the deformity before it affects their ability to function normally a priority.

The management of a patient with pectusexcavatum requires a thorough work up to ascertain the significance of the deformity and determine the need for referral to surgeons for surgical repair. Radiological imaging includes a non-contrast tomographic scan of the chest to assess the deformity of the bony and cartilaginous skeleton in a 3 dimensional way and also reveal any cardiac compression. Magnetic resonance imaging of the chest may also be done instead of CT scan to reduce radiation exposure but bony detail is better seen with CT Scan^{6,11}. An index of severity can be calculated by dividing the transverse diameter by the anteroposterior diameter of the chest wall (at the lowest part of the defect). In general an index ≥ 3.1 is severe^{6,11,12}. A 12 lead electrocardiogram can be done to document any dysarrhythmia⁶.

Echocardiography may be useful to reveal any abnormalities in the cardiac structures. Pulmonary function tests should be done in

patients who are old enough to cooperate with the testing. Chest X ray, mantoux test and full blood count should also be done to rule out pulmonary tuberculosis in patients with pectusexcavatum.

Surgical repair of pectus has evolved in the past years and can now be performed safely with minimal risk when indicated. The indications for surgical repair include two or more of the following :CT index of ≥ 3.1 , cardiology evaluation where the compression is causing cardiac displacement, murmurs or conduction abnormalities on ECG tracings or echocardiogram, documentation of progression of the deformity with associated physical symptoms other than isolated concerns of body image and history of failed previous repair^{1,6,13}. Children who do not have indications for surgical repair as indicated above should be followed up closely to watch for progression or worsening of defect and symptoms as they age. Our patient falls into this category as he is currently just followed up at the orthopaedic clinic after the review of his ECG, Echo and chest X-ray were found to be normal.

The timing for surgery in young children is problematic. Currently most surgeons will wait for patients to reach the adolescence or early teenage years to perform repair^{6,13}.

Conclusion/recommendation

The paediatricians need to have a good understanding of pectusexcavatum and realize the importance of the deformity. Pulmonary tuberculosis should be considered in children with pectusexcavatum so that anti tuberculous drugs can be commenced early when indicated. Referral for consideration of surgical treatment should also be done for severe cases as surgical correction can be performed safely with minimal risk where indicated.

REFERENCES

1. Goretsky MJ, Kelly RE, Croitoru D, Nuss D. Chest wall anomalies: Pectusexcavatum and carinatum.

- Adolesc Med 2004;15:455-471.
2. Fojin AA, Steuaerwald N, Ahrens WA, Allen KE. Anatomical, histologic and genetic characteristics of congenital chest wall deformities. *Semin Thorac Cardiovasc Surg* 2009;21:44-57.
 3. STOP TB Partnership TB REACH, German Leprosy, Relief Association, NIGERIA. Wave 3 project: score chart for diagnosis of TB in children.
 4. Iseman MD, Buschman DL, Ackerson LM. Pectusexcavatum and scoliosis. Thoracic anomalies associated with pulmonary disease caused by *Mycobacterium avium* complex. *Am Rev Respir Dis* 1991;144:914-916.
 5. Creswick HA, Stacey MW, Kelly RE Jr, Gustin T, Nuss D, Harvey H et al. Family study of the inheritance of pectusexcavatum. *J PediatrSurg* 2006;41:1699-1703.
 6. Jaroszewski D, Notrica D, Mc Mahon L, Steedly DE, Deschamps C. Current management of pectusexcavatum. A review and update of therapy and treatment recommendations. *J Am Board Fam Med* 2010;23:230-239.
 7. Zhaa L, Feinberg MS, Gaides M, Ben-Dov I. Why is exercise capacity reduced in subjects with pectusexcavatum? *J Pediatr* 2000;136:163-167.
 8. Mocchegiani R, Badano L, Lestuzzi C, Nicolosi GL, Zanuttini D. Relation of right ventricular morphology and function in pectusexcavatum to the severity of chest wall deformity. *Am J Cardiol* 1995; 76:941-946.
 9. Haller Jr JA, Peters GN, Mazur D, White JJ. Pectusexcavatum :a 20year surgical experience. *J ThoracCardiovascSurg* 1970;60:375-83.
 10. Lawson ML, Cash TF, Akers R, Vasser E, BurkiB, Tabangin M et al. A pilot study of the impact of surgical repair on disease specific quality of life among patients with pectusexcavatum. *J PediatrSurg* 2003;38:916-918.
 11. Haller Jr JA, Krammer SS, Lectman SA. Use of CT scans in selection of patients for pectusexcavatum surgery : a preliminary report. *J PediatrSurg* 1987;22:904-908.
 12. Cahill JL, Lees GM, RoberTson HG. A summary of preoperative and postoperative cardiopulmonary performance in patients undergoing pectusexcavatum and pectuscarinatum repair. *J PediatrSurg* 1984;19:430-433.
 13. Fonkalsrud EW. Current management of pectusexcavatum. *World J Surg* 2003;27:502-508.