

Hurthle cell tumor of the thyroid gland: Report of a rare case and review of literature

PCN Okere, DB Olusina¹, MO Enyinnah²

Departments of Radiation Medicine, ¹Morbid Anatomy, University of Nigeria Teaching Hospital, Enugu, ²Surgery, Federal Medical Centre, Umuahia, Nigeria

Abstract

This article presents a case of Hurthle cell adenoma (HCA) of the thyroid gland with a review of literature on Hurthle cell tumors. This case presented is that of a 57-year-old woman with a recurrent thyroid swelling. She previously underwent a right hemithyroidectomy for thyroid mass 10 years prior. A left lobectomy was done and microscopic examination revealed a HCA of the thyroid. The patient was discharged on thyroid replacement therapy and has remained healthy after more than 24 months of follow-up. The literature review highlights the criteria for diagnosis, the role of imaging and fine needle aspiration cytology (FNAC) in preoperative diagnosis.

Key words: Goiter, Hurthle cell, thyroid tumors

Date of Acceptance: 09-Jul-2013

Introduction

Hurthle cell tumors of the thyroid are rare neoplasm accounting for less than 5% of all thyroid tumors.^[1] Hurthle cell tumors have been called Askanazy cell tumors,^[2] oncocytoomas, and mitochondriomas or oxyphil tumors. They have been found in association with various benign thyroid conditions like Hashimoto's thyroiditis, hyperthyroidism, nodular goiter, and thyroid neoplasms; where they often represent oncocyctic metaplasia.^[3] While tumor-size has been canvassed as predictive of malignancy or benignity,^[4-7] Hurthle cell tumors remain interesting diagnostic phenomena with acknowledged preoperative and intraoperative difficulties in discriminating adenomas from carcinomas.^[8] In addition, the behavior of Hurthle cell neoplasms are unpredictable,^[4,9] while equally unsettled is the natural history of the tumors and optimal treatment options. Additional to difficulty in tissue diagnosis, Hurthle cell neoplasms also have no specific imaging characteristics.

presented with recurring progressively increasing neck swelling of 5 years duration. There were no associated pain or pressure symptoms. Her voice was not hoarse and she did not provide any history suggestive of thyrotoxicity or hypothyroidism. She also did not give a positive family history of neck swelling. Ten years prior to this presentation, she had undergone a right hemithyroidectomy for a thyroid mass. No histology report on the thyroidectomy specimen was available and there was no history of irradiation to the head or neck. Five years after the surgery she noticed a recurring and progressive swelling of her neck in the thyroid area.

On examination, she was healthy-looking, with no features of thyrotoxicity or hypothyroidism. Her pulse and blood pressure were within normal range for age and gender. The neck showed a collar crease scar from the previous right hemithyroidectomy as well as left-sided nontender goiterous swelling with a firm, smooth consistency and measuring about 10 × 6 cm. No regional lymph nodes were palpated and there was slight tracheal deviation to the right.

Case Report

CS is a 57-year-old grandmultiparous housewife who

Address for correspondence:

Dr. Philip CN Okere,
Department of Radiation Medicine, University of Nigeria Teaching Hospital, Enugu - 400 001, Nigeria.
E-mail: pcnokere@yahoo.com

Access this article online

Quick Response Code:	Website: www.njcponline.com
	DOI: ***
	PMID: *****

A clinical diagnosis of recurrent goiter was made; this time left-sided.

Laboratory indices which were normal included thyroid function tests, full blood count, serum electrolytes, urea and creatinine, and serum calcium and phosphate. Also normal were her fasting blood sugar and erythrocyte sedimentation rate. Retroviral screening for antibodies to human immunodeficiency virus (HIV) I and II was nonreactive. The X-ray of the soft tissue neck and thoracic inlet was reported as simple goiter of left lobe of the thyroid with no retrosternal extension; chest X-ray revealed mild increase in cardiothoracic ratio. High frequency real-time ultrasonography revealed a goiterous left thyroid gland devoid of any intraglandular calcifications. No regional lymph nodes were seen. Doppler scan in duplex mode showed a goiterous mixed echoic mass with scattered signals peripheral to the mass. The right thyroid bed was empty and no lymph nodes were demonstrable. Fine needle aspiration cytology (FNAC) was not done and the reason for this was not stated.

On 27th July 2010, a left lobectomy was performed and a goiterous gland measuring 8 × 7 × 5 cm was removed. A grey-white nodule thought to be a lymph node and measuring 2 × 2 × 1.5 cm was removed over the right thyroid bed. Specimen was sent for histology. Microscopic examination showed benign proliferation of thyroid follicles. The epithelial cells composing the follicular adenoma were reported to be rich in oxyphilic cytoplasm [Figures 1 and 2] and had small regular nuclei. No capsular or vascular invasions were demonstrable in the sections. The histological diagnosis was Hurthle cell adenoma (HCA) of the thyroid.

Postoperative period was uneventful and patient was discharged on the 3rd day post surgery on thyroid replacement therapy (100 µg thyroxine daily). Patient was healthy after more than 24 months and follow-up continues.

Discussion

Hurthle cells are also called oxyphil cells because they are composed predominantly of thyroglobulin-producing, mitochondria-rich thyroid epithelial cells^[10] which confer the granular, pink cytoplasm. These tumors are rare^[11] and to the best of the knowledge of the authors, this is the first report from this environment. Hurthle cell neoplasms represent less than 5% of all thyroid tumors.^[11] Hurthle cells, apart from forming thyroid neoplasms, as in this patient, are associated with benign thyroid conditions like goiters and thyroiditis where they represent oncocyctic metaplastic changes.^[3] Majority of the tumors of Hurthle cells are benign, as seen in this patient, and are called HCAs. However, many are malignant (figures are up to 40%) and are called Hurthle cell carcinomas (HCCs).^[12] Hurthle cell tumors are

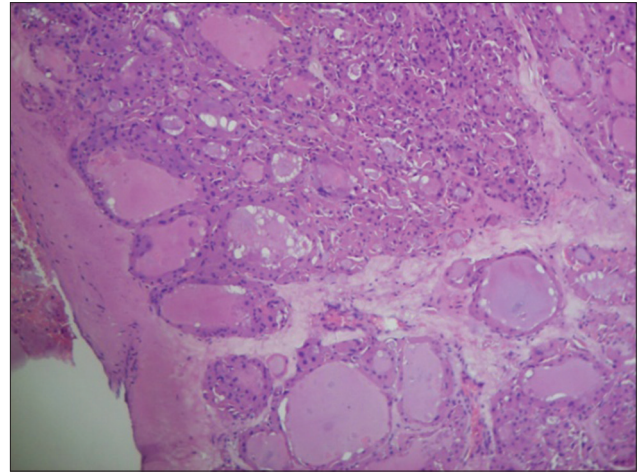


Figure 1: Hurthle cells within nodule forming follicles in section of thyroidectomy specimen (low power, hematoxylin and eosin). Note fibrous capsule

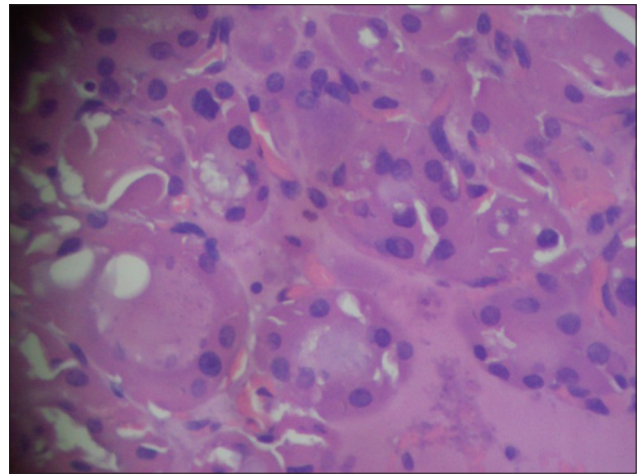


Figure 2: Section through Hurthle cell nodule (H and E, ×400)

interesting phenomena, not only because of the enduring debate about the true nature but also because HCCs are particularly aggressive,^[13] thereby making more vital, the task of differentiating the HCAs from the carcinomas.^[14] This differentiation impacts the operative intervention since majority of surgeons recommend thyroid lobectomy for HCAs while advocating total thyroidectomy for HCCs.^[15] Several authors have reported tumors initially diagnosed as HCAs which later recurred or metastasized.^[4,16] While recurrence is a feature of malignancy, and in the case here presented the patient had a right lobectomy 5 years before the clinical occurrence of the tumor, it is however impossible to judge if this constitutes a recurrence of disease as there was no histology report of the first biopsy to be seen, and the new lesion occurred in the contralateral side. The scenario of a multifocal HCA is not supported by antecedents in literature. In a series however, by Chen *et al.*,^[7] no patient with HCA had bilateral disease. However, they found on the other hand that 16% of those with HCC had bilateral foci which required total thyroidectomy. One patient with

HCA in his series had contralateral tumor which turned out to be follicular variant of papillary thyroid cancer.

In this case, prior to lobectomy, no attempt was apparently made to establish the character of the tumor by FNAC. Records did not state any reason why this was omitted. While several studies have shown that FNAC reliably recognizes Hurthle cell neoplasms,^[5,17-19] it cannot differentiate adenoma from carcinoma with certainty. The value of FNAC in our patient will remain painfully unknown since it was not done before the first and second lobectomies. Tumor size has been suggested by some workers^[4-7] to be predictive of malignancy. In this case, the tumor was above the accepted 4 cm threshold yet had histological features consistent with benign disease. Some have suggested that tumors of this type should be placed in an intermediate category;^[20] this would imply some latent malignant potential. It is however more plausible that a long tumor growth period and late presentation allowed this adenoma to attain a large size usually found in HCCs.

Evaluation of ultrasound and X-ray films in this reported patient did not show any specific features that would have allowed retrospective tumor characterization. Maizlin *et al.*,^[21] attempted to match sonographic appearance with histologic characteristics of 15 histologically proven cases of Hurthle cell neoplasms. They concluded that the pathologic criteria which differentiate benign from malignant Hurthle cell neoplasms for example capsular breach, vascular invasion extrathyroidal, and nodal involvement are beyond the resolution of sonography; thus precluding their usefulness in their characterization.

Conclusion

Hurthle cell neoplasms are rare tumors. Their biology is confounding and behavior unpredictable. Tumor-size of Hurthle cell neoplasms is an important preoperative index for predicting benignity. This index impacts on the choice doing either a total or hemithyroidectomy. While HCCs grow to comparatively larger sizes, late presentation however, may allow for large size in adenomas and may compound the paradigm of tumor size as predictor of malignancy. More local study that includes diligent follow-up of all thyroid specimen to histology are however required. Imaging modalities like ultrasound and plain radiography show nonspecific features and are thus unhelpful in preoperative distinction between HCA and carcinoma.

References

1. Stojadinovic A, Hoos A, Ghossein RA, Urist MJ, Leung DH, Spiro RH, *et al.* Hurthle cell carcinoma: A 60-year experience. *Ann Surg Oncol* 2002;9:197-203.
2. Tremblay G. Histochemical study of cytochrome oxidase and adenosine triphosphatase in Askanazy cells (Hurthle cells) of the human thyroid. *Lab Invest.* 1962;11:514-7.
3. Blaloch ZW, LiVolsi VA. Pathology of thyroid and parathyroid disease. In: Mills SE, Carter D, Reuter VE, Greenon JK, Oberman HA, Stoler MH, editors. *Sternberg's Diagnostic Surgical Pathology.* 4th ed. Philadelphia: Lippincott Williams and Wilkins; 2004. p. 578-9.
4. Thompson NW, Dunn EL, Batsakis JG, Nishiyama RH. Hurthle cell lesions of the thyroid gland. *Surg Gynecol Obstet* 1974;139:555-60.
5. Azadian A, Rosen IB, Walfish PG, Asa SL. Management considerations in Hurthle cell carcinoma. *Surgery* 1995;118:711-5.
6. Carcangiu ML, Bianchi S, Savino D, Voynick IM, Rosai J. Follicular Hurthle cell tumors of the thyroid. *Cancer* 1991;68:1944-53.
7. Chen H, Nicol TL, Zeiger MA, Dooley WC, Ladenson PW, Cooper DS, *et al.* Hurthle cell neoplasms of the thyroid gland: Are there factors predictive of malignancy? *Ann Surg* 1998;227:542-6.
8. Chen H, Udelsman R. Hurthle cell adenoma and carcinoma. In: Clark OH, Duh QY, editors. *Textbook of Endocrine Surgery.* Philadelphia: WB Saunders; 1997.
9. McLeod MK, Thompson NW. Hurthle cell neoplasms of the thyroid. *Otolaryngol Clin North Am* 1990;23:441-52.
10. Asa SL. My approach to oncocyctic tumours of the thyroid. *J Clin Pathol* 2004;57:225-32.
11. Barnabei A, Ferretti E, Baldelli R, Procaccini A, Spriano G, Appetecchia M. Hurthle cell tumours of the thyroid. Personal experience and review of the literature. *Acta Otorhinolaryngol Ital* 2009;29:305-11.
12. LiVolsi VA. Surgical pathology of the thyroid. In: Bennington JL, editor. *Major Problems in Pathology.* vol. 22. Philadelphia: W.B. Saunders; 1990. p. 357-63.
13. McHenry CR, Sandoval BA. Management of follicular and Hurthle cell neoplasms of the thyroid gland. *Surg Oncol Clin N Am* 1998;7:893-910.
14. Paphavasit A, Thompson GB, Hay ID, Grant CS, Van Heerden JA, Ilstrup DM, *et al.* Follicular and Hurthle cell thyroid neoplasms: Is frozen section evaluation worthwhile? *Arch Surg* 1997;132:674-8.
15. Chen HY, Benjamin LB, Chen MF. Hurthle cell tumor. *Int Surg* 1996;81:168-70.
16. Grant CS, Barr D, Goellner JR, Hay ID. Hurthle cell tumors of the thyroid: A diagnosis to be trusted? *World J Surg* 1988;12:488-95.
17. Wu HH, Clouse J, Ren R. Fine-needle aspiration cytology of Hurthle cell carcinoma of the thyroid. *Diagn Cytopathol* 2008;36:149-54.
18. McIvor NP, Freeman JL, Rosen I, Bedard YC. Value of fine-needle aspiration in the diagnosis of Hurthle cell neoplasms. *Head Neck* 1993;15:335-41.
19. Greaves TS, Olvera M, Florentine BD, Raza AS, Cobb CJ, Tsao-Wei DD, *et al.* Follicular lesions of the thyroid: A 5-year fine-needle aspiration experience. *Cancer* 2000;90:335-41.
20. Arganini M, Behar R, Wu TC, Straus F 2nd, McCormick M, DeGroot LJ, *et al.* Hurthle cell tumors: A twenty-five-year experience. *Surgery* 1986;100:1108-15.
21. Maizlin ZV, Wiseman SM, Vora P, Kirby JM, Mason AC, Filipenko D, *et al.* Hurthle cell neoplasms of the thyroid: Sonographic appearance and histologic characteristics. *J Ultrasound Med* 2008;27:751-7.

How to cite this article: ???

Source of Support: Nil, Conflict of Interest: None declared.