

# Leukemoid reaction associated with transitional cell carcinoma: A case report and literature review

H He, Z Zhang, J Ge, W Zhou

Department of Urology, Nanjing General Hospital of Nanjing Military Command, PLA, China

## Abstract

The goal of this article was to investigate the diagnosis, treatment and mechanisms of the leukemoid reaction (LKR) associated with transitional cell carcinoma. A 64-year-old male patient presented with anuria. Color ultrasound imaging revealed a large bladder tumor. Digital radiography and computerized tomography of the chest, abdomen and pelvis revealed only bilateral hydronephrosis, but did not reveal any metastasis. The pre-operative white blood cell count in the peripheral blood consistently increased to 58,400/mm<sup>3</sup> while neutrophil granulocyte count was 54,900/mm<sup>3</sup>, without fever. Radical cystectomy and construction of bilateral cutaneous ureterostomy was performed. The histological diagnosis was transitional cell carcinoma, Grade 3. Granulocyte colony-stimulating factor (G-CSF) staining was positive in tumor cells. Results: After surgery, the leukocyte value became nearly normal. At 3 months later, patient was admitted to our hospital with the complaints of the left leg edema, diagnosed as pelvic lymph node metastasis. Patient died of systemic metastasis within 6 months after the cystectomy. Bladder cancer associated with LKR, though rare, is considered highly malignant, difficult to diagnose and as having poor prog

**Key words:** Bladder cancer, immunohistochemistry, leukemoid reaction, lymphatic metastasis

**Date of Acceptance:** 28-Aug-2013

## Introduction

The term leukemoid reaction (LKR) describes an elevated white blood cell (WBC) count ( $>50 \times 10^9/L$ ) or leukocytosis that is a physiological response to stress or infection (as opposed to a primary blood malignancy, such as leukemia). A LKR is typically a response to an underlying medical issue such as drugs, Hemorrhage, infections, Asplenia, Diabetic ketoacidosis, Organ necrosis, etc., Bladder tumors are commonly seen in urinary surgery, but reports on LKR caused by bladder carcinoma are rare. One such patient was admitted to and treated recently at our hospital; the analytic report follows.

## Case Report

A 64-year-old male was admitted to our hospital 20 days after electroscission for bladder tumor recurrence with a chief complaint of anuria for 1 day. 3 years prior, he had

received cystoscopic examination for 1 month due to a painless gross total hematuria and a solitary waterweed-like neoplasm was discovered. He was diagnosed with a bladder tumor and treated with transurethral electroscission. The post-operative pathological report revealed a solitary uroepithelium carcinoma of the bladder (Degree II). Post-operative bladder irrigation with 30 mg mitomycin was performed once weekly for 6 weeks, then biweekly for 12 weeks and then once monthly for 2 years. He was rehospitalized for bladder tumor recurrence 20 days ago and was treated with electroscission for the bladder tumor. The post-operative pathological report showed invasive uroepithelium carcinoma of the bladder. He was discharged from the hospital after recovery. Hematuria appeared again and worsened and then he was anuric for 1 day prior to admittance. Ultrasonic examination in another hospital

### Address for correspondence:

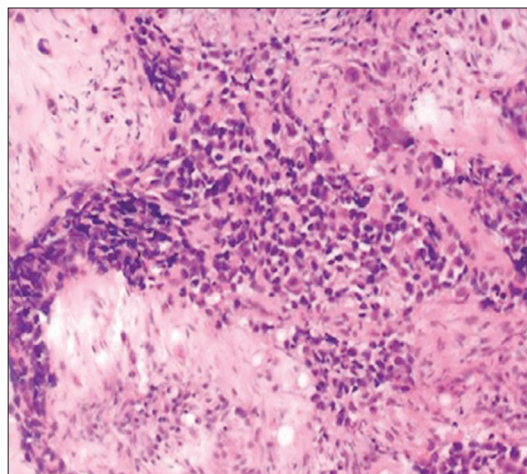
Dr. Wenquan Zhou,  
No. 305, East Zhongshan Road, Nanjing 210002, Jiangsu, China.  
E-mail: hehaowei1982@hotmail.com

### Access this article online

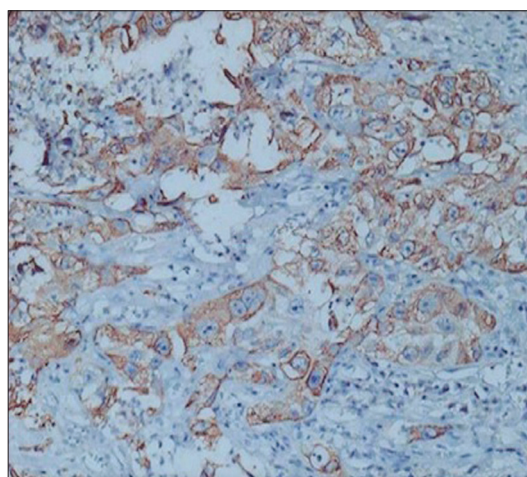
<b>Quick Response Code:</b>	<b>Website:</b> www.njcponline.com
	<b>DOI:</b> ***
	<b>PMID:</b> *****

revealed bilateral hydronephrosis and bilateral ureter expansion and he was readmitted to our hospital. Physical examination revealed body temperature was 37.1°C, pulse was 71 beats/min, respiratory rate was 16 breaths/min and BP was 122/83 mmHg. Palpation revealed no swollen superficial lymph nodes, no bulging in costal spinal angle and lumbar region, no percussion pain in bilateral costal spinal angle and no sign of psoas major stimulation. There was no tenderness or masses in the suprapubic region. Auscultation of the heart and lungs revealed no abnormality. Laboratory findings after admission were WBC count of  $26.2 \times 10^9/L$ , neutrophil count of  $23.0 \times 10^9/L$ , serum creatinine level of 1460  $\mu\text{mol/L}$ , granulocyte colony-stimulating factor (G-CSF) of 4032 ng/L, immunoglobulin (Ig) G 16.4 g/L, serum Igk light chain of 13.9 g/L, urine Igk light chain of 294 mg/L and urine IgY light chain of 234 mg/L. Pathological examination of bone marrow aspirated from the right anterior superior iliac spine revealed active proliferation of myeloid tissue and granulation hyperplasia. Color ultrasound examination of the abdomen revealed no obvious abnormality in the lymph nodes in the liver, gallbladder, spleen, pancreas and retroperitoneum. Computed tomography (CT) scanning revealed (1) local thickening in the posterior wall of the urinary bladder, which was considered possible evidence of recurrence after the bladder carcinoma operation; and (2) prostate calcification. Chest radiography revealed aortosclerosis and lung pleural thickening on both sides.

Immediately after admittance, ultrasound-guided percutaneous catheterized drainage for hydronephrosis of the right kidney was performed as emergency treatment. Laboratory examination revealed that serum creatinine decreased to 245  $\mu\text{mol/L}$  and the WBC count continued to rise (to a maximum of  $58.4 \times 10^9/L$ ) after the antibiotics treatment of 3 days as did the neutrophilic granulocyte count (to a maximum of  $54.9 \times 10^9/L$ ). The patient had no fever. Consultation with hematologists gave a diagnosis of LKR, after bone marrow aspiration and determination of the content of bone marrow deoxyribonucleic acid (DNA) to exclude the possibilities of infection and leukemia. Radical cystectomy and cutaneous bilateral ureterostomy were performed under general anesthesia. The post-operative pathological report showed invasive uroepithelium carcinoma of the bladder (Degree III) with involvement of every layer of the bladder and seminal vesicles. Metastasis was not found in the lower rectal margin of the bladder, bilateral ureters or adipose tissue lymph nodes [Figure 1]. Immunohistochemistry (IHC) revealed overexpression of G-CSF in cancer cells [Figure 2]. Examination 2 weeks after the operation revealed the WBC count was  $13.7 \times 10^9/L$  and the neutrophil count was  $9.8 \times 10^9/L$ . Patient presented with the left waist abdomen pain accompanies edema of the left lower limb 3 months after discharge. Laboratory examination showed the WBC count was  $44.5 \times 10^9/L$  and the neutrophil count was  $39.21 \times 10^9/L$ . CT scanning



**Figure 1:** Pathological section at low magnification ( $\times 100$ ) with H and E stain. Pathological report: Invasive uroepithelium carcinoma of the bladder (Degree III) with involvement of every layer of bladder and seminal vesicle



**Figure 2:** Pathological section at high magnification ( $\times 400$ ) with immunohistochemistry. Immunohistochemistry reveals overexpression of granulocyte colony-stimulating factor in cancer cells

revealed the possibility of lymph node metastasis within and behind the left iliacus. Left lower back pain and left lower limb edema were ameliorated after treatment with an argon-helium knife and reexamination showed a WBC count of  $39.0 \times 10^9/L$ , a neutrophil count of  $34.73 \times 10^9/L$  and appearance of juvenile cells. At 3 months after leaving the hospital, patient died of systemic metastasis.

## Discussion

LKR describes an elevated WBC count or leukocytosis that is a physiological response to stress or infection (as opposed to a primary blood malignancy, such as leukemia). The course can be either acute or chronic. Primary diseases may be acute or chronic infection, malignant cancer, hematological disorder, chemical injuries, etc., In terms of characterizing LKRs by cell type involved, there

are neutrophilic, eosinophilic, basophilic, monocellular, lymphocytic, erythroleukemic and mixed lineage LKRs, of which neutrophilic LKR is most commonly seen. Conventionally, a leukocytosis exceeding  $50,000 \text{ WBC/mm}^3$  with a significant increase in early neutrophil precursors is referred to as a LKR. The peripheral blood smear may show a mix of early mature neutrophil precursors, in contrast to the immature forms typically seen in acute leukemia. The bone marrow in a LKR, if examined, may be hypercellular, but is otherwise typically unremarkable. This is named leukocytosis neutrophilic LKR, which was seen in this case report. This disease should be differentially diagnosed with leukemia. In general, the major manifestation of LKR is abnormal serum WBC with restriction to one cell type, not involving erythrocytes or megakaryocytes; therefore, patients do not suffer from anemia or thrombocytopenia. Changes in the myelogram are not prominent and there are no symptoms of leukemia other than hyperplasia and left shift. In cellular morphology, toxic granulation and vacuoles often appear in LKR, without cell abnormalities. Primary diseases often exist and the hemogram values return to normal when the primary disease is treated. There is no tissue or organ invasion and neutrophil alkaline phosphatase (NAP) remains at a normal level or increases. In cases of leukemia, toxic granulation and vacuoles seldom appear and cell abnormalities exist in most cases, often with tissue and organ invasion and NAP decreasing or disappearing.

As early as 1973, Block and Whitmore<sup>[1]</sup> reported one case of bladder cancer accompanied by LKR, thrombocytopenia and hypercalcemia. Since then, 48 cases of bladder cancer with LKR have been reported in Japan and the disease was identified by high levels of invasion and metastasis. Its prognosis was extremely poor and life expectancy of most patients was less than 1 year.<sup>[2]</sup> In the case reported here, local recurrence and lymph node metastasis appeared 3 months after the operation. The patient died of systemic metastasis 6 months later. In 1990, Ito *et al.*<sup>[3]</sup> discovered that G-CSF may be produced in bladder cancer. In 1993, Satoh *et al.*<sup>[4]</sup> reported one case of squamous cell carcinoma of the bladder with leukocytosis, in which the count of WBC reached a maximum of  $50.3 \times 10^9/\text{L}$ . The patient died of systemic metastasis 9 months after the operation. Furthermore, it was found that the patient's serum G-CSF level was 4928 ng/L. Furthermore, hepatic metastatic tumors also generate G-CSF, which is identified by the IHC analysis, indicating that G-CSF secretion in bladder tumor resulted in paraneoplastic LKR.

However, whether G-CSF can accelerate proliferation of bladder cancer cells is still controversial. In 1994, Sato *et al.*<sup>[5]</sup> found that the serum G-CSF level increased, which further induced leukocytosis in a patient with invasive bladder carcinoma, with no gene rearrangement and amplification of G-CSF. They also did not find the G-CSF

receptor in cancer cells. Hence, indirect promotion of proliferation of the bladder carcinoma by G-CSF could not be proved. However, as reported by Tachibana *et al.*,<sup>[6]</sup> high-levels of expression of G-CSF messenger ribonucleic acid (mRNA) and G-CSF receptor mRNA were found in cancer cells of patients with LKR bladder carcinoma. Proliferation in bladder carcinoma was induced *in vitro* by exogenous G-CSF and could be inhibited by anti G-CSF antibodies, which demonstrated that generation of G-CSF closely correlated with the proliferation of bladder carcinoma. Ohmi *et al.*<sup>[7]</sup> found that, in the presence of peripheral blood mononuclear cells, recombinant human G-CSF (rhG-CSF) strongly promotes proliferation of KK47 cells (derived from a transitional cell bladder carcinoma) in a dose-independent manner.

Levels of basic fibroblast growth factor (basic FGF) appear to be important to the effective dose of G-CSF. It was considered that rhG-CSF might promote proliferation of KK47 cells by accelerating production of basic FGF. In 2004, Chakraborty *et al.*<sup>[8]</sup> found that in bladder carcinoma samples with G-CSF and granulocyte colony-stimulating factor receptor (G-CSFR) expression, expression of integrin- $\beta 1$  protein was increased. Furthermore, expression of G-CSF, G-CSFR and integrin- $\beta 1$  was similarly increased in normal bladder mucosa that was distant from bladder carcinoma. In the 5637 human bladder carcinoma cell line, G-CSFR promotes integrin- $\beta 1$  adherence to fibronectin and laminin. Further studies proved that expression of G-CSF/G-CSFR in bladder carcinoma promotes adherence and invasion of cancer cells by a mechanism involving integrin- $\beta 1$ .<sup>[9]</sup> Transfecting TCC-SUP and 5637 cell lines with plasmids encoding G-CSFR, G-CSF/G-CSFR promoted proliferation of TCC-SUP-GR and anti G-CSF antibody accelerated apoptosis of 5637 glucocorticoid receptor (GR) cells. 5637 GR cells implanted in nude mice induced formation of a huge subcutaneous tumor, demonstrating that the autocrine (paracrine) pathway of G-CSF/G-CSFR promotes survival and growth of bladder cancer cells.<sup>[10]</sup> An increasing number of case reports have shown rapid tumor recurrence and systemic metastasis, with extremely poor prognoses. LKR and G-CSF have been widely accepted as markers useful in estimating prognosis for patients with bladder transitional cell carcinoma.<sup>[11,12]</sup>

Bladder carcinoma has a high rate of recurrence and progression. Although many relevant molecular markers have been identified, molecular markers of bladder cancer with both specificity and sensitivity have not been determined. Research in recent years has concentrated on such candidates as p53, Rb, cyclin D, p27Kip1, fibroblast growth factor receptor-3, cadherin, survivin, aurora, matrix metalloproteinase enzymes (MMP) vascular endothelial growth factor and DNA methylation, among others. Molecular markers will become an effective tool in the diagnosis and prognosis of bladder carcinoma, although

for bladder carcinoma in different stages or degrees, one particular marker may be more or less useful. Detection of G-CSF also will contribute to estimating the prognosis of bladder carcinoma.

Hu *et al.*<sup>[13]</sup> recently used streptavidin-granulocyte-macrophage colony-stimulating factor (SA-GM-CSF) to irrigate the bladder of a mouse *in vivo* tumor model and discovered that the morbidity of mice with bladder carcinoma treated with SA-GM-CSF decreased from 100% to 37.5%. Further, 70% of mice treated with SA-GM-CSF were immune to wild MB49 cancer cells administered in a secondary irrigation of the bladder, indicating that SA-GM-CSF had a potent anti-tumor effect. Zhang *et al.*<sup>[14]</sup> administered SA-GM-CSF to mouse metastatic bladder cancer models and lung metastatic bladder cancer models. Higher numbers of CD4 and CD8 cells were found in the area of tumors and in the peripheral blood of treated animals and proliferation of cancer cells were prominently inhibited. The mice were immune to secondary injections of MB49 cancer cells. Shi *et al.*<sup>[15]</sup> demonstrated that sequential use of MB49 tumor vaccine modified with GM-CSF and IL-2 effectively induced a specific anti-tumor immune response.

LKR, a rare paraneoplastic reaction in patients with bladder carcinoma, indicates a high degree of malignancy, high probability of metastasis and recurrence and wretched prognosis. Analyses of bone marrow and DNA can exclude leukemia and testing of WBC count and levels of G-CSF contributes to diagnosis and estimation of prognosis. Appearance of LKR correlates with expression of G-CSF/G-CSFR and promotes survival and growth of bladder cancer cells. In future studies, drugs blocking G-CSF/G-CSFR signaling can be used to further improve prognosis and promote curative effects.

### Acknowledgment

We thank Medjaden Bioscience Limited for assisting in the preparation of this manuscript.

### References

1. Block NL, Whitmore WF Jr. Leukemoid reaction, thrombocytosis and hypercalcemia associated with bladder cancer. *J Urol* 1973;110:660-3.
2. Ishida K, Yuhara K, Kanamoto Y. A case of bladder tumor producing granulocyte colony-stimulating factor. *Hinyokika Kyo* 2004;50:253-6.
3. Ito N, Matsuda T, Takeuchi Y, Takeuchi E, Takahashi T, Yoshida O. Bladder cancer producing granulocyte colony-stimulating factor. *N Engl J Med* 1990;323:1709-10.
4. Satoh H, Abe Y, Katoh Y, Komine Y, Nakamura M, Tamaoki N. Bladder carcinoma producing granulocyte colony-stimulating factor: A case report. *J Urol* 1993;149:843-5.
5. Sato K, Terada K, Sugiyama T, Sugiyama T, Masuda H, Kakinuma H, *et al.* Granulocyte colony-stimulating factor produced by bladder carcinoma of a patient with leukemoid reaction did not affect proliferation of the tumor cells. *J Urol* 1994;151:1687-90.
6. Tachibana M, Miyakawa A, Tazaki H, Nakamura K, Kubo A, Hata J, *et al.* Autocrine growth of transitional cell carcinoma of the bladder induced by granulocyte-colony stimulating factor. *Cancer Res* 1995;55:3438-43.
7. Ohmi C, Matsuyama H, Tei Y, Yoshihiro S, Shimabukuro T, Ohmoto Y, *et al.* Granulocyte colony-stimulating factor may promote proliferation of human bladder cancer cells mediated by basic fibroblast growth factor. *Scand J Urol Nephrol* 2003;37:286-91.
8. Chakraborty A, White SM, Lerner SP. Granulocyte colony-stimulating factor receptor signals for beta1-integrin expression and adhesion in bladder cancer. *Urology* 2004;63:177-83.
9. Chakraborty A, White SM, Guha S. Granulocyte colony-stimulating receptor promotes beta1-integrin-mediated adhesion and invasion of bladder cancer cells. *Urology* 2006;68:208-13.
10. Chakraborty A, Guha S. Granulocyte colony-stimulating factor/granulocyte colony-stimulating factor receptor biological axis promotes survival and growth of bladder cancer cells. *Urology* 2007;69:1210-5.
11. Perez FA, Fligner CL, Yu EY. Rapid clinical deterioration and leukemoid reaction after treatment of urothelial carcinoma of the bladder: Possible effect of granulocyte colony-stimulating factor. *J Clin Oncol* 2009;27:e215-7.
12. Dukes JW, Tierney LM Jr. Paraneoplastic leukemoid reaction as marker for transitional cell carcinoma recurrence. *Urology* 2009;73:928.e17-9.
13. Hu Z, Tan W, Zhang L, Liang Z, Xu C, Su H, *et al.* A novel immunotherapy for superficial bladder cancer by intravesical immobilization of GM-CSF. *J Cell Mol Med* 2010;14:1836-44.
14. Zhang X, Shi X, Li J, Hu Z, Zhou D, Gao J, *et al.* A novel therapeutic vaccine of mouse GM-CSF surface modified MB49 cells against metastatic bladder cancer. *J Urol* 2012;187:1071-9.
15. Shi X, Zhang X, Li J, Guo F, Hu Z, Jing Y, *et al.* Sequential administration of GM-CSF and IL-2 surface-modified MB49 cells vaccines against the metastatic bladder cancer. *Urol Oncol* 2013;31:883-93.

How to cite this article: ???

Source of Support: Nil, Conflict of Interest: None declared.