

Effect of mineral trioxide aggregate and formocresol pulpotomy on vital primary teeth: A clinical and radiographic study

OO Olatosi, EO Sote, OO Orenuga

Department of Child Dental Health, Faculty of Dental Sciences, College of Medicine, University of Lagos, Lagos, Nigeria

Abstract

Background: Pulpotomy is the common therapy for cariously exposed pulps in symptom-free primary molar teeth. Formocresol (FC) is considered the gold standard dressing agent for pulpotomy, but concerns have been raised over the years about its safety. Other alternative pulpotomy agents have been investigated and suggested.

Objective: The objective was to evaluate and compare the clinical and radiographic response of FC and white mineral trioxide aggregate (MTA) as pulpotomy materials on primary molars.

Materials and Methods: Fifty primary molars, with deep carious lesion that exposed a vital but asymptomatic pulp, in 37 children aged 4-7 years were treated with conventional pulpotomy procedure. The teeth were divided randomly into two groups. Group I (FC) and group II (MTA). The treated teeth were evaluated clinically and radiographically and were followed-up for 12 months.

Results: At the end of the 12 months follow-up, the clinical success rates for FC and MTA were 81% and 100%, respectively. There was a statistically significant difference ($P = 0.04$) between the clinical success rates of FC and MTA. While the radiographic success rates for FC and MTA were 81% and 96%, respectively, there was no statistically significant difference between the radiographic success of MTA and FC.

Conclusion: White MTA showed a higher clinical and radiographic success rate when compared to FC as a pulpotomy agent in vital primary molars, and it has a potential to become a replacement for FC in primary molars.

Key words: Formocresol, mineral trioxide aggregate, primary molars, pulpotomy

Date of Acceptance: 16-Sep-2014

Introduction

Dental caries and traumatic injuries can cause the dental pulp to undergo irreversible damage which can lead to premature loss of a tooth. One of the major goals in pediatric dentistry is to maintain the primary dentition in an intact state until the permanent successors erupt.^[1,2]

Pulpotomy is a common treatment done to retain cariously involved primary molars that would otherwise be extracted. In pulpotomy, the coronal part of the pulp is removed, and the remaining pulp tissue is covered with a medicament to maintain the vitality of the radicular pulp.^[3] The pulpotomy

procedure is based on the rationale that the radicular pulp tissue is healthy or is capable of healing after surgical amputation of the affected or infected coronal pulp.^[4]

Although many materials such as FC, ferric sulfate, glutaraldehyde, calcium hydroxide, zinc oxide eugenol (ZOE) have been used over the years for pulpotomy procedure, the ideal material should meet certain requirements such as being bactericidal, harmless to the pulpal tissue and surrounding structures, promoting healing of the radicular pulp, not interfering with normal physiological root

Address for correspondence:

Dr. Olatosi Olubukola Olamide,
Department of Child Dental Health, Faculty of Dental Sciences,
College of Medicine, University of Lagos, Lagos, Nigeria.
E-mail: bukkyolatosi@yahoo.com

Access this article online

Quick Response Code:



Website: www.njcponline.com

DOI: 10.4103/1119-3077.151071

resorption, and preserving the radicular pulp without any clinical or radiographic symptoms.^[1] Formocresol (FC) has been a popular pulp medicament most frequently used in clinical practice for pulpotomy in primary teeth. Doubts have arisen as to the safety of FC in spite of its efficacy.^[5-8] These findings have led to the search for a suitable alternative to replace FC. This replacement medicament must be equally effective but without the undesirable side-effects of FC.

Mineral trioxide aggregate (MTA) was developed by Torabinejad at Loma Linda University in 1995. Mineral trioxide aggregate was introduced as a potential alternative dressing material for pulpotomy of primary molars with features of stimulating cytokine release from bone cells, inducing hard tissue formation, a dentinogenic effect on the pulp, antimicrobial properties, and ability to maintain pulp integrity after pulp capping and pulpotomy without cytotoxic effect.^[9]

The aim of this study, therefore, was to evaluate and compare the clinical and radiographic response of FC and MTA as pulpotomy materials on primary molars.

Materials and Methods

Study design and sampling

The study was carried out on primary molars of children aged 4-7 years selected from patients referred to the Pediatric Dentistry unit of the Department of Child Dental Health Lagos University Teaching Hospital with good general health and no history of systemic illness or hospitalization.

The study was carried out on 50 primary molars requiring pulpotomy treatment. Each tooth was randomly assigned to one of the two treatment groups, the FC and MTA group.

The teeth requiring pulpotomy were selected according to the following clinical criteria:

- Deep carious lesion that exposes vital pulp but symptomless
- Absence of clinical symptoms or evidence of the pulp degeneration, such as swelling (pulpal origin), sinus tract, tenderness to percussion, pathologic tooth mobility, excessive bleeding from amputated radicular pulp stumps
- Possibility of proper restoration with Stainless steel crown
- No radiographic evidence of the pulp degeneration such as, internal and external resorption, inter-radicular, and/or periapical bone destruction or pulp stones.

Ethics

An approval for the research was obtained from the Health Research and Ethics Committee of the Lagos University

Teaching Hospital. Informed consent was obtained from parents/guardians. Participation in the study was voluntary.

Pulpotomy procedure

All pulpotomy procedures were performed by a pediatric dentist. Local anesthesia was administered, and the teeth were isolated with a rubber dam. After removal of the carious lesion, the pulp chamber was accessed with bur N°330, high-speed handpiece and water spray. Following removal of the coronal pulp with a slow round bur, hemostasis was obtained with moistened cotton pellets. The medicaments used were FC (Cresol Formalina GHIMAS S.P.A Italy) and MTA (White Proroot MTA, DENTSPLY Tulsa Dental, USA). In the FC group, cotton pellet dipped in 1:5 diluted FC (Buckley's solution) of which excess was squeezed out and placed on the pulp stump for 5 min.

In the MTA group, white MTA was prepared according to the manufacturer's instruction by mixing MTA powder with distilled water at a 3:1 powder/water ratio and placed over the pulp stump. In both groups, ZOE cement was placed to fill the pulp chamber. The teeth were restored with stainless steel crown (SSC 3M ESPE) at the same visit. Clinical and radiographic evaluations of each tooth were performed at 1, 3, 6, 9, and 12 months after the pulpotomy.

At each follow-up appointment, the pulpotomy was considered clinically successful if the treated primary molars showed the following: No symptoms of pain, no tenderness to percussion, no swelling or sinus tract, no pathologic tooth mobility. The pulpotomy was considered radiographically successful at follow-up appointment if the radiograph showed the following: A normal periodontal ligament space, no furcation or periapical radiolucency, no active/progressing internal root resorption, no pathologic external root resorption. Deviation from any one of these clinical and/or radiographic signs was regarded as a failure of treatment.

At each follow-up visit, clinical assessment of the treated teeth which were only identified by code was carried out by two experienced dentists who were blinded to the treatment groups. Series of preoperative and postoperative radiographs for each treated tooth were independently evaluated by the dentists and were both calibrated by evaluating a series of randomly selected pre- and post-operative radiographs from ten children. The intra and inter-examiner reproducibility were calculated by Cohen's unweighted Kappa statistic and were 0.94 and 0.97, respectively.

Statistical analysis

Statistical analysis was carried out using Epi info 7 Centers for Disease Control and Prevention (CDC) Atlanta, Georgia (USA). Description of the patients and teeth included in this study was tabulated. In addition, clinical and radiographic evaluation results were tabulated according

to the recall. The differences between the two during the observation period were statistically analyzed using the *t*-test, Fisher exact test and Chi-square. The level of significance was set at $P < 0.05$.

Results

A total of 50 vital primary molars in 37 child patients was used in the study, with an equal number of teeth in both the FC and MTA groups. The age range for the patients was 4-7 years in both groups. A total number of four teeth in two patients was lost to follow-up at the end of the 12 months evaluation period [Table 1].

Clinical and radiographic success rates of MTA and FC were 100% at 1, 3, and 6 months with no signs of failure.

The number of teeth evaluated at 9 months follow-up was 49. All the 25 teeth in the MTA group were available for follow-up and did not show any sign/symptom of failure. Of the 24 teeth available in the FC group, 1 (4.2%) tooth had failed due to pathological tooth mobility. The remaining 23 (95.8%) treated teeth showed no signs/symptoms of pain, tenderness to percussion, swelling and/or sinus tract and pathologic tooth mobility. Clinical success rate at 9 months was 100% and 95.8% for MTA and FC, respectively, with no statistically significant difference between the two agents ($P = 0.49$) [Table 2a].

The radiographic success rate at 9 months for the FC group was 83.3% and 100% for MTA. This difference was statistically significant ($P = 0.05$) [Table 2b]. Of the 24 teeth available in the FC group, 20 (83.3%) teeth showed no signs of failure, while 4 (16.8%) showed signs of radiographic failure. Findings in the teeth with radiographic failure in the FC group were 1 (4.2%) internal root resorption, 1 (4.2%) external root resorption, 1 (4.2%) furcation radiolucency and 1 (4.2%) periodontal ligament space widening. The tooth with periodontal ligament space widening also showed signs of furcation radiolucency.

At 12 months follow-up period, 46 teeth were available for evaluation of which 25 were for the MTA group and 21 for the FC group. In the FC group 17 (81%) teeth had no signs and symptoms. A total of four had failed, three due to buccal sinus and one due to pathological tooth mobility. There was no sign of clinical failure in the MTA group. The clinical success rate at 12 months was 100% and 81% for MTA and FC, respectively. This finding was statistically significant ($P = 0.04$) [Table 3a].

The radiographic evaluation at 12 months in the MTA group 24 (96%) teeth showed no signs of failure, but failure was observed in 1 (4%) tooth with furcation involvement. In the FC group 17 (81%) teeth showed no signs of radiographic failure. A total of 4 (19%) teeth

showed signs of radiographic failure. Of these four teeth, 2 (9.5%) had furcation involvement, 1 (4.8%) had external root resorption, and 1 (4.8%) had external root resorption and internal root resorption [Figure 1] in the same tooth. The radiographic success rates for MTA and FC were 96% and 81%, respectively. There was no statistically significant difference ($P = 0.20$) between the two agents [Table 3b].

Table 1: Number of pulpotted teeth and follow-up times according to agents

Months	Number of teeth		Total
	FC	MTA	
3	25	25	50
6	25	25	50
9	24	25	49
12	21	25	46

FC=Formocresol; MTA=Mineral trioxide aggregate

Table 2a: Clinical evaluation and success rate of FC and MTA pulpotted at 9 months follow-up

Clinical findings	Frequency (%)	
	FC (n=24)	MTA (n=25)
No sign/symptom	23 (95.8)	25 (100)
Symptoms of pain	0 (0)	0 (0)
Tenderness to percussion	0 (0)	0 (0)
Swelling and/or fistula	0 (0)	0 (0)
Pathological tooth mobility	1 (4.2)	0 (0)
Total	24 (100)	25 (100)

$P=0.49$; FC=Formocresol; MTA=Mineral trioxide aggregate

Table 2b: Radiographic evaluation and success rate of FC and MTA pulpotted at 9 months follow-up

Radiographic findings	Frequency (%)	
	FC (n=24)	MTA (n=25)
No change	20 (83.3)	25 (100)
External root resorption	1 (4.2)	-
PLS widening + furcation radiolucency	1 (4.2)	-
Internal root resorption	1 (4.2)	-
Furcation and/or periapical radiolucency	1 (4.2)	-
Total	24 (100)	100

* $P=0.05$; *Significant at $P<0.05$; FC=Formocresol; MTA=Mineral trioxide aggregate; PLS=Periodontal ligament space

Table 3a: Clinical evaluation and success rate of FC and MTA pulpotted at 12 months follow-up

Clinical findings	Frequency (%)	
	FC (n=21)	MTA (n=25)
No change	17 (81)	25 (100)
Symptoms of pain	-	-
Tenderness to percussion	-	-
Swelling and/or fistula	3 (14.3)	-
Pathological tooth mobility	1 (4.7)	-
Total	21 (100)	25 (100)

* $P=0.04$; *Significant at $P<0.05$; FC=Formocresol; MTA=Mineral trioxide aggregate

Table 3b: Radiographic evaluation and success rate of FC and MTA pulpotomies at 12 months follow-up

Radiographic findings	Frequency (%)	
	FC (n=21)	MTA (n=25)
No change	17 (81.0)	24 (96.0)
External root resorption	1 (4.8)	-
PLS widening	-	-
Internal root resorption + external	1 (4.8)	-
Furcation and/or periapical radiolucency	2 (9.5)	1 (4.0)
Total	21 (100)	25 (100)

P=0.20; FC=Formocresol; MTA=Mineral trioxide aggregate; PLS=Periodontal ligament space

Table 4: Clinical and radiographic assessment of MTA and FC treated primary molars at different evaluation times

Month	FC			MTA		
	n	Frequency	Rate (%)	n	Frequency	Rate (%)
Clinical						
3	25	25	100	25	25	100
6	25	25	100	25	25	100
9	24	23	95.8	25	25	100
12	21	17	81.0	25	25	100
Radiographic						
3	25	25	100	25	25	100
6	25	25	100	25	25	100
9	24	20	83.3	25	25	100
12	21	17	81.0	25	24	96.0

FC=Formocresol; MTA=Mineral trioxide aggregate

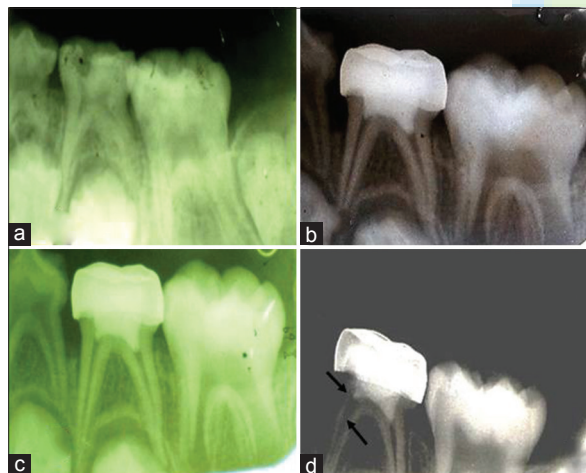


Figure 1: (a). preoperative radiograph of FC treated tooth (b) 6 months follow-up (no signs of failure) (c) 9 months follow-up (d) At 12 months follow-up (internal root resorption)

At the end of the 12 months follow-up, the clinical success rates for FC and MTA were 81% and 100% respectively. There was a statistically significant difference ($P = 0.04$) between the clinical success rates of FC and MTA. While the radiographic success rates for FC and MTA were 81% and 96%, respectively, there was no statistically significant difference between the radiographic success of MTA and FC [Table 4].

Discussion

The present study was conducted to evaluate the clinical and radiographic success rates of pulpotomies performed using MTA a relatively new agent in endodontics, which has been demonstrated to be biocompatible, nontoxic, promote regeneration of pulp tissues and which fulfills the purpose of pulpotomy treatment; to maintain the treated teeth in a functional state.^[10-12]

Formocresol was used as a control group since it is still the gold standard in primary teeth pulp therapy, in spite of its reported toxic, mutagenic, and carcinogenic properties.^[5-8] It is possible that FC would be abandoned if an effective nontoxic alternative is identified.

The ages of the children ranged between 4 and 7 years due to lack of cooperation that may be seen in children <4 years and the possibility of physiologic root resorption (>3/4 of root) in children above the age of 7 years.^[2,13]

The success of any clinical procedure is usually determined during the follow-up visits. Availability of patients at scheduled follow-up appointments is, therefore, an important factor which must be considered in determining the efficacy of the treatment.^[11]

In this study, 37 children had pulpotomy done on 50 primary molars. A total of 46 teeth in 35 children was available for evaluation after 12 months. This high number of patients available for follow-up was probably due to a good rapport with the children, their parents and repeated reminders. The two children lost to follow-up were as a result of relocation to another city and loss of interest.

Our findings showed a higher success rate in teeth treated with MTA (100% clinical, 96% radiographic) than those with FC (81% clinical, 81% radiographic) throughout the follow-up period both clinically and radiographically. There was a statistically significant difference between the clinical success rates of MTA and FC ($P = 0.04$) at the end of the 12 months follow-up period. These findings are similar to those reported by other authors.^[11,14,15] The lower success rate for FC compared with MTA observed in this study is consistent with previous studies that showed decreased success rate of FC with time.^[16-18]

The common radiographic failure in the present study in the FC group were internal/external root resorptions, inter radicular/periapical radiolucency, while the clinical failures in the FC group, where the presence of sinus and pathologic tooth mobility. The probable reason for this may be due to the fixative effect of FC and its ability to vaporize and escape through the apical foramen. In the MTA group, there was no clinical failure, the radiographic finding of inter radicular

radiolucency seen in one tooth may be attributed to misdiagnosis of inflammation in the radicular pulp prior to treatment.

Internal root resorption was observed in this study in one tooth (4.2%) in the FC group both at 9 months and 12 months follow-up evaluation and none in the MTA group. This agrees with the findings by Eidelman *et al.* who reported one case (7%) of internal root resorption in the FC group and none in the MTA group.^[15] Holan *et al.* also found 4 teeth (13.8%) in the FC group with internal root resorption which was associated with periapical and/or inter-radicular radiolucent defects and external root resorption.^[11] There are reports that internal resorption is associated with eugenol.^[19] When used together with zinc oxide (as a sub-base following pulpotomy), eugenol comes into direct contact with vital tissue following hydrolysis of zinc eugenol to yield the free eugenol. This causes a moderate to severe inflammatory response, resulting in chronic inflammation and necrosis. It has been reported that internal resorption is more likely the result of undiagnosed chronic inflammation existing in the radicular pulp prior to pulpotomy than the result of exposure of the radicular pulp to eugenol.^[11] Smith *et al.* also claimed that the fixed layer caused by FC on the pulp serves as a barrier to eugenol.^[19]

The internal root resorption seen in this study is not likely to come from eugenol as ZOE paste was placed as a base on FC fixed tissue which serves as a barrier to eugenol, rather the internal root resorption may be from the reversible fixative effect of FC and its irritative pH.

In the present study, there was a statistically significant difference in the success rate using clinical criteria, with MTA showing better outcomes at the end of the 12 months evaluation period when compared with FC.

The greater success rate of MTA can be attributed to its biocompatibility and sealing ability when compared to FC.

Despite the promising findings regarding the use of MTA in this study, it is important to note that the follow-up period was short. There is, therefore, a need to conduct further studies with a larger sample size and longer follow-up period. It is also important to study and determine the possible effects of MTA on succedaneous permanent teeth. Further, histological studies are also needed to determine the pulpal response to this material.^[20] However, the results here indicate that MTA has a promising potential to be a replacement for FC after pulpotomy in primary molars.

Conclusion

Mineral trioxide aggregate showed clinical and radiographic success as a dressing material following pulpotomy procedure in primary teeth, and it has a promising potential to become

a replacement for FC in primary molars. Though FC has been a controversial medicament for decades, it is still being used for pulpotomy procedure. However, MTA may be a potential replacement for FC. One of the limitations of MTA is its high cost and technique sensitivity.

References

1. Fuks AB. Current concepts in vital primary pulp therapy. *Eur J Paediatr Dent* 2002;3:115-20.
2. Godhi B, Sood PB, Sharma A. Effects of mineral trioxide aggregate and formocresol on vital pulp after pulpotomy of primary molars: An *in vivo* study. *Contemp Clin Dent* 2011;2:296-301.
3. Camp JH, Fuks AB. Pediatric endodontics: Endodontic treatment for the primary and young permanent dentition. In: Cohen S, Hargreaves KM, editors. *Pathways of the Pulp*. 9th ed. St. Louis: Mosby Elsevier; 2006. p. 822-53.
4. Bergholtz G. Effect of bacterial products on inflammatory reactions in the dental pulp. *Scand J Dent Res* 1977;85:122-9.
5. Ranly DM, Horn D. Assessment of the systemic distribution and toxicity of formaldehyde following pulpotomy treatment: Part two. *ASDC J Dent Child* 1987;54:40-4.
6. Zarzar PA, Rosenblatt A, Takahashi CS, Takeuchi PL, Costa Júnior LA. Formocresol mutagenicity following primary tooth pulp therapy: An *in vivo* study. *J Dent* 2003;31:479-85.
7. Block RM, Lewis RD, Hirsch J, Coffey J, Langeland K. Systemic distribution of 14C-labeled Paraformaldehyde incorporated within Formocresol following pulpotomies in dogs. *J Endod* 1983;9:176-89.
8. Pashley EL, Myers DR, Pashley DH, Whitford GM. Systemic distribution of 14C-formaldehyde from formocresol-treated pulpotomy sites. *J Dent Res* 1980;59:602-8.
9. Torabinejad M, Hong CU, McDonald F, Pitt Ford TR. Physical and chemical properties of a new root-end filling material. *J Endod* 1995;21:349-53.
10. Ansari G, Ranjipour M. Mineral trioxide aggregate and formocresol pulpotomy of primary teeth: A 2-year follow-up. *Int Endod J* 2010;43:413-8.
11. Holan G, Eidelman E, Fuks AB. Long-term evaluation of pulpotomy in primary molars using mineral trioxide aggregate or formocresol. *Pediatr Dent* 2005;27:129-36.
12. Farsi N, Alamoudi N, Balto K, Mushayt A. Success of mineral trioxide aggregate in pulpotomized primary molars. *J Clin Pediatr Dent* 2005;29:307-11.
13. Agamy HA, Bakry NS, Mounir MM, Avery DR. Comparison of mineral trioxide aggregate and formocresol as pulp-capping agents in pulpotomized primary teeth. *Pediatr Dent* 2004;26:302-9.
14. Peng L, Ye L, Tan H, Zhou X. Evaluation of the formocresol versus mineral trioxide aggregate primary molar pulpotomy: A meta-analysis. *Oral Surg Oral Med Oral Pathol Oral Radiol Endod* 2006;102:e40-4.
15. Eidelman E, Holan G, Fuks AB. Mineral trioxide aggregate vs. formocresol in pulpotomized primary molars: A preliminary report. *Pediatr Dent* 2001;23:15-8.
16. Jayam C, Mitra M, Mishra J, Bhattacharya B, Jana B. Evaluation and comparison of white mineral trioxide aggregate and formocresol medicaments in primary tooth pulpotomy: Clinical and radiographic study. *J Indian Soc Pedod Prev Dent* 2014;32:13-8.
17. Airen P, Shigli A, Airen B. Comparative evaluation of formocresol and mineral trioxide aggregate in pulpotomized primary molars-2 year follow up. *J Clin Pediatr Dent* 2012;37:143-7.
18. Aeinehchi M, Dadvand S, Fayazi S, Bayat-Movahed S. Randomized controlled trial of mineral trioxide aggregate and formocresol for pulpotomy in primary molar teeth. *Int Endod J* 2007;40:261-7.
19. Smith NL, Seale NS, Nunn ME. Ferric sulfate pulpotomy in primary molars: A retrospective study. *Pediatr Dent* 2000;22:192-9.
20. Salako N, Joseph B, Ritwik P, Salonen J, John P, Junaid TA. Comparison of bioactive glass, mineral trioxide aggregate, ferric sulfate, and formocresol as pulpotomy agents in rat molar. *Dent Traumatol* 2003;19:314-20.

How to cite this article: Olatosi OO, Sote EO, Orenuga OO. Effect of mineral trioxide aggregate and formocresol pulpotomy on vital primary teeth: A clinical and radiographic study. *Niger J Clin Pract* 2015;18:292-6.
Source of Support: Nil, **Conflict of Interest:** None declared.