

# Surgical Decompression for Traumatic Spinal Cord Injury in a Tertiary Center

OA Ojo, EO Poluyi, BS Owolabi, OO Kanu, MO Popoola<sup>1</sup>

Department of Surgery, College of Medicine of University of Lagos, Lagos University Teaching Hospital, Lagos, Nigeria, <sup>1</sup>Department of Epidemiology, Human Genetics and Environmental Science University of Texas School of Public Health, Houston, Texas, USA

ABSTRACT

**Background:** There are controversies regarding the importance and timing of spinal cord decompression following trauma. Documented evidence shows that early decompression in the setting of acute spinal cord injury (SCI) improves neurologic outcomes. Our objective was to evaluate the outcome of posttraumatic spinal cord decompression with or without spinal stabilization in our region. **Methodology:** We performed a cross-sectional study on adult patients who presented with acute spinal cord compression of traumatic etiology within a 2-year period. The primary outcome was change in Frankel's grading 6 months after surgery. Secondary outcomes were complication rates and mortality. **Results:** A total of 35 patients made up of 24 (68.6%) males and 11 (31.4%) females were recruited into the study. The spectrum of injuries included cervical 27 (77.1%), thoracic 7 (20.0%), and lumbar vertebrae 1 (2.9%). The outcome as measured by Frankel's grade at 6 months after surgery showed improvement in 9 (25.7%) patients following intervention. All patients who presented with Frankel's Grade C and D improved to Grade E while none of those who presented with Frankel's Grade E deteriorated. The common complications of spine decompression and fixation in this series were surgical site infections (11.4%) and chest infections (11.4%), especially in high cervical injury. **Conclusion:** Spinal cord decompression with spinal stabilization enhances the rehabilitation of patients with unstable spine and completes spinal cord injuries. Our experience shows improvement in neurological function in patients with spinal cord decompression despite the challenges of instrumentation in Sub-Saharan Africa.

**KEYWORDS:** Anterior cervical discectomy and fusion, lateral mass fixation, spinal decompression, traumatic spinal cord injury

Date of Acceptance: 10-Jul-2017

## INTRODUCTION

Acute spinal cord compression (SCC) is usually associated with significant myelopathic sequelae regardless of the causative factors. The severity of neurologic deficit depends on the degree of compression as well as the duration of spinal cord injury (SCI). Cord compression with paraplegia or quadriplegia has enormous socioeconomic and emotional consequences.<sup>[1,2]</sup>

Regardless of the etiology of SCC, the general principle is early decompression, and prognosis is noted to be better when decompression is done as early as possible in acute spinal injury. Studies have documented significant improved outcome when spinal cord injured

patients have decompression and stabilization in unstable spinal injuries within the first 48 h of injury.<sup>[3-5]</sup> In cases of complete SCI from cord transection or acute compression with spinal instability, patients have been noted to have better rehabilitation process and care even though the neurology may not improve. Although there are controversies about the importance and timing of decompression, there is a consensus for the need to stabilize the spine in unstable patients to help with

**Address for correspondence:** Dr. OA Ojo, Department of Surgery, Neurosurgery Unit, Lagos University Teaching Hospital, Idi-Araba, Lagos State, Nigeria. E-mail: tayoojo111@yahoo.com

This is an open access article distributed under the terms of the Creative Commons Attribution-NonCommercial-ShareAlike 3.0 License, which allows others to remix, tweak, and build upon the work non-commercially, as long as the author is credited and the new creations are licensed under the identical terms.

For reprints contact: reprints@medknow.com

**How to cite this article:** Ojo OA, Poluyi EO, Owolabi BS, Kanu OO, Popoola MO. Surgical decompression for traumatic spinal cord injury in a tertiary center. Niger J Clin Pract 2017;20:1455-60.

Access this article online	
Quick Response Code:	Website: <a href="http://www.njcponline.com">www.njcponline.com</a>
	DOI: 10.4103/njcp.njcp_303_16

rehabilitation. Hence, decompression and stabilization enhance care.<sup>[6,7]</sup>

There are different methods of decompression which could be in form of laminectomy or corpectomy. Decompression could also be as a single entity or in combination with stabilization. The decision on what to do depends on presentation, etiology, and findings on computed tomography and magnetic resonance imaging (MRI) scan of patients with SCC.

This study aims to document the experience of spinal cord decompression with or without spinal stabilization in our region with emphasis on outcome based on changes in Frankel's grading 6 months after surgery as well as complication rates and mortality.

## METHODOLOGY

A prospective cross-sectional study was done on patients who presented with acute SCC of traumatic etiology. All patients who had spine injury and cord decompression surgery within a 2-year period were included in this study. Inclusion criteria were adult patients with cord compression who were operated on. The details of the patients were recorded at presentation, and subsequently, other details were retrieved from the case notes. Children and patients with multiple injuries as well as those with cardiovascular instability were excluded from the study.

A full demographic data were recorded at presentation. Etiology and clinical examination were documented, and details of the surgery were recorded. Neurology of patients, especially the motor functions, was recorded using the Frankel's grading both preoperatively and at 6 months after surgery on follow-up. All the patients were followed up for a minimum of 6 months. Complication of the surgery and mortality was noted. The outcome measure primarily was changes in Frankel's grading. Complication and mortality were secondary outcomes.

Data obtained was divided into preoperative, operative, and postoperative patient details. Mean and standard deviation were computed for continuous variables while the frequency was generated for categorical variables. Data were analyzed using SPSS Version 20.0 (IBM Corp, Armonk, NY) statistical software. The analyzed data are presented as frequency tables.

Ethical approval was obtained from the appropriate authority. Confidentiality of the patient's information in the medical records was ensured as names were not required for this study.

## RESULTS

A total of 35 patients met the inclusion criteria and were recruited into the study. General patient characteristics

are summarized in [Table 1]. There were 24 (68.6%) males and 11 (31.4%) females with a male female ratio of 2.2:1. The mean age was 38.6 ( $\pm$ 13.3) years. Median age was 35 years, and the modal age was 28 years.

Cervical, thoracic, and lumbar spines were the areas involved. The most frequently injured cord region was the cervical spine (77.1%).

Various surgical procedures were carried out to decompress the cord at different levels. These included simple laminectomy (11.4%), laminectomy with lateral mass fixation (17.1%) in cervical region, laminectomy with pedicle screws and rods in thoracic and thoracolumbar region (22.9%), anterior cervical discectomy and fusion (ACDF) (22.9%) and combination of ACDF with lateral mass fixation (360° fixation) (25.7%) [Figure 1].

A summary of the changes in Frankel grade is presented in [Table 2]. The outcome as measured by Frankel's grade at 6 months after surgery showed 9 (25.7%) patients had improved Frankel's grade following surgical intervention. Of the patients who presented with Frankel's Grade A, there was no improvement in 14 (82.4%) patients while 3 (17.7%) patients died. Of those who presented with Frankel's Grade B, 12.5% improved to Grade C, 12.5% to Grade D, and 37.5% to Grade E. One patient (12.5%)

**Table 1: Preoperative patient characteristics (n=62)**

	Frequency (%)
Gender	
Male	24 (68.6)
Female	11 (31.4)
Mean age	38.6 ( $\pm$ 13.3)
Etiology	
Spine trauma	35 (100.0)
Traumatic cervical spine injury	27 (77.1)
Traumatic thoracic injury	8 (22.9)
Surgery level	
Cervical	27 (77.1)
Thoracic	7 (20.0)
Lumbar	1 (2.9)
Surgery type	
360°	9 (25.7)
ACDF	8 (22.9)
Laminectomy	4 (11.4)
Lateral mass fixation	6 (17.1)
Thoracic fixation	8 (22.9)
Frankel at presentation	
A	17 (48.6)
B	8 (22.9)
C	2 (11.4)
D	2 (17.1)
E	6 (22.9)

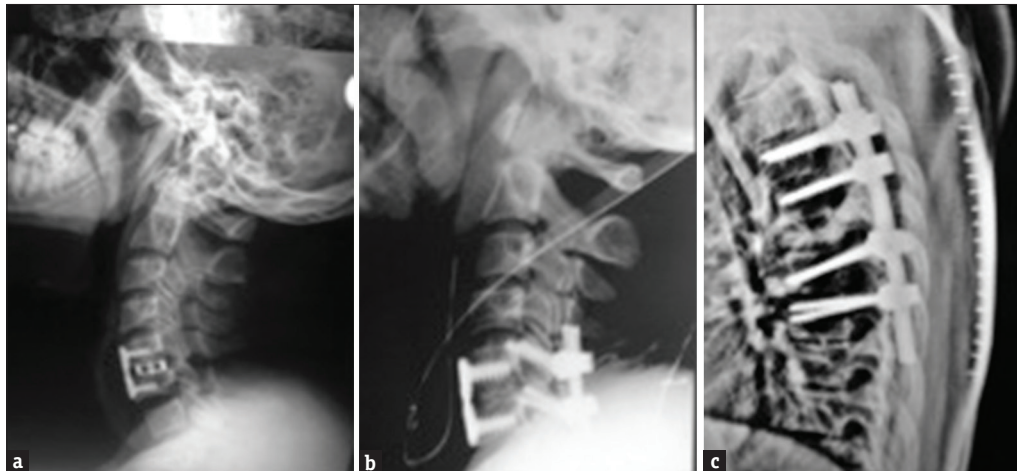
ACDF=Anterior cervical discectomy and fusion

remained unchanged in Frankel grading while 2 (25.0%) patients died. Mortalities were only seen in the cervical spine group, and they were five in all (14.3%). There were no mortalities in the thoracic and lumbar group.

All patients who presented with Frankel's Grade C and D improved to Grade E while none of those who presented

with Frankel's Grade E deteriorated. Fifteen (51.7%) of the patients with Frankel's at presentation below Grade E had no changes in Frankel grading preoperative and 6 months after surgery, while 5 (17.2%) of them died [Table 3].

The common complications of spine surgery in this series include surgical site infections (11.4%) and chest



**Figure 1:** Postoperative images of (a) C5/C6 anterior decompression and fixation. (b) Anterior and posterior decompression and fixation (3600 fixation). (c) Thoracic decompression and fixation with screws and rods

**Table 2: Postoperative characteristics showing Frankel outcome and etiology**

Diagnosis	Frankel outcome scoring						Total percentage improvement
	Died (%)	Nil (%)	Improved by 1 grade point (%)	Improved by 2 grade points (%)	Improved by 3 grade points (%)	Frankel at presentation (%)	
Cervical spine injury	5 (18.5)	12 (80.0)	2 (66.7)	3 (100.0)	2 (66.7)	3 (50.0)	29.2
Thoracic injury	0	3 (20.0)	1 (33.3)	0	1 (33.3)	3 (50.0)	40.0
Total	5 (14.3)	15 (42.9)	3 (8.6)	3 (8.6)	3 (8.6)	6 (17.1)	31.0

**Table 3: Postoperative characteristics showing surgery done and complications**

Complications	Combined fixation (360) (%)	ACDF (%)	Laminectomy (%)	Lateral mass fixation (%)	Thoracic fixation (%)	Total (%)
Systemic complication						
Pneumonia	1 (2.9)	0	2 (5.7)	0	0	3 (8.6)
Cardiac arrest	1 (2.9)	0	0	1 (2.9)	0	2 (5.7)
Local complication						
CSF leak	1 (2.9)	0	0	0	0	1 (2.9)
SSI	1 (2.9)	0	0	1 (2.9)	2 (5.7)	4 (11.4)
Death	1 (2.9)	0	0	1 (2.9)	0	2 (2.9)

ACDF=Anterior cervical discectomy and fusion; CSF=Cerebrospinal fluid; SSI=Surgical site infection

**Table 4: Frankel's grade at presentation versus Frankel's grade at discharge**

Frankel's grade at presentation	Frankel's grade at discharge (%)					Died	Total
	A	B	C	D	E		
A	14 (82.4)	0	0	0	0	3 (21.4)	17 (100.0)
B	0	1 (12.5)	1 (12.5)	1 (12.5)	3 (37.5)	2 (25.0)	8 (100.0)
C	0	0	0	0	2 (100.0)	0	2 (100.0)
D	0	0	0	0	2 (100.0)	0	2 (100.0)
E	0	0	0	0	6 (100.0)	0	6 (100.0)
Total	14 (10.0)	1 (2.9)	1 (2.9)	1 (2.9)	13 (37.1)	5 (14.3)	35 (100.0)

infections (11.4%) while other complications include septicemia (8.6%) and cerebrospinal fluid leak (2.9%). There was no deterioration of the motor functions after the surgery in any of the patients. Laminectomy and combination of ACDF with lateral mass fixation had the lowest postoperative complication [Table 4]. Five patients died soon after the surgery in the study given a mortality rate of 14.3%.

## DISCUSSION

Acute SCC in the cervical and thoracic spine region usually result from high-impact injuries such as road traffic accident or fall from height.<sup>[8,9]</sup> Common causes of cord compression include trauma, degenerative diseases, infective diseases, and spinal tumor, especially metastatic lesions.<sup>[10]</sup> The most common of the causes is trauma as documented by Hua *et al.*<sup>[9]</sup> Spinal cord is an extension of hindbrain into the spinal canal and spans from C1 to L1/L2 where it terminates as the conus medullaris, compression is therefore possible in its course through the cervical and thoracic spine including the termination at L1/L2.

Operative techniques utilized in decompression were dependent on the spinal level of injury or compression, the severity, and the available surgical expertise. In the cervical region, the options were ACDF, posterior decompression with or without lateral mass screw stabilization as well as a combination of anterior and posterior decompression and instrumentation. The combination of ACDF and posterior fixation is also called 360° fixation and may be useful for the treatment of other cervical spine pathologies.<sup>[11]</sup> Thoracic and lumbar surgeries were limited to posterior approach as the instrumentation for anterior decompression and stabilization of both thoracic and lumbar regions were not available in the center [Figure 1a-c]. Other possible approaches that have been documented include transforaminal decompression and interbody fusion using minimally invasive techniques.<sup>[12]</sup>

The degree and duration of compression of the cord before surgical intervention determines the outcome of decompression. Therefore, the aim of the surgeon is to relieve cord compression as early as possible and stabilize the spine to protect the cord. In trauma setting, there is evidence to suggest that outcome is better when spinal decompression is done within 48 h.<sup>[5,13]</sup> Patients presenting to our center were operated within 48 h of presentation (not necessarily 48 h of injury) except patients that were not stable clinically for such surgery. Patients with mechanism of injury indication high impact injury without neurological deficit other than pain had MRI done to rule out spine injury. Such

patients with cord compression or ligamentous injury but without significant neurologic deficit were offered early decompression with or without stabilization as necessary.

In different studies of cervical spine injury, the importance of early decompression and stabilization is demonstrated by the improved clinical outcome and no deterioration of neurology.<sup>[3]</sup> There were 9 (31.0%) cases of improved neurology in this series, and no patient had deterioration in Frankel grading postsurgery. The improvement was from one point to three points [Table 3]. In contrast, Liu *et al.* postulated that late surgery has better outcome because of increased mortality rate seen in early surgery in their series.<sup>[14]</sup> Literature search revealed that few people agree with this opinion. It is impossible to conclude the outcome from our study because most patients presented well beyond 48 h after the incidents, and the outcome of decompression is best when it is done within the first 48 h of injury. The reason for this is due to few neurosurgical centers that have facilities for spine surgery in our subregion. There are reports that showed improved clinical outcome even when decompression is done >72 h after injury.<sup>[4,15]</sup> Therefore, surgery is indicated in acute spine injury at presentation.<sup>[16,17]</sup>

In unstable spinal injuries, decompression is as important as stabilization to ensure the cord is no longer at risk of further injury. Nnadi and Bankole in a study had documented good neurologic improvement from conservative management of acute spine injury.<sup>[18]</sup> This is in contrast to other studies elsewhere. Of course, where the expertise and facilities are not available for surgical intervention, the carers are left with the conservative option but this should not be the standard of care as evidenced in our study which showed some improvement in outcome after surgical decompression in acute settings. There were, however, more patients with improved outcome in cervical injuries than thoracic [Table 3].

That surgery is needed in unstable spine injury is not in doubt.<sup>[19,20]</sup> The patient may not have any improvement in neurology afterwards, but rehabilitation is easier with a stable spine construct.<sup>[21]</sup> This was the case in this study. The option of bed rest in conservative management for about 6 weeks predisposes patients to complications such as deep vein thrombosis, pressure ulcers, infections and possibly death from any of the mentioned complications.<sup>[22]</sup> Such complications are not as frequent when spines are stabilized early, and patients encouraged to mobilize on wheel chair as appropriate with earlier hospital discharge and better rehabilitation.<sup>[1,21]</sup> These advantages were lacking as evidenced by the outcome of conservative management of Nnadi and Bankole.<sup>[18]</sup>



The neurology in acute SCI is classified using the Frankel's classification of neurological deficits.<sup>[23]</sup> Frankel grading in this study varied widely with etiology of cord compression. Cord compressions from trauma are classified as complete or incomplete. Complete cord injury corresponds to Frankel's Grade A while incomplete could be from Grade B to Grade D. The concept of spinal shock is worth noting. This highlights the controversy of the patients initially classified as complete but to be later recategorized as incomplete on recovery from the spinal shock. Seventeen patients (22.9%) in this series presented with Frankel's Grade A of SCI.

It is challenging to differentiate between mortalities attributable to surgical intervention as complication and outcome from the disease process, especially in traumatic high cervical spine injury. Higher cervical level injuries are associated with muscle spasms and respiratory distress, which could result in the patient being dependent on respiratory supports. Such patients after surgery may maintain the preoperative neurology or deteriorate to the point of death from the complications of respiratory distress.<sup>[22]</sup>

In a study comparing outcome of late and early surgery, there were indications that mortality is higher in patients operated early as against those operated late in traumatic cervical injury.<sup>[14]</sup> This observation is possible in a setting where the severe cervical injuries with high mortality might have died leaving the relatively low risk injuries by "natural selection." In this study, 5 (14.3%) patients died after the surgery. They were all in the cervical spine group and died of respiratory failure. Our practice is to give patients with cord injury the best chance possible. We have Intensive Care Unit support, and therefore, we decompress the cord and stabilize the spine as soon as possible while we continue to resuscitate the patients. Many other studies supports that neurology improves with early decompression.<sup>[3,15]</sup>

There are challenges to accessing appropriate health care in a resource poor country. In addition to this challenge is the lack of instrumentations and expertise. Despite the challenges, spine decompression can and should be done when indicated and where manpower is available. The chances of recovery from cord compression are better when cord decompression is done regardless of the etiological factors.

## CONCLUSION

Spine stabilization in addition to cord decompression enhances the rehabilitation of unstable and complete spine injuries. Our experience shows acceptable improvement in neurological function in patients with spinal cord decompression despite the challenges of

instrumentation in Sub-Saharan Africa. Larger series with longer follow-up period are necessary in our subregion to conclusively justify the benefits of cord decompression.

## Financial support and sponsorship

Nil.

## Conflicts of interest

There are no conflicts of interest.

## REFERENCES

- Krueger H, Noonan VK, Trenaman LM, Joshi P, Rivers CS. The economic burden of traumatic spinal cord injury in Canada. *Chronic Dis Inj Can* 2013;33:113-22.
- DeVivo MJ. Causes and costs of spinal cord injury in the United States. *Spinal Cord* 1997;35:809-13.
- Jug M, Kejzar N, Vesel M, Al Mawed S, Dobravec M, Herman S, *et al.* Neurological recovery after traumatic cervical spinal cord injury is superior if surgical decompression and instrumented fusion are performed within 8 hours versus 8 to 24 hours after injury: A single center experience. *J Neurotrauma* 2015;32:1385-92.
- Shrivastava S, Sakale H, Dulani R, Singh PK, Sanrakhia M. Role of decompression in late presentation of cervical spinal cord disorders. *Asian Spine J* 2014;8:183-9.
- Fehlings MG, Vaccaro A, Wilson JR, Singh A, W Cadotte D, Harrop JS, *et al.* Early versus delayed decompression for traumatic cervical spinal cord injury: Results of the Surgical Timing in Acute Spinal Cord Injury Study (STASCIS). *PLoS One* 2012;7:e32037.
- Jiang JM, Jin DD, Chen JT, Wang JX, Zhu ZG, Zhai DB, *et al.* Decompression and internal fixation in the treatment of thoracolumbar spine and spinal cord injury: Report of 166 cases. *Di Yi Jun Yi Da Xue Xue Bao* 2002;22:82-3.
- Rosenfeld JF, Vaccaro AR, Albert TJ, Klein GR, Cotler JM. The benefits of early decompression in cervical spinal cord injury. *Am J Orthop (Belle Mead NJ)* 1998;27:23-8.
- Chen Y, Tang Y, Allen V, DeVivo MJ. Fall-induced spinal cord injury: External causes and implications for prevention. *J Spinal Cord Med* 2016;39:24-31.
- Hua R, Shi J, Wang X, Yang J, Zheng P, Cheng H, *et al.* Analysis of the causes and types of traumatic spinal cord injury based on 561 cases in China from 2001 to 2010. *Spinal Cord* 2013;51:218-21.
- Díaz-Borrego P, Morillo-Leco G, Sáenz-Rodríguez L, Alcaraz-Rousselet MA. Spinal cord injury due to osteoarticular causes. *Rev Neurol* 2005;41:137-40.
- Mazel C, Trabelsi R, Antonietti P. Systematic circumferential (360 degree) decompression treatment of major arthrotic cervical stenosis. *Rev Chir Orthop Reparatrice Appar Mot* 2002;88:449-59.
- Wu AM, Zheng YJ, Lin Y, Wu YS, Mao FM, Ni WF, *et al.* Transforaminal decompression and interbody fusion in the treatment of thoracolumbar fracture and dislocation with spinal cord injury. *PLoS One* 2014;9:e105625.
- Smith JS, Anderson R, Pham T, Bhatia N, Steward O, Gupta R. Role of early surgical decompression of the intradural space after cervical spinal cord injury in an animal model. *J Bone Joint Surg Am* 2010;92:1206-14.
- Liu Y, Shi CG, Wang XW, Chen HJ, Wang C, Cao P, *et al.* Timing of surgical decompression for traumatic cervical spinal cord injury. *Int Orthop* 2015;39:2457-63.

15. Rahimi-Movaghar V, Niakan A, Haghnegahdar A, Shahlaee A, Saadat S, Barzideh E. Early versus late surgical decompression for traumatic thoracic/thoracolumbar (T1-L1) spinal cord injured patients. Primary results of a randomized controlled trial at one year follow-up. *Neurosciences (Riyadh)* 2014;19:183-91.
16. Batchelor PE, Wills TE, Skeers P, Battistuzzo CR, Macleod MR, Howells DW, *et al.* Meta-analysis of pre-clinical studies of early decompression in acute spinal cord injury: A battle of time and pressure. *PLoS One* 2013;8:e72659.
17. La Rosa G, Conti A, Cardali S, Cacciola F, Tomasello F. Does early decompression improve neurological outcome of spinal cord injured patients? Appraisal of the literature using a meta-analytical approach. *Spinal Cord* 2004;42:503-12.
18. Nnadi M, Bankole OB. Nonoperative treatment of acute traumatic spinal injuries: A prospective study. *Niger J Clin Pract* 2014;17:767-71.
19. Chang CM, Chen HC, Yang Y, Wang RC, Hwang WL, Teng CL. Surgical decompression improves recovery from neurological deficit and may provide a survival benefit in patients with diffuse large B-cell lymphoma-associated spinal cord compression: A case-series study. *World J Surg Oncol* 2013;11:90.
20. Papadopoulos SM, Selden NR, Quint DJ, Patel N, Gillespie B, Grube S. Immediate spinal cord decompression for cervical spinal cord injury: Feasibility and outcome. *J Trauma* 2002;52:323-32.
21. Chen TY, Dickman CA, Eleraky M, Sonntag VK. The role of decompression for acute incomplete cervical spinal cord injury in cervical spondylosis. *Spine (Phila Pa 1976)* 1998;23:2398-403.
22. Kawu AA, Alimi FM, Gbadegesin AA, Salami AO, Olawepo A, Adebule TG, *et al.* Complications and causes of death in spinal cord injury patients in Nigeria. *West Afr J Med* 2011;30:301-4.
23. Frankel HL, Hancock DO, Hyslop G, Melzak J, Michaelis LS, Ungar GH, *et al.* The value of postural reduction in the initial management of closed injuries of the spine with paraplegia and tetraplegia. I. *Paraplegia* 1969;7:179-92.

