

# Radiation-induced femoral head necrosis

IH Abdulkareem

Department of Trauma and Orthopaedics, Leeds University Teaching Hospitals, Leeds, UK

## Abstract

There are very few cases of radiation-induced femoral head necrosis described in the literature, therefore, this case will add new knowledge and highlights important aspects in the diagnosis and management of this uncommon condition. Our patient was 74 years old and presented with left hip and groin pain for 8 months, with no previous history of trauma or osteoarthritis. However, he had been treated for metastatic prostate cancer, to the pelvis and roof of the left acetabulum, with androgen ablation, and radiotherapy 5 years before presentation. Examination of the left hip revealed painful movements, but no restriction in the range of motion. Initial X-rays did not show any abnormalities, but MRI scan revealed a suspicious lesion in the roof of the left acetabulum, with no indication of secondary weakening of the femoral neck. The patient was therefore referred to the oncologists to consider radiotherapy, but they were not convinced it was metastatic, because he had no new urinary symptoms, and the PSA remained normal throughout this period. He was subsequently referred for a bone scan to look for possible secondary lesions (from the prostate gland), but this did not reveal any abnormal increased uptake. Three months later, he was reviewed in the clinic with a repeat X-ray of the pelvis which revealed complete destruction of the left femoral head and the acetabular roof, but CT-guided biopsy revealed no evidence of malignancy in the left hip. However, in view of the persistent pain and radiological evidence of left hip destruction, the patient had left Total Hip Replacement (THR), and excellent post-operative recovery. He mobilised fully, and was discharged on day five. Histology of the femoral head and hip capsule, revealed no evidence of metastasis from the prostate cancer, but confirmed osteonecrosis of the femoral head, presumably caused by the previous radiotherapy. MRI of the spine was clear and he was discharged to the oncologists and urologists for follow up

**Key words:** Cancer treatment, femoral head necrosis, radiation

**Date of Acceptance:** 25-Mar-2011

## Introduction

This is a case presentation of an uncommon condition called radiation-induced necrosis, involving the femoral head, otherwise known as osteonecrosis or Avascular Necrosis (AVN). Osteonecrosis is a well-described complication of radiotherapy for various cancers and pathologies. However, there are few documented cases of radiation-induced femoral head necrosis in the literature, and so it is believed that this case will add new knowledge and highlight important aspects in the management of this uncommon condition, which can be a diagnostic dilemma. Quinlan and colleagues<sup>[1]</sup> described a case of a 67-year-old man who developed bilateral osteonecrosis of the femoral head, following radiotherapy for a squamous cell carcinoma of the urethra. Dzik Jurasz *et al.*,<sup>[2]</sup>

reported an incidence of femoral head osteonecrosis of 4 out of 763 treated cases in their series. However, Massin's review of 71 irradiated hips following gynecologic cancers revealed a higher rate of osteonecrosis (24%).<sup>[3]</sup> The critical radiation dose above which osteonecrosis may occur is usually in the range of 3000-4000 rads (30-40 Gy).<sup>[4]</sup>

Avascular Necrosis (AVN) is defined as cellular death of bone components due to interruption of the blood supply; the bone structures then collapse, resulting in bone destruction, pain, and loss of joint function. AVN is associated with numerous conditions and usually involves

### Address for correspondence:

Dr. Imran H Abdulkareem,  
Registrars' Room, B Floor Clarendon Wing, Leeds General  
Infirmary, Great George Street, Leeds LS1 3EX, West Yorkshire, UK.  
E-mail: imranharuna@yahoo.com

### Access this article online

Quick Response Code:



Website: [www.njcponline.com](http://www.njcponline.com)

DOI: 10.4103/1119-3077.106787

PMID:

the epiphysis of long bones, such as femoral and humeral heads as well as femoral condyles, but small bones can also be affected. In clinical practice, AVN is most commonly encountered in the hip.

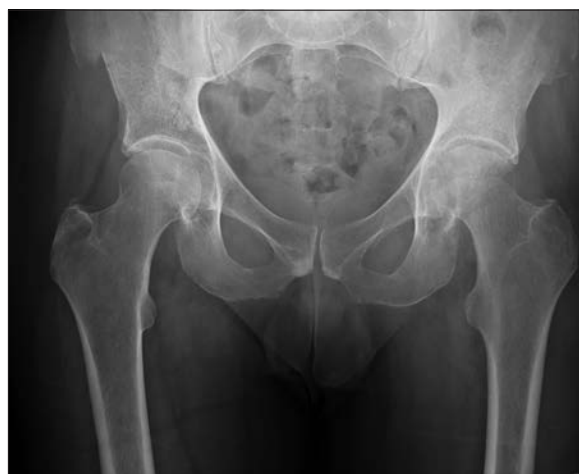### Case Report

The patient was a 74-year-old retired Caucasian male, who presented from his general physician with pain in the left hip and groin of 8-month duration, which had been progressive and became worse recently. He was systemically well and had no history of trauma or osteoarthritis in the left hip. However, he had a history of prostate cancer, with metastases to the pelvis and roof of the left acetabulum, which was treated with androgen ablation, as well as radiotherapy 5 years before presentation. He also previously had open medial menisectomy of the left knee following medial meniscal tear due to trauma, as well as right ankle Open Reduction and Internal Fixation (ORIF), 50 years previously.

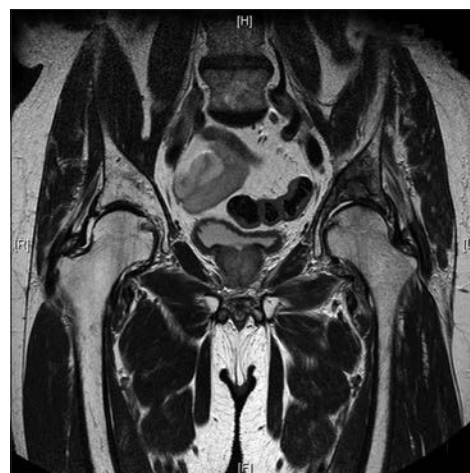Examination of the left hip revealed painful movements, but no restriction in the range, and the rest of the general examination was normal. Initial X-rays of the pelvis and left hip did not show any abnormalities (appendix). Subsequent pelvic X-ray a few weeks later, revealed subtle destruction of the left femoral head, consistent with early AVN [Figure 1].

A Magnetic Resonance Imaging (MRI) scan of the hip and pelvis revealed the presence of a suspicious lesion in the roof of the left acetabulum, with decreased signal in the left femoral head and marrow edema, suggestive of early osteonecrosis [Figure 2]. However, there was no suggestion of femoral neck weakening requiring any prophylactic fixation or replacement at that stage of the patient's presentation.

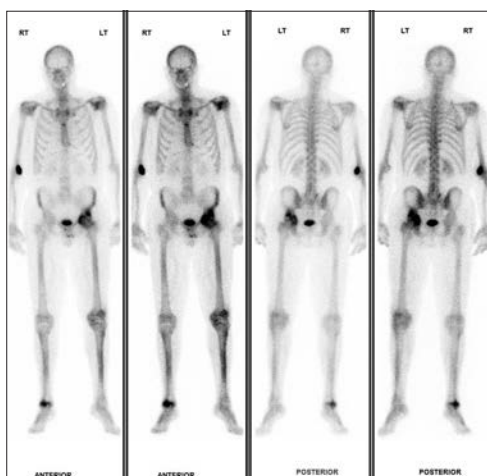
The patient was, therefore, referred to the oncologists to consider radiotherapy, but they were not convinced that the acetabular lesion was metastatic, as he had no new urinary symptoms, and the Prostate-Specific Antigen



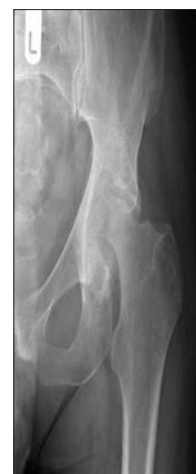**Figure 1:** AP Pelvis, showing early destruction (osteonecrosis) of the left femoral head



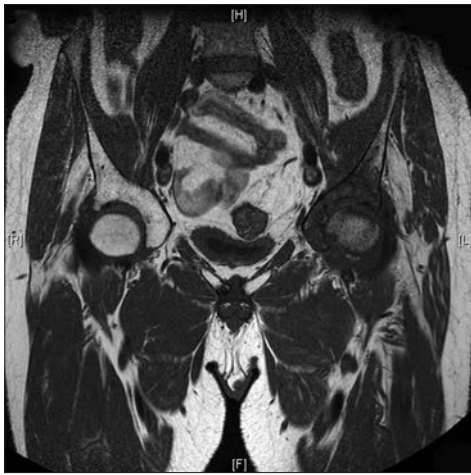**Figure 2:** T2 weighted MRI of the Pelvis showing destruction of the left acetabulum and decreased signal in the left femoral head, with marrow oedema



**Figure 3:** Bone scan, showing increased uptake in the left acetabulum and femoral head



**Figure 4:** AP Pelvis, showing gross destruction of the left femoral head and acetabulum

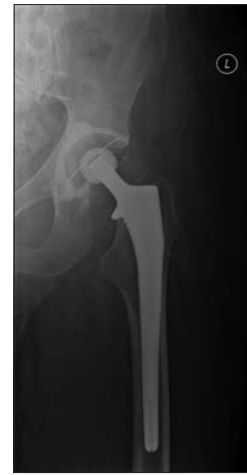

**Figure 5:** MRI scan showing decreased signal, marrow oedema, and gross destruction of the left femoral head and acetabulum

(PSA) remained normal throughout that period. He was then referred for a technetium bone scan to look for other secondary lesions. A Computed Tomography (CT)-guided biopsy was also arranged to confirm the diagnosis and consider prophylactic fixation or Total Hip Arthroplasty (THA). The bone scan [Figure 3] revealed increased uptake in the left acetabulum and femoral head, in keeping with AVN, but there were no other suspicious areas of increased uptake in the spine or axial skeleton to suggest metastases.

Three months later, he was reviewed in the clinic with a repeat X-ray of the pelvis [Figure 4], which revealed complete destruction of the left femoral head and the acetabular roof. In addition, his symptoms had progressively become worse, and he could not mobilise unaided. CT scan (appendix) and a repeat MRI at that stage [Figure 5] revealed decreased signal and severe destruction of the femoral head, in keeping with progressive osteonecrosis. The CT-guided biopsy revealed no evidence of malignancy in the left hip. Therefore, in view of the persistent pain and radiological evidence of left hip destruction, the patient had left Total Hip Replacement (THR) in 2008, with excellent postoperative recovery and mobilised full weight-bearing immediately [Figure 6].

He was discharged on the fifth day postoperatively and has had several uneventful clinic appointments so far. Histology of the femoral head and hip capsule revealed the presence of numerous inflammatory cell infiltrates, loss of fat cell outlines, widespread marrow edema, numerous tissue histiocytes, and replacement of necrotic marrow by undifferentiated mesenchymal tissue, consistent with osteonecrosis. There was no evidence of metastasis from the prostate cancer, and hence no further radiotherapy was suggested. He also complained of left knee pain, which was confirmed to be due to mild osteoarthritis, and temporarily relieved by intra-articular injection of Marcaine and Domperidone. MRI scan of the neck and spine revealed



**Figure 6:** AP Pelvis, showing satisfactory Cemented Left Total Hip Replacement (THR), post-operatively

no evidence of metastasis or vertebral collapse. The patient subsequently improved with analgesia and physiotherapy and the post-surgical history was uneventful.

### Literature Review and Discussion

Fu *et al.*,<sup>[5]</sup> have previously described radiation osteitis and insufficiency fractures in women after pelvic irradiation for gynecologic malignancies. They noted that damage to the pelvic bones after radiotherapy for gynecologic malignancies was uncommon with megavoltage radiotherapy, but can be misdiagnosed as bony metastases, and therefore should be considered as a diagnosis of exclusion. They reported 12 women treated for various malignancies, who developed osteitis, femoral head or neck necrosis, or insufficiency fractures after radiotherapy.

Our patient similarly presented 5 years following pelvic radiotherapy for metastatic prostate cancer (although records of the dose of radiation received by the patient could not be obtained from the oncologists at the time of this review), and there was a delay in diagnosis, as his symptoms and presentation were initially thought to be a result of another metastatic episode rather than radiation-induced AVN of the femoral head. Other differentials considered include previous trauma such as femoral neck fracture, Gaucher's disease, hemoglobinopathies, dysbaric osteonecrosis, steroid therapy, alcoholism, gout/hyperuricemia, and idiopathic osteonecrosis.<sup>[6]</sup> However, in this case, there was a strong association with previous radiotherapy involving the pelvis and hips, even though only the left hip was affected by osteonecrosis, perhaps resulting from a higher radiation dose on the left hip as compared to the contralateral (right) hip, or even inadequate shielding of the left hip during the radiotherapy. Therefore, a high index of suspicion is required to arrive at the diagnosis to prevent further disability to the patient.

In 1995, Grigsby *et al.*,<sup>[7]</sup> evaluated the risk of femoral neck fracture in a large series of patients (1313) with gynecologic cancers who underwent groin radiotherapy. Among these patients, the incidence of femoral neck fracture was 4.8% (10/207); 4 patients developed femoral fractures, and the cumulative actuarial incidence of fracture was 11% at 5 years and 15% at 10 years. They concluded that femoral head fractures was a common complication of groin irradiation for gynecologic malignancies, presumably due to AVN and also recommended special precautions in treatment (radiotherapy) planning to reduce the incidence of this complication.

Hanif *et al.*,<sup>[8]</sup> also described AVN of the femoral head in 15 pediatric patients treated for cancer in a major pediatric oncology center over a period of 15 years. The age range was 7-27 years, and most of them had radiotherapy and steroid treatments for hematologic and other solid pediatric malignancies. Hence, like adult patients, those who received high doses of local radiotherapy involving the femoral heads are at a great risk of AVN, and should thus be placed on close surveillance so that they can be diagnosed and treated as early as possible, to prevent disability.

Several treatment options have been described in the literature<sup>[9]</sup> for osteonecrosis and include use of pharmacologic agents such as naftidrofuryl, statins, stanozolol, heparin, coumadin, enoxaparin, iloprost and bisphosphonate. Other options include pulsed electromagnetic fields, electrical stimulation with current, extracorporeal shock wave therapy, biologic treatment modalities, and hyperbaric oxygen therapy. Surgical options include cementation of the femoral head, use of tantalum, arthrodiastasis, core decompression, osteotomy, muscle pedicle graft, as well as bipolar prosthetic and total joint replacements. Our patient was offered left total hip replacement because of his age, level of symptoms, and extent of femoral head destruction. He did well postoperatively and mobilised full weight-bearing within a few days.

## Conclusion

Femoral head osteonecrosis following radiotherapy is an uncommon condition, which requires a high index of suspicion to prevent delay in diagnosis and reduce patient suffering and disability. It is recommended that during radiotherapy, there should be proper shielding of vital structures and organs, use of multifield technique, treatment of all fields everyday to reduce total radiation dose, and awareness of tolerance doses of radiation, as the means of preventing or reducing the risk of femoral head necrosis.

## References

1. Quinlan JF, North J, Clarke DA, Gwynne-Jones DP. Radiation-induced osteonecrosis of the hips following genital-preserving surgery and chemoradiotherapy. *N Z Med J*. 2009 Jun 19;122(1297):84-6
2. Dzik-Jurasz AS, Brooker S, Husband JE, Tait D. What is the prevalence of symptomatic or asymptomatic femoral head osteonecrosis in patients previously treated with chemoradiation? A magnetic resonance study of anal cancer patients. *Clin Oncol (R Coll Radiol)* 2001;13:130-4.
3. Massin P, Duparc J. Total hip replacement in irradiated hips. A retrospective study of 71 cases. *J Bone Joint Surg Br* 1995;77:847-52.
4. Libshitz H, Edeiken B. Radiotherapy changes of the paediatric hip. *AJR Am J Roentgenol*. 1981 Sep;137(3):585-8
5. Fu AL, Greven KM, Maruyama Y. Radiation osteitis and insufficiency fractures after pelvic irradiation for gynaecological malignancies. *Am J Clin Oncol* 1994;17:248-54.
6. Hungerford DS, Lennox DW. The importance of increased intraosseous pressure in the development of osteonecrosis of the femoral head: Implications for treatment. *Orthop Clin North Am* 1985;16:635-54.
7. Grigsby PW, Roberts HL, Perez CA. Femoral neck fracture following groin irradiation. *Int J Radiat Oncol Biol Phys* 1995;32:63-7.
8. Hanif I, Mahmoud H, Pui CH. Avascular femoral head necrosis in pediatric cancer patients. *Med Paediatr Oncol* 1993;21:655-60.
9. Mont MA, Jones LC, Seyler TM, Marulanda GA, Saleh KJ, Delanois RE. New treatment approaches for osteonecrosis of the femoral head: An overview. *Instr Course Lect* 2007;56: 197-212.

**How to cite this article:** Abdulkareem IH. Radiation-induced femoral head necrosis. *Niger J Clin Pract* 2013;16:123-6.

**Source of Support:** Nil, **Conflict of Interest:** None declared.