

The prevalence of cervical ribs in Enugu, Nigeria

SN Ezeofor, NR Njeze, MN Aghaji¹, AC Onuh, EN Obikili²

Departments of Radiation Medicine, ¹Community Medicine and ²Anatomy, College of Medicine, University of Nigeria, Enugu Campus, Enugu State, Nigeria

Abstract

Background: Cervical rib is an important cause of nontraumatic thoracic outlet neurovascular compression. This study was undertaken as there is no known documented report on its prevalence in the study environment.

Aims: To evaluate the prevalence of cervical ribs and its variation with sex and age among patients presenting at radiological facilities for a chest radiograph.

Settings and Design: Retrospective evaluation of plain posterior-anterior view chest radiographs done in radiological facilities in Enugu, Southeast, Nigeria.

Subjects and Methods: Evaluated in this study were all 6571 chest radiographs consecutively obtained between 2009 and 2012 in three randomly selected radiological facilities in Enugu.

Statistical Analysis Used: SPSS version 17 software was used in data analysis. Chi-square and student *t*-tests were used to test for the significance of findings at 95% confidence level.

Results: This study reports the overall prevalence of cervical ribs as 48 (0.7%) with a significantly higher rate in females 43 (1.1%) when compared to males 5 (0.2%) ($P = 0.000$). In 27 (0.4%) cases, the cervical ribs were bilateral; whereas in 21 (0.3%) cases, they were unilateral with 8 (0.1%) on the left and 13 (0.2%) on the right. There was no age-related variability with prevalence ($P = -0.813$).

Conclusions: The prevalence of cervical rib in the study population is low and within the known range as seen in other geographical regions of Nigeria.

Key words: Cervical ribs, chest radiographs, Nigeria

Date of Acceptance: 18-Nov-2015

Introduction

Cervical rib results from a failure of regression of the costal process of the seventh cervical rib. Cervical rib is an important cause of nontraumatic thoracic outlet neurovascular compression. This study was undertaken as there is no known documented report on its prevalence in the study environment.^[1-4]

Address for correspondence:

Dr. SN Ezeofor,
Department of Radiation Medicine, College of Medicine,
University of Nigeria, Enugu Campus, Enugu State, Nigeria.
E-mail: salome.ezeofor@unn.edu.ng

Access this article online

Quick Response Code: 	Website: www.njcponline.com
	DOI: 10.4103/1119-3077.183315
	PMID: 27251970

This study aims to evaluate the prevalence of cervical ribs and its variation with sex and age among patients presenting at radiological facilities for chest radiograph in Enugu, Nigeria.

Subjects and Methods

The study has a retrospective design.

About, 3 of 20 radiological facilities in Enugu, Nigeria, were selected by simple random sampling. A review of all plain

This is an open access article distributed under the terms of the Creative Commons Attribution-NonCommercial-ShareAlike 3.0 License, which allows others to remix, tweak, and build upon the work non-commercially, as long as the author is credited and the new creations are licensed under the identical terms.

For reprints contact: reprints@medknow.com

How to cite this article: Ezeofor SN, Njeze NR, Aghaji MN, Onuh AC, Obikili EN. The prevalence of cervical ribs in Enugu, Nigeria. *Niger J Clin Pract* 2016;19:513-6.

posterior-anterior view chest radiographs obtained between January 2009 and December 2012 at the selected facilities was carried out. The radiographs were examined with good viewing boxes in a room with low ambient light levels by four of the researchers who are consultant radiologists. There were 6571 chest radiographs of posterior-anterior views. The inclusion criteria are radiographs with the root of the neck clearly visualized and records of the patient's sex and age available. The exclusion criteria are radiographs with the root of the neck cutoff or poorly visible or whose sex and age records were unavailable. Information collected included the patient's sex, age, and the presence and position of cervical ribs.

The following diagnostic criteria for a cervical rib were adopted:^[5,6]

- The rib must abut the seventh cervical vertebral transverse process, which is seen to project horizontally or caudally from the spine, rather than the transverse process of the first thoracic vertebra which extends diagonally upward from the point of origin
- It must have no connection with the manubrium sterni, although it may form a synostosis with the first rib thus distinguishing it from a rudimentary first rib.

Ethical clearance for this study was obtained from the hospital ethical committee. The patients' identities were removed from the submitted images.

The SPSS version 17 software (Chicago, Illinois, USA) was used in data analysis. Chi-square and student *t*-tests were used to test for the significance of findings at 95% confidence level.

Results

Of the 6571 radiographs, 3922 (59.7%) were from females and 2649 (40.3%) were from males. The age range of the cases was 11–92 years, and their mean age was 31.8 ± 11 years.

A total of 48 cases had cervical ribs giving an overall prevalence of 0.7%. In 27 (0.4%) cases, the cervical ribs were bilateral, [Figure 1] while in 21 (0.3%) cases, they

were unilateral with 13 (0.2%) on the right [Figure 2] and 8 (0.1%) on the left [Figure 3].

A significantly higher prevalence of cervical ribs was found in females 43 (1.1%) when compared to males 5 (0.2%) ($P = 0.000$). The mean age of cases with cervical ribs was 31.4 ± 7.2 years, and it did not differ from those of cases without ribs 31.8 ± 11.1 years ($P = 0.813$) [Table 1].

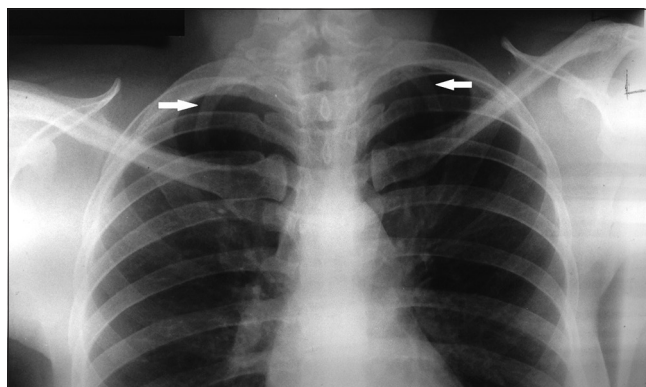


Figure 1: PA chest radiograph showing bilateral cervical ribs (white arrows)

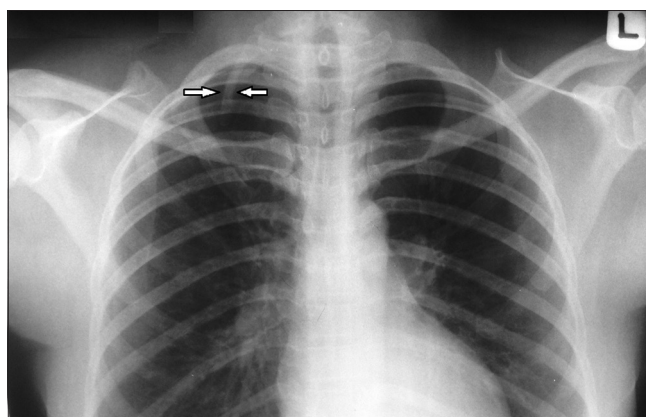


Figure 2: PA chest radiograph showing a right-sided cervical rib (white arrows)

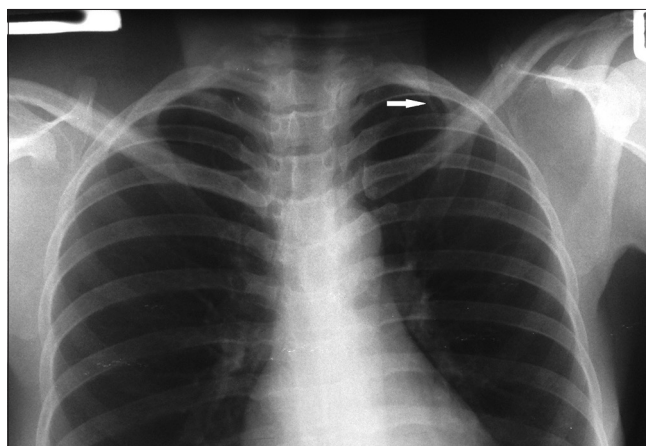


Figure 3: PA chest radiograph showing a left-sided cervical rib (white arrow)

Table 1: Prevalence of cervical ribs in Enugu, Nigeria				
	Female n (%)	Male n (%)	Total n (%)	P
Cervical ribs				
Yes	43 (1.1)	5 (0.2)	48 (0.7)	0.000
No	3879 (98.9)	2644 (99.8)	6523 (99.3)	
Position				
None	3879 (98.9)	2644 (99.8)	6523 (99.3)	
Bilateral	24 (0.6)	3 (0.1)	27 (0.4)	
Unilateral	19 (0.5)	2 (0.1)	21 (0.3)	
Right	12	1	13	
Left	7	1	8	
Total	3922 (100.0)	2649 (100.0)	6571 (100.0)	

Discussion

Cervical rib is a congenital defect during bone formation. It develops from the costal process of the primitive vertebral arches. In the fetus, the costal element which is separate initially, later regresses, and fuses with the transverse process to form the anterolateral boundary of the foramen transversarium. If the costal process of the seventh cervical rib continues to develop, it may result in a cervical rib, which is separate from the vertebra.^[1] It can lead to neurovascular compression which can give rise to thoracic outlet syndrome.^[7]

The evidence for the presence of cervical ribs dates back to the 150 AD (150 years after the death of Christ) when it was first described in human cadaver dissections by Galen, a Greek anatomist and later by Andreas Vesalius in the 15th century.^[8] Astley Cooper, in 1818, was the first to assemble the clinical symptoms of neurovascular compression associated with a cervical rib.^[9]

In St. Bartholomew's Hospital London in 1861, Coote diagnosed a cervical rib on clinical grounds. He further performed the first cervical rib resection to restore the radial pulse in a female patient.^[10]

A significantly higher prevalence of cervical rib anomalies has been demonstrated in stillborn fetuses and in childhood cancer patients, especially acute lymphoblastic leukemia, astrocytoma, and germ cell tumors.^[6,11,12] In cases of suspected child abuse, cervical rib presence may be mistaken for fracture of the first rib.^[1]

The majority of patients with cervical ribs are asymptomatic and in patients requiring operation for thoracic outlet syndrome, only 8–10% actually has cervical rib as demonstrated in previous reports.^[2-4]

This present study which showed a cervical rib prevalence of 0.7% and sex differential prevalence of 1.1% for females and 0.2% for males falls within the 0.58–24.9% range reported in Nigeria^[13,14] and most other countries.^[15-20] Comparison of these previous studies show that the highest prevalence was reported among the Asian population (24.9%),^[16] followed by the Turkish population (6.1%),^[17] the white British population (5.9%),^[16] the Saudi Arabians (3.4%),^[18] and then the Italians (2.5%),^[19] whereas the lowest prevalence was seen in the Malawian population (0.58%).^[15] A previous report^[16] highlighted that Asians are infected 5 times more likely to have cervical ribs when compared with the white British.

The present study also revealed that cervical ribs are more common in females, and this agrees with the above earlier studies^[13-20] among varied race, tribes, sample size, and

imaging techniques used but contrasts with the Central Indian Population study, which reported no gender difference in incidence.^[21] Researchers have been unable to suggest a reason for this gender difference in cervical ribs occurrence, and we can only allude it to creation.

The present study also revealed no age variation in cervical ribs occurrence.

Furthermore, in this study, there was a higher incidence of bilateral cervical ribs than unilateral. This is in agreement with a report from Lucknow (UP), on Indian population^[22] but is in contrast to studies from many other countries^[13-20] where their reports demonstrated that unilateral cervical ribs were seen more on the right than on the left, just like in this present study.

The cause of the variations measured is not immediately discernible, but it may be due to the differences in race and ethnicity, the population studied, the sample size, and the imaging techniques used. For instance, earlier reports on the English population^[23] showed the prevalence to be 0.05%, but a later study^[24] reported an incidence of 0.74% and this difference was said to be most likely due to advances in the imaging technique and equipment. Digital radiography allows the radiologist to alter brightness and contrast and thus obtain clearer images. Thus, the technique and quality of radiographs may affect the accuracy of diagnosis of cervical ribs, thereby influencing the prevalence rates obtained. In this study, films were of the conventional type.

Conclusions

The prevalence of cervical ribs in this environment is 0.7% and it is low. Clinicians, however, should always consider the presence of cervical rib in evaluating patients with neurovascular symptoms of the upper extremities. In our environment, future studies on this subject should aim to make use of digital radiography.

Financial support and sponsorship

Nil.

Conflicts of interest

There are no conflicts of interest.

References

- Oestreich AE. Cervical rib simulating fracture of the first rib in suspected child abuse. *Radiology* 1996;199:582.
- Roos DB. Congenital anomalies associated with thoracic outlet syndrome. Anatomy, symptoms, diagnosis, and treatment. *Am J Surg* 1976;132:771-8.
- Makhoul RG, Machleder HI. Developmental anomalies at the thoracic outlet: An analysis of 200 consecutive cases. *J Vasc Surg* 1992;16:534-42.
- Hempel GK, Shutze WP, Anderson JF, Bukhari HI. 770 consecutive supraclavicular first rib resections for thoracic outlet syndrome. *Ann Vasc Surg* 1996;10:456-63.

5. Etter LE. Osseous abnormalities of the thoracic cage seen in forty thousand consecutive chest photoroentgenogram. *Am J Roentgenol* 1944;51:359-63.
6. Merks JH, Smets AM, Van Rijn RR, Kobes J, Caron HN, Maas M, *et al.* Prevalence of rib anomalies in normal Caucasian children and childhood cancer patients. *Eur J Med Genet* 2005;48:113-29.
7. Storey JR, Tranmer BI. The patient complaining of numbness or weakness. In: Popp J, Tranmer BI, editors. *The Primary Care of Neurological Disorders*. Illinois: American Association of Neurological Surgeons; 1998. p. 157-70.
8. Roos DB, Annest SJ, Brantigan CO. Historical and anatomic perspectives on thoracic outlet syndrome. *Chest Surg Clin N Am* 1999;9:713-23.
9. Cooper A. *Exostosis in Surgical Essays*. 2nd ed., Vol. 1. London: Cox and Son; 1818. p. 167-72.
10. Coote H. Exostosis of the left transverse process of the seventh cervical vertebra, surrounded by blood vessels and nerves; successful removal. *Lancet* 1861;1:360-1.
11. Furtado LV, Thaker HM, Erickson LK, Shirts BH, Opitz JM. Cervical ribs are more prevalent in stillborn fetuses than in live-born infants and are strongly associated with fetal aneuploidy. *Pediatr Dev Pathol* 2011;14:431-7.
12. Bots J, Wijnaendts LC, Delen S, Van Dongen S, Heikinheimo K, Galis F. Analysis of cervical ribs in a series of human fetuses. *J Anat* 2011;219:403-9.
13. Ani CC, Adegbe EO, Amedaji M, Gabkwet A. Cervical rib variant in a Nigerian population. *Jos J Med* 2012;6:60-2.
14. Abimbola EO, Willido AA. Prevalence of cervical ribs in a Nigeria population. *J Dent Med Sci* 2014;13:5-7.
15. Ebite LE, Igbigbi PS, Chisi JE. The prevalence of true cervical rib in adult Malawian population. *J Anat Sci* 2005;(1):7-9.
16. Tryfonidis M, Anjarwalla N, Cole A. Incidence of cervical rib in the white British population and direct comparison with the incidence in the Asian population: A radiological study. *J Bone Joint Surg Br* 2010;92 Suppl 4:499.
17. Erken E, Ozer HT, Gulek B, Durgun B. The association between cervical rib and sacralization. *Spine (Phila Pa 1976)* 2002;27:1659-64.
18. Bokhari RF, Al-Sayyad MJ, Baeesa SS. Prevalence of cervical ribs and elongated transverse processes in Saudi Arabia. *Saudi Med J* 2012;33:66-9.
19. Palma A, Carini F. Variation of the transverse apophysis of the 7th cervical vertebra: Anatomico-radiological study of an isolated population. *Arch Ital Anat Embriol* 1990;95:11-6.
20. Viertel VG, Intrapromkul J, Maluf F, Patel NV, Zheng W, Alluwaimi F, *et al.* Cervical ribs: A common variant overlooked in CT imaging. *AJNR Am J Neuroradiol* 2012;33:2191-4.
21. Sharma DK, Vishnudutt, Sharma V, Rathre M. Prevalence of cervical rib and its association with gender body side, handedness and other thoracic bony anomalies in a population of central India. *India J Basic Appl Med Res* 2014;3:593-7.
22. Gupta A, Gupta DP, Saxena DK, Gupta RP. Cervical ribs: It's prevalence in Indian population around Lucknow (UP). *J Anat Soc India* 2012;61:189-91.
23. Adson AV, Coffey JR. Cervical rib: A method of anterior approach for relief of symptoms by division of the scalenus anticus. *Ann Surg* 1927;85:839-57.
24. Brewin J, Hill M, Ellis H. The prevalence of cervical ribs in a London population. *Clin Anat* 2009;22:331-6.