

## Original Article

# Clinical Outcomes after Open Locked Intramedullary Nailing of Closed Femoral Shaft Fractures for Adult Patients in a Nigerian Hospital

ON Salawu, GH Ibraheem<sup>1</sup>, OM Babalola<sup>1</sup>, DM Kadir<sup>2</sup>, BA Ahmed<sup>1</sup>, SB Agaja<sup>1</sup>, A Olawepo<sup>1</sup>, AA Nasir<sup>1</sup>

Department of Surgery,  
Federal Medical Centre,  
Birnin Kebbi, <sup>1</sup>Department  
of Surgery, University of  
Ilorin Teaching Hospital,  
<sup>2</sup>Department of Surgery,  
General Hospital, Ilorin,  
Nigeria

### ABSTRACT

**Background:** Femoral shaft fractures are common injuries in adults. Closed locked intramedullary nailing is the recommended treatment for femoral shaft fractures due to its high union rate. **Objective:** The objective of this study is to determine the outcome of management of closed femoral shaft fractures in adult patients, using open locked intramedullary nailing. **Patients and Methods:** This is a prospective study which was carried out on all adult patients aged 16 years and above who presented within 2 weeks of sustaining closed femoral shaft fractures to the accident and emergency unit of a University Teaching Hospital in Nigeria from January 2013 to December 2013. Pathological fractures were excluded from the study. The procedure was carried out using standard techniques, and each patient was followed up for a minimum of 1 year. **Results:** Forty-three patients were recruited into the study. They had a mean age of  $36.9 \pm 11.7$  years, with a male to female ratio of 2.9:1. The most common cause of closed femoral shaft fractures was road traffic crashes (95.3%), with motorcycle-related injuries found to be the highest type (56.1%). The rate of union in the study was 95.3%. The average time to radiological union was  $14.0 \pm 1.2$  weeks while the mean time to painless full weight bearing was  $14.2 \pm 1.2$  weeks. Among the complications encountered were broken nails (4.7%), infection, loosening of the distal screw, and limb length discrepancy (2.3% each). Using Thoresen's criteria, excellent results were obtained in 93% and poor results in 4.7% of patients. **Conclusion:** Open locked intramedullary nailing gives excellent clinical outcomes with high union and low complication rates in the management of closed femoral shaft fractures in adult patients.

**KEYWORDS:** *Clinical union, femoral shaft fracture, open locked intramedullary nail, radiological union, Thoresen's criteria*

**Date of Acceptance:**  
14-Jun-2017

## INTRODUCTION

Femoral shaft fractures are common injuries in adults and may result into major morbidity or even mortality if not adequately treated.<sup>[1-3]</sup>

A femoral shaft fracture is a break in continuity of the femoral shaft and it is said to be closed when the fracture site does not communicate with the exterior. It commonly affects patients in their productive age and frequently occurs following road crashes.<sup>[4,5]</sup> Femoral shaft fracture patterns vary according to the direction of the force applied and the amount of force absorbed. The amount

of comminution present increases with the amount of energy absorbed by the femur at the time of fracture.<sup>[6]</sup>

Up to 40% of isolated femoral fractures may require transfusion because closed femoral shaft fractures can result in loss of up to 1.5 liters of blood.<sup>[7]</sup> This blood loss is significant; hence, resuscitation is essential in these

**Address for correspondence:** Dr. GH Ibraheem,  
Department of Surgery, University of Ilorin  
Teaching Hospital, Ilorin, Nigeria.  
E-mail: [ghibraheem@yahoo.com](mailto:ghibraheem@yahoo.com)

This is an open access article distributed under the terms of the Creative Commons Attribution-Non Commercial-Share Alike 3.0 License, which allows others to remix, tweak, and build upon the work non-commercially, as long as the author is credited and the new creations are licensed under the identical terms.

**For reprints contact:** [reprints@medknow.com](mailto:reprints@medknow.com)

**How to cite this article:** Salawu ON, Ibraheem GH, Babalola OM, Kadir DM, Ahmed BA, Agaja SB, *et al.* Clinical outcomes after open locked intramedullary nailing of closed femoral shaft fractures for adult patients in a Nigerian Hospital. *Niger J Clin Pract* 2017;20:1316-21.

Access this article online	
Quick Response Code:	Website: <a href="http://www.njcponline.com">www.njcponline.com</a>
	DOI: 10.4103/njcp.njcp_294_16

patients before investigations and definitive treatment are carried out.

The treatment of femoral shaft fractures has undergone significant evolution over the past century. Before the 20<sup>th</sup> century, the definitive treatment method was traction or splinting. These methods were associated with several complications such as poor control of length and alignment, pin tract infection, nonunion, and joint stiffness due to prolonged immobilization.<sup>[8,9]</sup> Open reduction and internal fixation have reduced some of these complications by enabling early mobilization of the patient after surgery. The gold standard for treating closed femoral shaft fractures currently is closed locked intramedullary nailing.<sup>[10-13]</sup> This requires the use of an image intensifier. In the absence of this, the fracture site can be opened up, and the procedure done using an external targeting device to guide the locking of the nail. This is termed open locked intramedullary nailing.<sup>[14]</sup> Opening the fracture site causes loss of the nutrient-rich fracture hematoma with the potential effect of delaying union. The surgical wound also heals with fibrosis with the potential for joint stiffness. Studies on open intramedullary nailing have however shown comparable outcomes to closed nailing with regard to rate and time of union.<sup>[4]</sup>

The aim of this study was to assess the clinical outcome of treatment of closed femoral shaft fractures in adults using open locked intramedullary nailing in our center.

## PATIENTS AND METHODS

This was a prospective, descriptive hospital-based study carried out over a 12 months period (January 2013–December 2013). All consecutive patients 16 years and above who presented to our institution within 2 weeks of sustaining a closed femoral shaft fracture were recruited into the study. Patients with pathological fractures were excluded from the study. Informed consent was taken from all patients before recruitment.

Patient demographic data, details of the injury, radiologic investigations, treatment, and outcome were recorded on a structured questionnaire. All patients were evaluated, resuscitated, and prepared for surgery. Anesthesia consisted of subarachnoid block in 26 (60.5%) patients, epidural block in 16 (37.2) patients, and general anesthesia in 1 (2.3%) patient. All patients were managed with open locked intramedullary nailing using Surgical Implant Generation Network (SIGN<sup>®</sup>) nails.

The technique is as described below:

The maximum length of the nail to be used was determined by measuring the distance from the greater

trochanter to the superior pole of the patella on the unaffected limb. Antegrade technique [Figure 1] was the preferred method of insertion, but a retrograde technique [Figure 2] was employed in instances where the fracture was close to the distal end of the femur. An entry point to the femur was created using a bone awl, and the proximal fragment was reamed progressively up to a size 11 mm reamer. Fracture reduction was achieved by making a 3-7 cm incision at the fracture site through which the distal fragment was reamed. A 9 mm diameter nail of appropriate length determined preoperatively was passed through the proximal fragment and guided into the distal fragment through the fracture site incision. An external targeting device attached to the nail was used to insert locking screws into the distal fragment. The fracture was compressed, and proximal locking screws were then inserted after ensuring proper rotational alignment of the limb.

Each patient was followed up for 1 year. During each visit, clinical status of the limb was assessed using the Thoresen's criteria. X-rays were done in the immediate postoperative period to assess fracture reduction and fixation. Follow-up x-rays were taken at 6 and 12 weeks posttreatment to assess for progression of healing. Subsequent x-rays were taken every 4 weeks until radiological union was achieved. Radiological union was taken as the presence of callus bridging three cortices seen on two different views of the fracture site.

Data obtained was analyzed using the Statistical Package for the Social Sciences software version 17 (SPSS Inc, Chicago, USA). Fisher's exact test was used to determine the statistical significance between qualitative variables. Relationship of difference in  $P < 0.05$  was accepted as statistically significant.

## RESULTS

During the study period, 43 patients with 43 closed femoral shaft fractures were recruited and managed with open locked intramedullary nailing. There were 32 male and 11 female giving a male to female ratio of 2.9:1. Their ages ranged from 20 to 60 years, with a mean age

**Table 1: Causes of femoral shaft fractures**

Causes	n (%)
Road traffic crash	41 (95.3)
Fall from height	2 (4.7)
Types of road traffic crash	
Motorcycle	23 (56.1)
Car	8 (19.5)
Bus	7 (17.1)
Truck	2 (4.9)
Pedestrian	1 (2.4)

**Table 2: Fracture characteristics**

	<i>n</i> (%)
Side	
Right	28 (65.1)
Left	15 (34.9)
Site	
Proximal third	6 (14.0)
Middle third	27 (62.8)
Distal third	10 (23.2)
Configuration	
Transverse	23 (53.4)
Comminuted	14 (32.6)
Segmental	3 (7.0)
Spiral	2 (4.7)
Oblique	1 (2.3)

**Table 3: Distribution of fractures according to AO/OTA classification**

AO/OTA classification	Number of patients (%)
A1	2 (4.7)
A2	1 (2.3)
A3	23 (53.4)
B1	2 (4.7)
B2	2 (4.7)
B3	1 (2.3)
C1	6 (13.9)
C2	3 (7.0)
C3	3 (7.0)
Total	43 (100)

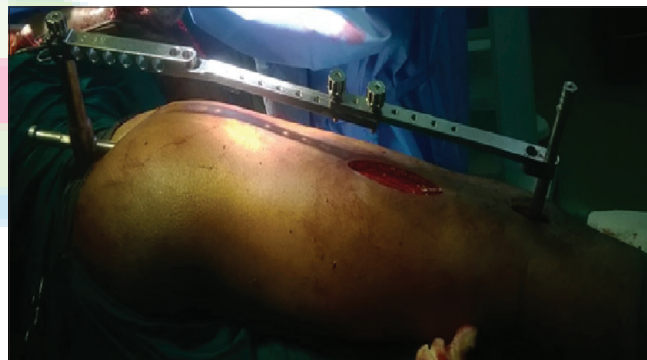**Table 4: Types of complications**

Complication	<i>n</i> (%)
Superficial wound infection	1 (2.3)
Limb length discrepancy	1 (2.3)
Broken implant (nail)	2 (4.7)
Loose screw	1 (2.3)
Total	5 (11.6)

of  $36.9 \pm 11.7$ . The most common cause of femoral shaft fractures was road traffic crashes, and among the road traffic crashes, motorcycle-related crashes constituted the highest group (56.1%,  $n = 23$ ) as shown in Table 1.

Femoral shaft fractures were found to be more common on the left side (65%,  $n = 28$ ) than the right side (35%,  $n = 15$ ). The middle third of the femoral shaft was the most frequent part affected (62.8%,  $n = 27$ ) while transverse configuration was the most common configuration seen (53.4%,  $n = 23$ ) as shown in Table 2. Using the AO/OTA classification, simple fractures (Type A) were the most common class (60.4%) while wedge fractures (Type B) were the least common (11.7%) as shown in Table 3. The anesthetic techniques employed varied from subarachnoid block in 26 (60.5%) patients, to epidural block in 16 (37.2%) patients, and general anesthesia in one (2.3%) patient.

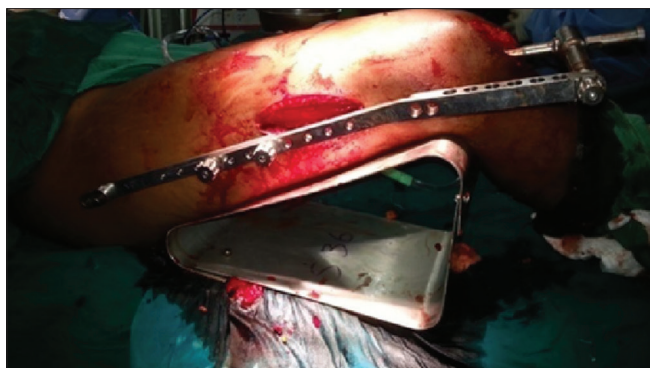
The union rate of femoral shaft fractures in this study was 95.3%. The mean time to radiological union was  $14.0 \pm 1.2$  weeks, with a range of 11–16 weeks. The mean time to painless full weight bearing was  $14.2 \pm 1.2$  weeks, with a range of 11–16 weeks.



**Figure 1:** Antegrade approach: External jig attached to the inserted nail in antegrade approach

**Table 5: Result of outcome of treatment using Thoresen's criteria**

Criteria	Outcome of results				Total patients
	Excellent, number of patients (%)	Good, number of patients (%)	Fair, number of patients (%)	Poor, number of patients (%)	
Malalignment of femur					
Varus/valgus	41 (95.3)	0	0	2 (4.7)	43
Antevertum/recurvatum	43 (100.0)	0	0	0	43
Internal rotation	43 (100.0)	0	0	0	43
External rotation	43 (100.0)	0	0	0	43
Shortening of femur	42 (97.7)	0	1 (2.3)	0	43
Knee motion					
Flexion	43 (100.0)	0	0	0	43
Extension deficit	43 (100.0)	0	0	0	43
Pain/swelling	43 (100.0)	0	0	0	43
Nonunion/nail breakage	41 (95.3)	0	0	2 (4.7)	43



**Figure 2:** Retrograde approach: External jig attached to the inserted nail in retrograde approach

The postoperative complications consisted of broken nails in two patients (4.7%) and superficial wound infection, loosening of locking screw, and limb length discrepancy in one patient each as shown in Table 4.

The outcome of management was assessed for all patients using the Thoresen's criteria, which is designed to assess functional outcomes for femoral diaphyseal fractures. Thoresen's criteria assesses five groups of criteria as "excellent," "good," "fair," or "poor". Nearly 93% of patients ( $n = 40$ ) scored 'excellent' in all criteria; 2.3% scored "fair" in one of the criteria; and 4.7% scored "poor" in one of the criteria as shown in table 5. The patient with a fair result had limb shortening of about 3 cm postsurgery while both patients with poor results had nail breakage.

## DISCUSSION

To avoid unnecessary morbidity, femoral shaft fractures need to be adequately managed using sound orthopedic principles. The goal of treatment of these fractures is to achieve union in acceptable alignment while avoiding unnecessary morbidity. In this study, femoral shaft fractures were found to be three times more common in males than females. This is probably because males are more involved in rigorous activities to earn an income and hence more at risk of the injury. This pattern is similar to the findings of Akinyoola *et al.* and Sekimpi *et al.*<sup>[4,15]</sup>

The mean age was  $36.9 \pm 11.7$  years showing that femoral shaft fractures occur predominantly in the productive age group. This young age group represents the most active and mobile members of the society and as such are most susceptible to trauma. Similar results were found in studies by Ikpeme *et al.*, Dim *et al.*, and Ikem *et al.*, in which the mean age of patients with femoral shaft fractures reported were  $35 \pm 11.9$  years, 35 years, and  $35 \pm 13.2$  years, respectively.<sup>[14-17]</sup>

Road traffic crashes were the most frequent cause of femoral shaft fractures in this study accounting for 95.3% of all cases. This is similar to reports from Deepak *et al.* and Sekimpi *et al.* where road traffic crashes were identified as the most common cause of femoral diaphyseal fractures.<sup>[13,15]</sup> Road traffic crashes are frequent causes of injury in this environment. Risk factors which have been found to be associated with road traffic crashes include poor knowledge of road safety measures such as road signs and speed limit by the drivers, driving under the influence of alcohol, and bad roads.<sup>[18-21]</sup>

Further analysis revealed that of the various forms of road traffic crashes, motorcycle crashes were the most frequently seen in this study (56.1% of all crashes). The peculiarity of injuries sustained during a motorcycle crash is that there is a high-energy impact directly to the rider/passenger unlike vehicular injuries where the impact is often indirect. The reported risk factors for motorcycle crashes include riding under the influence of alcohol, carrying multiple passengers, and riding at night without headlamps. In addition, most commercial motorcycle riders in our environment are young males (<30 years of age) with low educational background and no formal training on the use of the motorcycle before they commence operation.<sup>[22-24]</sup>

The middle third of the femoral shaft was the most common part involved in fractures. This finding is similar to that of Naeem-Ur-Razaq *et al.* and Deepak *et al.*, who reported the middle third of the femoral shaft as the most common part affected in their studies.<sup>[13,25]</sup> However, Sekimpi *et al.* and Admaise *et al.* reported the distal third and the proximal third of femoral shaft respectively as the most common part involved in their studies.<sup>[15,26]</sup> The lack of uniformity of these findings may suggest that the three major divisions of the femoral shaft may be equally predisposed to fractures, with the point of impact determining the location of the fracture.

The most common fracture configuration in this study was transverse fractures seen in 23 cases (53.5%). Transverse fractures typically occur following a direct impact to the limb and have characteristically been reported as the most common major fracture configuration in femoral shaft fractures.<sup>[10,13,27]</sup>

The time to radiological fracture union was  $14.0 \pm 1.2$  weeks while the time to painless full weight bearing was  $14.2 \pm 1.2$  weeks after surgery. The duration of these two variables are very close though with a statistically significant association ( $P = 0.000$ ). The close correlation between these variables suggests that the ability of a patient to bear full weight on the affected limb without pain at the fracture site is indicative of

union. Caution should however be taken in commencing unprotected full weight bearing without radiological evidence of healing in view of medicolegal considerations. The time to union in his study is similar to the findings of Ertürer *et al.*, who reported 14 weeks as the mean duration to union in femoral shaft fractures managed with locked intramedullary nailing.<sup>[28]</sup> Soren in Kenya, however, found a longer time to union (18.5 weeks) in his study.<sup>[29]</sup> Soren's study, however, included nonunion and malunion in addition to fresh fractures. Ikpeme *et al.* reported  $17.2 \pm 5.9$  weeks as mean time to union after treatment of 23 femoral fractures with open locked intramedullary nailing.<sup>[14]</sup> The longer time to union reported in their study may also be due to inclusion of both fresh fractures and fracture complications such as nonunion and malunion in the study.

The rate of union at 6 months postsurgery was 95.3%. The high union rate for intramedullary nailing of femoral fractures may be explained by the fact that this method preserves the periosteum which consequently encourages good callus formation. Reaming during the surgery also provides autologous bone graft at the fracture site which serves as osteoinductive and osteogenic agents for callus formation.<sup>[30,31]</sup> Early partial weight bearing in a patient managed with locked intramedullary nailing also stimulates callus formation at the fracture site.<sup>[32]</sup> The studies done by Deepak *et al.* on closed, locked intramedullary nailing of femoral shaft fractures and Naeem-Ur-Razaq *et al.* on open locked intramedullary nailing of femoral shaft fractures, had shown that the two methods give similar results in terms of union rate.<sup>[13,25]</sup> In addition, open locked intramedullary nailing as used in this study does not require an image intensifier or fracture table. These advantages have encouraged the use of this method in developing countries such as Nigeria and other countries in the West African subregion.

Five patients (11.6%) had postoperative complications [Table 4]. Nail breakage occurred in two patients (4.7%), one of them was a man who had AO/OTA type C3 fracture of the femoral shaft. The other patient was a female who had AO/OTA type C2 fracture of the femoral shaft. They both started unprotected ambulation before being instructed to do so. Their intramedullary nails broke at the level of the initial fracture. Both of them had exchange nailing, and their fractures united without incidence.

Superficial surgical site infection was noticed in one patient (2.3%), on the 6<sup>th</sup> day postsurgery, with *Staphylococcus aureus* isolated from the wound. The infection was treated with wound dressing and appropriate antibiotics. The infection rate of 2.3% in this study is within the range of infection rate (0%–4%) reported in studies done by Sadic *et al.* and Sekimpi *et al.*<sup>[12,15]</sup>

One patient (2.3%) had shortening of about 3 cm. The patient had AO/OTA type C3 of the femoral shaft fracture. The shortening was managed with a shoe raise.

Loosening of distal screws was seen in one patient (2.3%). Loosening of the distal screws may have been due to over drilling of the cortex while attempting to place the locking screw. This may occur in open locked intramedullary nailing where there is no image intensifier to guide the locking of the screw. In spite of this, the patient's fracture healed within the study period.

All the patients had range of knee motion from 0° to at least 120° by 6 months after surgery. Early commencement of physiotherapy postoperatively helps to stretch and strengthen the quadriceps muscles and prevent knee stiffness.

Locked intramedullary nailing for femoral fractures characteristically produces excellent functional outcomes when assessed with the Thoresen's criteria. Nearly 93% of the patients had an excellent functional outcome in this study. This is comparable to results from Arpacioğlu *et al.* and Youssef *et al.*, who had excellent or good results in 86.3% and 92.85% of femoral fractures managed in their respective reports.<sup>[33,34]</sup>

## CONCLUSION

Femoral shaft fractures in this environment commonly occur following road traffic crashes with most patients being young male adults. Locked intramedullary nailing of adult femoral shaft fractures by the open method gives good clinical and radiological outcomes. Compliance of patients with instructions given to them after surgery is important so as to prevent some of the avoidable complications. Detailed instructions should thus be provided to patients along with close follow up to ensure good results. Further randomized studies to directly compare open and closed locked intramedullary nailing will add to the knowledge base and improve practice for better patient outcomes.

## Financial support and sponsorship

Nil.

## Conflicts of interest

There are no conflicts of interest.

## REFERENCES

1. Agaja SB, Ehalaiye BF. Patterns of fracture and dislocation injuries at ECWA hospital, Egbe. Kogi State, Nigeria. *Niger J Orthop Trauma* 2005;4:46-54.
2. Enwelu GO, Giwa SO, Obalum DC. Pattern of extremity injuries in polytrauma in Lagos, Nigeria. *Niger Postgrad Med J* 2008;15:6-9.
3. Owoola AM, Thanni LO. Epidemiology and outcome of limb fractures in Nigeria: A Hospital based study. *Niger J Orthop*

- Trauma 2012;11:97-101.
4. Akinyoola L, Orekha O, Odunsi A. Open intramedullary nailing of neglected femoral shaft fractures: Indications and outcome. *Acta Orthop Belg* 2011;77:73-7.
  5. Kaim Khani GM, Humail M, Anjum P, Solangi P, Afridi HD. Is open diaphyseal femur fracture managed by delayed interlocking intramedullary nail a prudent choice? *Pak J Med Sci* 2011;27:541-4.
  6. Turner CH. Bone strength: Current concepts. *Ann N Y Acad Sci* 2006;1068:429-46.
  7. Lee C, Porter KM. Prehospital management of lower limb fractures. *Emerg Med J* 2005;22:660-3.
  8. Bezabeh B, Wamisho BL, Coles MJ. Treatment of adult femoral shaft fractures using the Perkins traction at addis Ababa Tikur Anbessa University Hospital: The Ethiopian experience. *Int Surg* 2012;97:78-85.
  9. Doorgakant A, Mkwandire NC. The management of isolated closed femoral shaft fractures in a district hospital in Malawi. *Trop Doct* 2012;42:8-12.
  10. Wild M, Gehrman S, Jungbluth P, Hakimi M, Thelen S, Betsch M, *et al.* Treatment strategies for intramedullary nailing of femoral shaft fractures. *Orthopedics* 2010;33:726.
  11. Ricci WM, Gallagher B, Haidukewych GJ. Intramedullary nailing of femoral shaft fractures: Current concepts. *J Am Acad Orthop Surg* 2009;17:296-305.
  12. Sadic S, Custovic S, Smajic N, Fazlic M, Vujadinovic A, Hrustic A, *et al.* Complications and functional recovery in treatment of femoral shaft fractures with unreamed intramedullary nailing. *Med Arch* 2014;68:30-3.
  13. Deepak MK, Jain K, Rajamanya KA, Gandhi PR, Rupakumar CS, Ravishankar R. Functional outcome of diaphyseal fractures of femur managed by closed intramedullary interlocking nailing in adults. *Ann Afr Med* 2012;11:52-7.
  14. Ikpeme I, Ngim N, Udosen A, Onuba O, Enembe O, Bello S. External jig-aided intramedullary interlocking nailing of diaphyseal fractures: Experience from a tropical developing centre. *Int Orthop* 2011;35:107-11.
  15. Sekimpi P, Okike K, Zirkle L, Jawa A. Femoral fracture fixation in developing countries: An evaluation of the Surgical Implant Generation Network (SIGN) intramedullary nail. *J Bone Joint Surg Am* 2011;93:1811-8.
  16. Dim EM, Ugwoegbulem OA, Ugbeye ME. Adult traumatic femoral shaft fractures: A review of the literature. *Ibom Med J* 2012;5:26-38.
  17. Ikem IC, Ogunlusi JD, Ine HR. Achieving interlocking nails without using an image intensifier. *Int Orthop* 2007;31:487-90.
  18. Agaja SB. Road traffic injuries in Nigeria: A serious cause for concern. *Niger Clin Rev* 2005;9:33-42.
  19. Ogazi C, Edison E. The drink driving situation in Nigeria. *Traffic Inj Prev* 2012;13:115-9.
  20. Kehinde OS, Olusegun FF. Taking alcohol by deception II: Paraga (alcoholic herbal mixture) use among commercial motor drivers in a South-Western Nigerian city. *BMC Res Notes* 2012;5:301.
  21. Okafor Ifeoma P, Odeyemi Kofoworola A, Dolapo Duro C. Knowledge of commercial bus drivers about road safety measures in Lagos, Nigeria. *Ann Afr Med* 2013;12:34-9.
  22. Iribhogbe PE, Odai ED. Driver-related risk factors in commercial motorcycle (okada) crashes in Benin City, Nigeria. *Prehosp Disaster Med* 2009;24:356-9.
  23. Adogu PO, Ilika AL, Asuzu AL. Predictors of road traffic accident, road traffic injury and death among commercial motorcyclists in an urban area of Nigeria. *Niger J Med* 2009;18:393-7.
  24. Oluwadiya KS, Kolawole IK, Adegbehingbe OO, Olasinde AA, Agodirin O, Uwaezuoke SC. Motorcycle crash characteristics in Nigeria: Implication for control. *Accid Anal Prev* 2009;41:294-8.
  25. Naeem-Ur-Razaq M, Qasim M, Khan MA, Sahibzada AS, Sultan S. Management outcome of closed femoral shaft fractures by open Surgical Implant Generation Network (SIGN) interlocking nails. *J Ayub Med Coll Abbottabad* 2009;21:21-4.
  26. Admaise D, Tekle Y, Wamisho BL. Radiologic and clinical details of major adult limb fractures in a Teaching Hospital AAU, Ethiopia. *Ethiop East Cent Afr J Surg* 2009;14:88-97.
  27. Olasinde AA, Oluwadiya KS, Olakulehin OA, Adetan O. Locked intramedullary nailing of femur and tibia in a semi urban area. *Niger J Orthop Trauma* 2011;10:89-91.
  28. Ertürer E, Öztürk I, Dirik Y, Uzun M, Aksoy B. Radiographic and functional results of osteosynthesis with locked unreamed intramedullary nailing of femoral shaft fractures in adults. *Acta Orthop Traumatol Turc* 2005;39:381-6.
  29. Soren OO. Outcome of Surgical Implant Generation Network nail initiative in treatment of long bone shaft fracture in Kenya. *East Afr Orthop J* 2009;3:8-14.
  30. Wu CC. Exchange nailing for aseptic nonunion of femoral shaft: A retrospective cohort study for effect of reaming size. *J Trauma* 2007;63:859-65.
  31. Giannoudis PV, Pountos I, Morley J, Perry S, Tarkin HI, Pape HC. Growth factor release following femoral nailing. *Bone* 2008;42:751-7.
  32. Taitsman LA, Lynch JR, Agel J, Barei DP, Nork SE. Risk factors for femoral nonunion after femoral shaft fracture. *J Trauma* 2009;67:1389-92.
  33. Arpacioğlu MO, Akmaz I, Mahirogullari M, Kiral A, Rodop O. Treatment of femoral shaft fractures by interlocking intramedullary nailing in adults. *Acta Orthop Traumatol Turc* 2003;37:203-12.
  34. Youssef S, El-Menawy M, Yahia M. Evaluation of static locked intramedullary nailing for treatment of comminuted femoral shaft fractures. *Egypt Orthop J* 2014;49:101-7.