

Sickle Cell Disease with Hearing Defect and Retinitis Pigmentosa

Stanley Bulus Sano¹

¹Department of Ophthalmology, Barau Dikko Teaching Hospital, Kaduna State University, Kaduna, Nigeria

Abstract

A middle-aged homemaker, known sickle cell anaemia patient presented with complaints of reduced vision and night blindness since childhood along with recent-onset hearing impairment in both ears. Anterior segment findings revealed lens opacities more in the left eye, whereas fundus findings showed widespread bone spicule pigmentation in both eyes. Pure-tone audiometry indicated bilateral sensorineural hearing loss. With improvement in visual acuity after refraction, the corrective spectacle was prescribed along with a hearing aid. She presently maintains a follow-up appointment with the sickle cell, ophthalmology, and ear, nose, and throat clinics for a routine checkup. She has improved in her general health and has been crisis-free since the presentation.

Keywords: Bone spicule pigmentation, night blindness, retinitis pigmentosa, sensorineural deafness, sickle cell anaemia

INTRODUCTION

Sickle cell anaemia (SCA) results from homozygosity for the beta-globin S (Hbs) gene mutation which is common in sub-Saharan Africa and affects up to 3% of births in some parts of the continent.^[1] Nearly 90% of the world's SCA patients live in Nigeria, India, and the Democratic Republic of Congo.^[2] In Nigeria, it affects 1%–3% of adults, whereas 25% have the sickle cell trait.^[3] Different haemoglobinopathies have been identified but HbS is the most common in Nigeria and is the result of the substitution of a single amino acid in position 6 of the beta chain of haemoglobin. Microvascular occlusion resulting from sickling within the lumen of smaller vessels causes acute and chronic tissue anaemia and infarction leading to multisystem effects such as painful crisis and other crisis seen in SCA.^[3]

Trapping of sickled red cells in the small blood vessels in various structures of the eye both in anterior and posterior segments leads to characteristic damage. Clinical manifestation varies depending on the presence or absence of vasoproliferative changes. Hence, its classification is proliferative or nonproliferative.^[4-6]

SCA crisis also results in stasis of the labyrinthine artery that supplies the inner ear, hypoxia of the organ of Corti and the stria vascularis within the cochlea, and the death of

outer hair cells, which are crucial for sound amplification. As a result, the inner ear is permanently harmed, and hearing is lost.^[7,8]

Retinitis pigmentosa (RP) defines a group of diffused retinal dystrophies initially predominantly affecting the rod photoreceptor cells with subsequent degeneration of cones with a worldwide prevalence of 1:5000.^[9] The disease is associated with reduced vision, night blindness, visual field loss, reduction or loss of electroretinogram, and pigmentary changes of the retina. The disease has an atypical and a typical variant which is the most common in Nigeria.^[10] An estimated 10%–30% of patients with retinitis RP also have some form of hearing impairment^[11]. Sickle cell disease-related hearing loss can be rapid or gradual in onset, unilateral or bilateral, moderate or severe, and temporary or permanent. RP and hearing loss may occur as a syndrome such as Usher's syndrome or as separate entities. Occurrence of SCA and RP is rare but has been reported.^[12]

Address for correspondence: Dr. Stanley Bulus Sano, Department of Ophthalmology, Barau Dikko Teaching Hospital, Kaduna State University, Kaduna, Nasarawa, Nigeria.
E-mail: stanley.bulus@kasu.edu.ng

This is an open access journal, and articles are distributed under the terms of the Creative Commons Attribution-NonCommercial-ShareAlike 4.0 License, which allows others to remix, tweak, and build upon the work non-commercially, as long as appropriate credit is given and the new creations are licensed under the identical terms.

For reprints contact: WKHLRPMedknow_reprints@wolterskluwer.com

How to cite this article: Sano SB. Sickle cell disease with hearing defect and retinitis pigmentosa. *Niger J Med* 2022;31:708-10.

Submitted: 06-Oct-2022

Accepted: 21-Oct-2022

Published: 28-Feb-2023

Access this article online

Quick Response Code:



Website:
www.njmonline.org

DOI:
10.4103/NJM.NJM_103_22

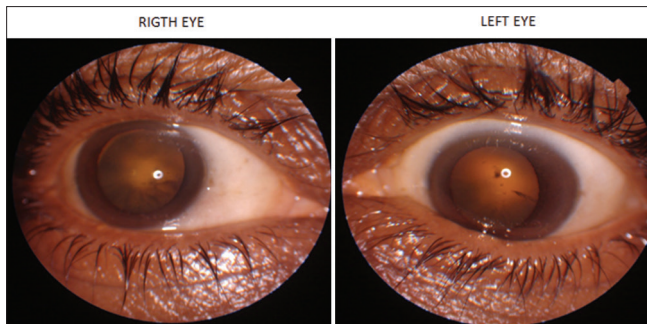


Figure 1: Right and left eyes of patient with early cortical opacity

We report this case of a homemaker with SCA complicated by hearing impairment associated with reduced vision and night blindness from RP.

CASE REPORT

A 60-year-old homemaker known SCA patient presented with progressive, painless deterioration in vision and night blindness since childhood to the outpatient unit of Barau Dikko Teaching Hospital Eye clinic on January 24, 2022. She had also noticed a progressive reduction in hearing two years before the presentation. She married 45 years ago at the age of 15 years in a monogamous nonconsanguineous marriage and a product of a nonconsanguineous union. Nonamong her siblings or parents have RP or SCA suggesting a likelihood of an autosomal recessive mode of inheritance of RP.

She had an unaided visual acuity of 6/24 and 3/60 with a best-corrected visual acuity of 6/12 and 6/60 in right and left eye, respectively. There was icterus with intraocular pressure of 14 mmHg in both eyes with quiet adnexa and anterior segment except for cortical spokes and posterior subcapsular lens opacities more in left eye as seen in [Figure 1]. Fundus examination revealed extensive bone spicule pigmentation with arteriolar attenuation and normal disc as in [Figure 2]. Posterior segment findings associated with sickle cell retinopathy were absent. A Humphrey visual field assessment revealed a borderline field defect in the right eye but a severe field defect in the left eye. Electroretinography could not be done due to the unavailability of the equipment. Ear, nose, and throat (ENT) review revealed clear auditory meatuses and intact tympanic membranes bilaterally. Pure-tone audiometry showed moderate sensorineural hearing loss at high frequencies and tympanometry was normal in both ears.

She was clinically stable with mild pallor and pitting ankle edema but no hepatomegaly or splenomegaly. A blood film smear showed poikilocytosis, anisocytosis, and hypochromic macrocytic red blood cells with polychromasia, whereas haemoglobin electrophoresis revealed a sickle band.

A diagnosis of SCA with RP complicated by hearing loss was made. She was given the best-corrected spectacles along with a hearing aid while maintaining a follow-up with the sickle

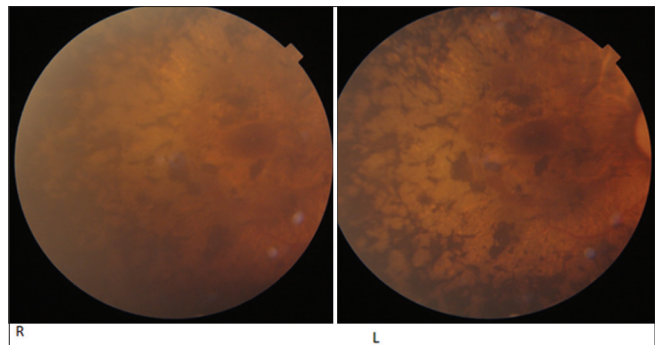


Figure 2: Right and left fundi showing bone spicule pigmentation

cell, clinic ENT, and ophthalmology and has been stable since the presentation.

DISCUSSION

This case report highlights the challenges of an SCA patient whose condition is complicated by hearing impairment and progressive deterioration in vision and night blindness from RP.

The greatest burden of SCA is in sub-Saharan Africa and India where access to medical and public health strategies are limited.^[13-15]

Deafness is a known complication of SCA across all ages, in a study among Nigerian adults aged 15–56 years of age with SCA, the prevalence of sensorineural hearing loss was found to be 66% and more common with HbSC than HbSS patients and more likely in those with preexisting inner, middle or external ear pathology.^[11] Hearing loss reported in this study was of gradual onset unlike in other studies where it was of sudden onset.^[7,8] Gradual loss of hearing may be explained by her relatively stable condition of SCA compared to those of typical SCA patients in developing countries.

RP in this patient was an incidental finding. Its effect on vision in SCA patients may be confused with or may worsen sickle cell retinopathy. Surprisingly, our patient maintained good vision despite the widespread bone spicule pigmentation except in the left eye (LE) where she had more pronounced posterior subcapsular lens opacities. RP with SCA is rare but has been reported along with dextrocardia and situs inversus syndrome in two young males in India.^[11]

CONCLUSION

SCA patients may also present with other medical conditions that require intervention for their overall well-being. Meticulous assessment of such patients will unravel other medical conditions and collaborative management is important for the holistic care of such patients.

Declaration of patient consent

The authors certify that they have obtained all appropriate patient consent forms. In the form, the patient(s) has/have given his/her/their consent for his/her/their images and other

clinical information to be reported in the journal. The patients understand that their names and initials will not be published and due efforts will be made to conceal their identity, but anonymity cannot be guaranteed.

Financial support and sponsorship

Nil.

Conflicts of interest

There are no conflicts of interest.

REFERENCES

1. Grosse SD, Odame I, Atrash HK, Amendah DD, Piel FB, Williams TN. Sick cell disease in Africa: A neglected cause of early childhood mortality. *Am J Prev Med* 2011;41:S398-405.
2. Piel FB, Hay SI, Gupta S, Weatherall DJ, Williams TN. Global burden of sickle cell anaemia in children under five, 2010-2050: Modelling based on demographics, excess mortality, and interventions. *PLoS Med* 2013;10:e1001484.
3. Emechebe GO, Onyire NB, Orji ML, Achigbu KI. Sick cell disease in Nigeria: A review. *IOSR J Dent Med Sci* 2017;16:87-94.
4. Emerson GG, Luty GA. Effects of sickle cell disease on the eye: Clinical features and treatment. *Hematol Oncol Clin North Am* 2005;19:957-73, ix.
5. Jampol LM, Condon P, Dizon-Moore R, Serjeant G, Schulman JA. Salmon-patch hemorrhages after central retinal artery occlusion in sickle cell disease. *Arch Ophthalmol* 1981;99:237-40.
6. Friberg TR, Young CM, Milner PF. Incidence of ocular abnormalities in patients with sickle hemoglobinopathies. *Ann Ophthalmol* 1986;18:150-3.
7. Kiser ZM, Clark KA, Sumner JL, Vercellotti GM, Nelson MD. Association between sensorineural hearing loss and homozygous sickle cell anemia: A meta-analysis. *Blood* 2019;134:3453.
8. Ogawa K, Kanzaki J. Aplastic anemia and sudden sensorineural hearing loss. *Acta Otolaryngol Suppl* 1994;514:85-8.
9. Kanski JJ. *Clinical Ophthalmology: A Systemic Approach*. 6th ed. UK: Butterworth Heinemann, Elsevier; 2007. p. 663.
10. Jurkles B, Zrenner E, Wessing A. Retinitis pigmentosa – Clinical, genetic and pathophysiologic aspects. *Klin Monbl Augenheilkd* 1997;210:1-18.
11. Bayazit YA, Yilmaz M. An overview of hereditary hearing loss. *ORL J Otorhinolaryngol Relat Spec* 2006;68:57-63.
12. Madhavan C, Bhende P, Gopal L, Vasanthi SB, Kumaramanickavel G. Retinitis pigmentosa patients with sickle cell disease and dextrocardia and situs inversus syndrome. *Indian J Ophthalmol* 2001;49:193-5.
13. Diallo D, Tcherna G. Sick cell disease in Africa. *Curr Opin Hematol* 2002;9:111-6.
14. Odame I. Perspective: We need a global solution. *Nature* 2014;515:S10.
15. Tshilolo L, Kafando E, Sawadogo M, Cotton F, Vertongen F, Ferster A, *et al*. Neonatal screening and clinical care programmes for sickle cell disorders in sub-Saharan Africa: Lessons from pilot studies. *Public Health* 2008;122:933-41.