

Case Report

Unusual Intravesical Foreign Body Following Perineo-vesical Injury

Ekene Victor Ezenwa, Emmanuel O Osaigbovon, Ofuani IJ

Department of Surgery,
Urology Unit, University of
Benin Teaching Hospital,
Benin City, Nigeria

ABSTRACT

Reports of foreign body in the bladder are rare. Various objects have been retrieved. Diagnosis is mainly by history of lower urinary tract symptoms and low abdominal pain combined with relevant radiological investigations. Treatment depends on the size, nature, and configuration of the object. The approach may be endoscopic or through open surgery depending on the above highlighted factors.

KEYWORDS: Foreign body, hematuria, intravesical, wood

INTRODUCTION

The bladder is the reservoir of urine. Because of its capacious nature and extension to the exterior through the urethra, other occupants apart from urine have been reported.^[1] These foreign bodies find their way into the bladder for different reasons. These reasons range from sexual, psychological, iatrogenic to external trauma as in the index case.

Reports of foreign body in the bladder is not very common^[2], hence the need to discuss this case of unusual intravesical finding following trauma.

CASE REPORT

This is a case report of Mr. E B a 20-year-old unemployed secondary school graduate who was seen at the accident and emergency unit of our center. He resides in Delta state which is located in the Niger Delta region of Nigeria, a riverine area. He presented with lower abdominal pain of a year duration, difficulty with micturition of 8 months duration, recurrent episodes of hematuria of 6 months and epigastric pain of 2 months.

His problem dates back to 18 months ago when he sustained a deep penetrating injury to the perineum while defecating into a river. He fell while squatting on wooden pegs inserted into the water body specifically for open defecation. He fell on the pole and sustained a deep perineal laceration which was managed conservatively in a peripheral center without exploration or radiological evaluation.

He subsequently started having lower abdominal pain following the injury which intensified a year ago. The pain was at the suprapubic region, insidious in onset, sharp, severe, continuous, radiates to the groin and penile tip, aggravated by urge to micturate and transiently relieved by analgesics.

The difficulty with micturition was characterized by frequency (>10 times daily), nocturia (>10 times per night), urgency, poor stream, intermittence, and strangury.

Hematuria was total, painful, with associated passage of clots, worsened by straining. He has been having an episode almost every month which usually lasts for a week. He also has associated dizziness but no fainting spells. Also noticed was occasional pyuria and passage of particles thought to resemble wood in his urine.

Epigastric pain was of insidious onset, burning, severe, intermittent, radiates to the back, worsened by the ingestion of spicy foods. He has been using nonsteroidal anti-inflammatory drugs (NSAIDs) in large doses on account of the suprapubic pain. He is nauseated, had an episode of hematemesis with hematochezia and passage of melena stool. He also had dizziness but no fainting spell.

Address for correspondence: Dr. Ekene Victor Ezenwa,
Department of Surgery, Urology Unit, University of Benin
Teaching Hospital, Benin City, Nigeria.
E-mail: veze001@yahoo.com

This is an open access journal, and articles are distributed under the terms of the Creative Commons Attribution-NonCommercial-ShareAlike 4.0 License, which allows others to remix, tweak, and build upon the work non-commercially, as long as appropriate credit is given and the new creations are licensed under the identical terms.

For reprints contact: reprints@medknow.com

How to cite this article: Ezenwa EV, Osaigbovon EO, Ofuani IJ. Unusual intravesical foreign body following perineo-vesical injury. Niger J Surg 2018;24:44-7.

Access this article online	
Quick Response Code: 	Website: www.nigerianjsurg.com
	DOI: 10.4103/njs.NJS_2_17

He has been managed in several private hospitals without improvement before presentation at the general outpatient clinic of the centre from where he was referred to urology unit. He initially did not honor the referral due to financial constraint. However, he finally presented at accident and Emergency section of our center with the above symptom. At presentation, an abdominopelvic ultrasound sound scan done as part of the evaluation in the unit revealed a contracted urinary bladder with mixed echogenic materials within its lumen. There were linear echogenic areas in the peripheral aspects of the bladders, some casting acoustic shadows. The impression was contracted urinary bladder with possible bladder wall calcification and mixed echogenic intra-luminal contents.

The linear objects within the bladder were replicated in an abdominal X ray also done for the same purpose [Figure 1].

He does not have any comorbid pathology. He is the second child in a family of four siblings in a polygamous setting. He neither takes alcohol, tobacco, or any other social drug.

General examination revealed a young man that was febrile (37.8), pale, anicteric, well hydrated, and with no pedal edema.

The abdomen was full, moves with respiration, there was epigastric, suprapubic, and renal angle tenderness, but no guarding nor rebound tenderness. The liver and spleen were not palpable, kidneys were not ballotable and bladder not distended. Bowel sound was present and normoactive. There were no ascites.

Rectal examination revealed a linear scar extending from the perineum to the anal verge. The peri-anal hygiene and anal sphincteric tone were good, rectum was empty, and prostate gland was not enlarged, gloved finger was stained with normal feces. The chest, cardiovascular and musculoskeletal system, and external genitalia were all normal. A diagnosis

of urosepsis with a foreign body in the bladder and acute gastric erosion from NSAID abuse were made.

The following investigations were requested Electrolyte/urea/creatinine (E, U, Cr), full blood count, blood culture, urinalysis, urine m/c/s. He was started on intravenous fluid, urethral catheter was placed which drained about 300 ml of blood stained urine and subsequently, he had the following medications: intravenous ceftriaxone/sulbactam and omeprazole.

The E, U, Cr was normal, the FBC was normal except for the packed cell volume which was 20% for which he received 4 units of blood. The result of the urinalysis was suggestive of infection (protein+++ , leukocytes+++ , blood+++ and nitrite+). The urine microscopy culture and sensitivity revealed: Numerous pus and red blood cells, the growth of *Escherichia coli* sensitive to furantoin but resistant to other tested antibiotics.

The posttransfusion packed cell volume was 30% and he was then scheduled for cystoscopy and extraction of foreign body in the bladder.

Findings at cystoscopy were two foreign bodies (wood) in the bladder measuring 9 cm × 2 cm and 3 cm × 1.5 cm, not adherent to the bladder wall, hyperaemic bladder wall with normal ureteric orifices. Due to the size of the foreign body, decision for open surgery was taken during which similar findings were made in addition to thickened bladder wall.

Due to the size and nature of the foreign body seen during radiological evaluation and cystoscopy [Figure 2], the object was successfully removed through open approach (open bladder exploration). The bladder was closed over an in situ catheter draining bloody urine. Retro pubic wound drain was also placed.

The procedure was well tolerated and immediate postoperative state was good. He had an uneventful postoperative care and was discharged home on the 8th day postoperative. His postoperative visits at the outpatient clinic of the hospital have remained uneventful for 6 months now.

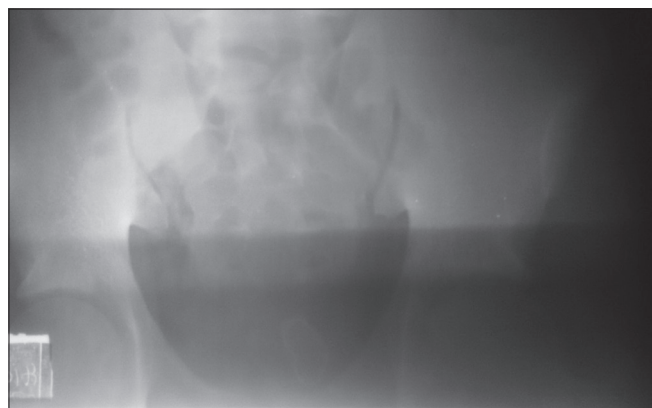


Figure 1: Plain abdominal X-ray showing foreign body in the bladder

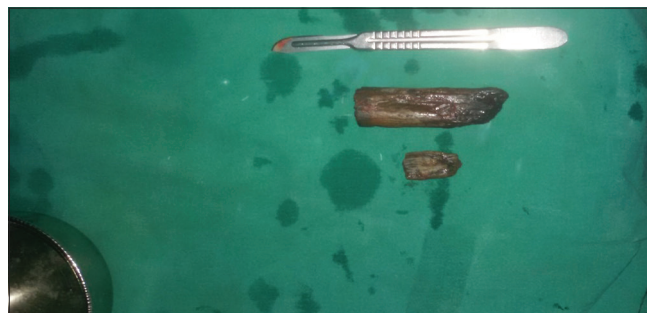

Figure 2: Retrieved foreign body

DISCUSSION

Exploring the bladder for the foreign body has always been an exciting venture, due to the varied nature of objects usually retrieved. The objects documented to have been retrieved from the bladder include paraffin (candlestick), urethral device, metallic cables, metallic flashlight cover, plastic tubes, fish, and snake.^[3,4]

The reason why a foreign body may get to the bladder ranges from psychological issues, during invasive urological procedure (iatrogenic), trauma (as in the index case) to migration from other organs (intra-uterine contraceptive device).^[3,5]

Psychologically, various circumstances including exotic impulse, mental illness, borderline personality disorder, sexual curiosity, sexual practice while intoxicated may be the reason for self-insertion of foreign bodies in lower urinary tract.^[3,5] Among these, the most common motive for foreign body insertion in the lower urinary tract is sexual or erotic in nature, such as masturbation or other forms of sexual variation or gratification.^[3,5]

The peculiarity of the index case lies in the nature and size of the foreign body involved (chunks of wood). The mechanism of the injury is also very peculiar as it highlights the socioeconomic component that predisposed the patient to such trauma. Open water body defecation is a public health issue not only because of the gastrointestinal pathogens that can be disseminated through the act but also for the injury that one can acquire when perpetrating such an act as exemplified by the index case. A penetrating perineal trauma the also involved the bladder leaving a large foreign body behind.

The delay in the diagnosis and also in seeking medical care in the index case is also a cause of concern, this can be attributed to low-quality health care sought initially by the patient and also the financial difficulty the patient had which made him not to seek for urology care even when eventually advised.

Reports^[6] of missed foreign body in the bladder is very rare in literature, this has occurred even following exploration for a concomitant abdominal trauma. A high index of suspicion for this pathology should always be entertained whenever an individual presents with perineo-vesical injury. Careful history taking and physical examination backed by pelvic radiological investigations to determine the exact size, number, and location of the foreign body is necessary.^[7] The radiological investigations important in this context

include pelvic ultrasound and plain abdominopelvic X-ray. Both of these investigations were useful in the index case. Computed tomography may be indicated if the initial evaluation by above modalities are not satisfactory.^[5]

The technique for the removal of intravesical foreign body ranges from minimally invasive procedures such as endoscopic management to open surgery. The option to be used depends on the size nature and configuration of the material.^[8] The endoscopic approach reduces the morbidity associated with the open approach while allowing for early discharge.^[1,3,8] The open approach is usually indicated when the object is large and of the configuration such that it cannot pass through the sheath of the scope and is not of the material that can be easily fragmented.^[4] This was the approach adopted for our patient where the pieces of wood encountered were large and could not be easily fragmented without prolonging the surgery time at the detriment of the patient.

Early removal of foreign bodies in the bladder is important as complications such as infection, hematuria, stones or fistula formation can occur when they are neglected.^[4] In the case presented hematuria and sepsis were the complications recorded which were both successfully managed. It is important to note that mortality has been recorded from sepsis resulting from intravesical foreign body.^[9]

This case tries to highlight the need for proper evaluation of patients with penetrating perineal trauma even in a low resource country like Nigeria. Simple radiological investigations such as ultrasound and X-ray would have detected the foreign body in the index case much earlier. The consequence of improper human waste disposal and late presentation due to economic reasons in a low resource economy is also highlighted. The fact that an unusual vesical object (large chunks of wood) was retrieved from the bladder is also of note.

CONCLUSION

Intravesical foreign body is an uncommon occurrence. Comprehensive evaluation of patients with penetrating perineal trauma using radiological modalities should always be undertaken as there may be an associated vesical injury with concomitant retention of fragments of the penetrating material.

Declaration of patient consent

The authors certify that they have obtained all appropriate patient consent forms. In the form the patient(s) has/have given his/her/their consent for his/her/their images and

other clinical information to be reported in the journal. The patients understand that their names and initials will not be published and due efforts will be made to conceal their identity, but anonymity cannot be guaranteed.

Financial support and sponsorship

Nil.

Conflicts of interest

There are no conflicts of interest.

REFERENCES

1. Irekpita E, Imomoh P, Kesieme E, Onuora V. Intravesical foreign bodies: a case report and a review of the literature. *International Medical Case Reports Journal*. 2011;4:35-39. doi:10.2147/IMCRJ.S18857.
2. Jung U.S, Lee J.H, Kyung M.S. Laparoscopic removal of an intravesical foreign body after laparoscopically assisted vaginal hysterectomy, a case report and review of the literature. *Surg Laparosc Endosc Percutan Tech*. 2008;18:420-427.
3. Cho DS, Kim SJ, Choi JB. Foreign bodies in urethra and bladder by implements used during sex behavior. *Korean J Urol* 2003;44:1131-4.
4. Oguntayo OA, Zayyan M, Odogwu K. Foreign body (metallic flashlight cover) in the urinary bladder mimicking advanced cancer of the cervix: Case report and review of the literature. *Afr J Urol* 2009;15:111.
5. Rahman NU, Elliott SP, McAninch JW. Self-inflicted male urethral foreign body insertion: Endoscopic management and complications. *BJU Int* 2004;94:1051-3.
6. Kashif B, Asaf A, Khursheed A. An unusual and missed foreign body in the urinary bladder. *J Pioneer Med Sci* 2013;4:10-2.
7. Johnin K, Kushima M, Koizumi S, Okada Y. Percutaneous transvesical retrieval of foreign bodies penetrating the urethra. *J Urol* 1999;161:915-6.
8. Rafique M. Intravesical foreign bodies: Review and current management strategies. *Urol J* 2008;5:223-31.
9. Sunwoo HS, Kwon CH, Kim YS, Chung KS, Kim JC. Five cases of foreign bodies in the bladder. *Korean J Urol* 1980;21:82-5.

