

The accuracy of 2D ultrasound prenatal sex determination

Blessing Ose-Emenim Igbinedion, Theophilus Oriazo Akhigbe¹

Department of Radiology, University of Benin, Benin, ¹Irrua Specialist Teaching Hospital, Irrua, Edo, Nigeria

ABSTRACT

Background: Pregnant women have been curious about the sex of their unborn child. The advent of ultrasound, its application into medicine, and the revolutionary changes in its resolution and function has led to the ability to assign a sex to these unborn children, thereby allaying the anxiety of these women but with consequent emergent ethical, moral, psycho-social, and medico-legal issues. The objectives were to determine the accuracy of sonographic prenatal sex determination, perform binary classification test, and the impact it has, including mis-diagnosis. **Materials and Methods:** A prospective prenatal sonographic sex determination study on 205 consecutive consenting pregnant women aged 20-40 years in a private hospital in Benin between August 2010 and October 2011. Questionnaires were administered to these women before and after the scan and the women were told the sex of the fetuses and their feelings on the determined sex recorded. The sex at birth was confirmed and compared to the scan determined gender by their case note and telephone. Relevant discussions during the scan and later on were recorded on the questionnaires. The statistical package used was SPSS version 17 and binary classification tests were performed. **Results:** The sensitivity (98.2%) and binary classification components values of prenatal sex determination were high with the sensitivity of detecting a female higher than that of males. Two males were misdiagnosed as females. Most of the women were happy even when the sex differed from that which they desired. **Conclusion:** Prenatal sonographic sex determination has a high sensitivity index. Consequently we advocate its use prior to more invasive sex tests.

Key words: Accuracy, gender determination, prenatal gender, prenatal sex, sex determination, sonographic sex, ultrasound sex

Address for correspondence:

Dr. Blessing Ose-Emenim Igbinedion,
Department of Radiology,
University of Benin, Benin,
Edo, Nigeria.
E-mail: igbins2@yahoo.com

INTRODUCTION

Ultrasound is used in most parts of the world for prenatal sex determination. Indication for prenatal sex determination can be medical or nonmedical. The medical indication for its use include in families at risk of x-linked disorders, testicular feminization syndrome, pseudo-hermaphroditism, genital anomalies, ambiguous genitalia, and determination of zygosity in multiple pregnancy.¹⁻⁵ In families predisposed to x-linked disorders it leads to the reduction in invasive procedures as sonographic prenatal determined females would not require further invasive genetic screening. The nonmedical reasons given by women for sonographic sex determination include preparturition

shopping, curiosity, husband/relatives' request, and to confirm suspicion.⁴

First trimester sonographic prenatal sex determination can be done from 11 weeks gestation using the direction of the genital tubercle and the "sagittal sign." The downward direction of the tubercle is considered a female while the upward direction a male.^{1,2} In sagittal sign, examination of the genital region in the midline sagittal plane demonstrates a caudal notch in females and a cranial notch in males.^{6,7} Ultrasound scan done in the second and third trimester places emphasis on visualization of the anatomy of the genitals or pelvic structure in determining the fetal sex. In the early publications on sonographic prenatal gender assignment male sex was identified by the presence of the penis and scrotum while females were by the absence of both scrotum and penis.⁸ But with improved modern ultrasound resolution technology visualization of the vulva, clitoris, and labia is considered a female fetus whereas demonstration of the scrotum, penis, descended testicles, and penile midline raphe is assigned to males. Visualization of the internal pelvic structures of the fetus such as the uterus and ovaries also assists in assigning appropriate sex to the fetus.

Access this article online

Quick Response Code:



Website:

www.nigeriamedj.com

DOI:

10.4103/0300-1652.103545

Unfortunately first trimester ultrasound sex determination has significant false negative rate.^{2,9} Studies done in the second trimester have better sensitivity values.⁹ The sensitivity of sonographic determined sex is dependent on the operator, machine, and habitus. Improvement in the sensitivity value increases with high proficiency and experience as well as high-quality machine. Incorrectly determined sex can have some psychological effects on the family.² Hence an attempt must be made to place an accurate sex type on the fetus. Thus we undertook this study to determine the prenatal sonographic accuracy and sensitivity pattern in our environment.

MATERIALS AND METHODS

This is a prospective study conducted at a private hospital in Benin from August 2010 to Oct 2011. Approval for the study was sought and granted from the radiology department and the management (which acts as the ethical board) of the private institution where the study was conducted. In the study 205 consecutive consenting pregnant women with pregnancies in the second or third trimester that were referred for obstetric ultrasound had the procedure explained to them and questionnaires administered after signing the informed consent section. Sonographic prenatal sex determination was conducted in these consenting women and the determined sex communicated to them. They were then asked how they felt about the determined sex and their feelings recorded.

Data such as phone numbers, gestational age at scan time, estimated date of delivery, case note number, and other relevant data were entered into the questionnaires. Their case notes were retrieved about 3 weeks after the expected date of delivery and the sex of the baby at birth entered into their questionnaires. The patients were also contacted by telephone and the sex at birth confirmed with relevant comments entered into the questionnaires. The sex at birth was then compared with the prenatal sonographic determined sex.

The ultrasound machine used was Fukuda Denshi FF Sonic, UF-4100, Tokyo, 2007. The scan was performed by one of the researchers. Identification of the vulva, clitoris, and labia was used to assign female sex to the fetus [Figure 1]. For male fetuses visualization of the scrotum, testicles, and penile shaft was utilized [Figure 2]. After the scan the women were asked how they felt after knowing the fetal sex. Their responses were then entered into the questionnaires. Relevant oral communications were also recorded in the questionnaires as other findings.

The data were analyzed using SPSS version 17. Descriptive analysis was performed on the patients' biodata and gestation of the pregnancies. Binary classification test such as sensitivity, specificity, positive predictive value, negative predictive value, and accuracy were performed for either fetal sex and the results tabulated. A chi-square test was also done with significant value set at 0.05.

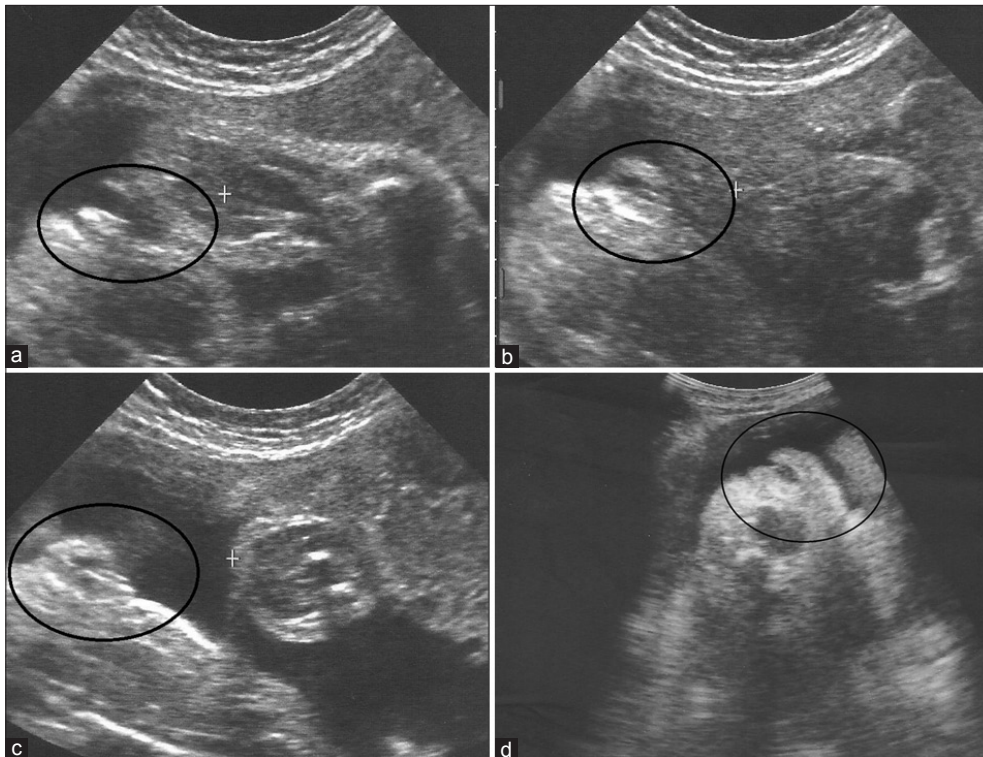


Figure 1: Female genitalia, encircled

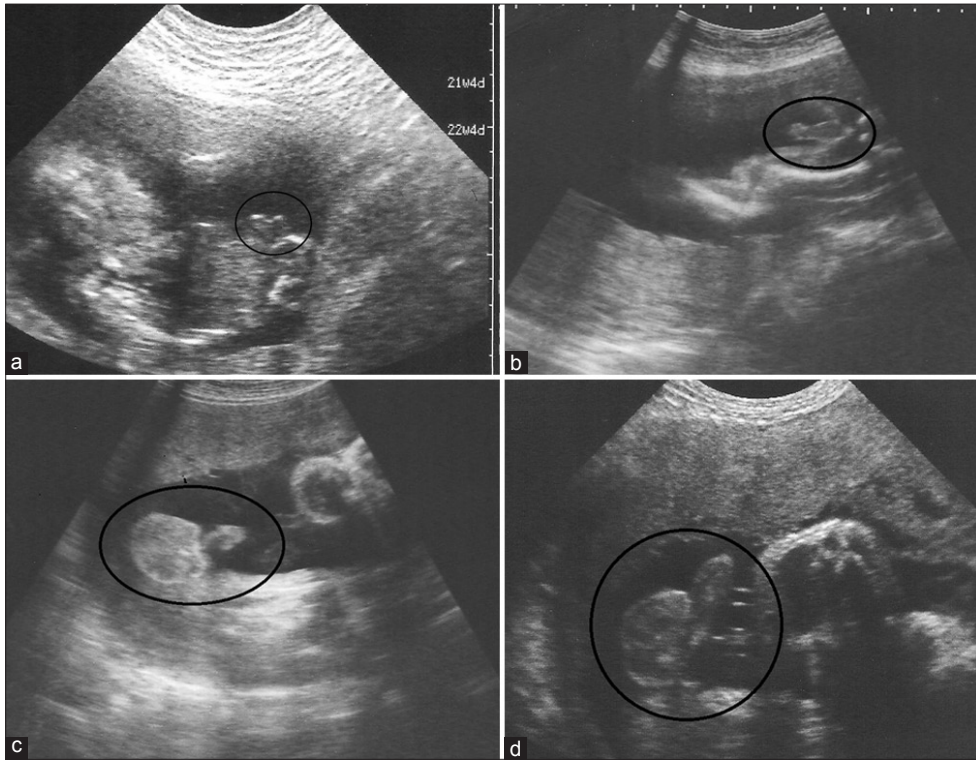


Figure 2: Male fetal external genitalia (circled)

RESULTS

Two hundred and five pregnant women participated in this study with the youngest aged 20 years while the oldest 40 years. The average age of the participants was 29.5 years; median 29 years; and mode 28 years. The mean time at which the scans were conducted was at 29.2 weeks gestation; median, 30 weeks gestation; mode, 35 weeks gestation. The earliest scan was at 17 weeks of gestation while the latest was at 40 weeks with the range spanning 23 weeks [Figure 3].

All the females were accurately detected sonographically as females, but 2 males were mistakenly reported as females [Table 1]. These two males were scanned at 33 and 36 weeks of gestation. The positive predictive value for ultrasound male sex detection is 100% [Table 2]. It thus means that if on ultrasound a male sex is detected, then the probability of being male is 100%. On the other hand if sonographically a female sex is detected, then the probability is 97.9% that it may turn out to be a female at birth. Furthermore, the sensitivity, specificity, and accuracy for either sex are high [Table 2].

After conducting the scans and the clients told what sex of baby they expect, 2 (0.9%) felt resigned; 8 (3.5%) were unhappy; 18 (7.8%) were indifferent; 194 (84.0%) were happy with the ultrasound fetal sex. Nine (3.9%) opted not to fill in their feelings about the outcome of the obstetric sex determination scans. Some of the women who were

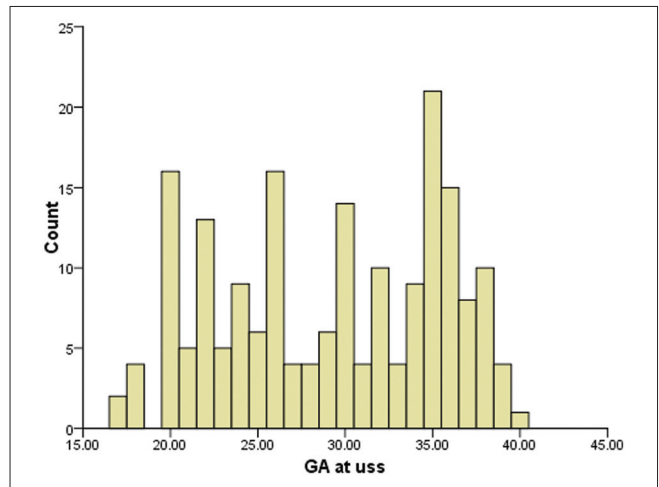


Figure 3: Histogram showing the frequencies and gestational ages at which obstetric scans were done

unhappy or resigned to the sex of the fetus as detected sonographically made comments like: *“It is God’s will, who are we to judge?”*, *“God knows better,”* *“Oh no! I have already bought clothing for the opposite sex,”* and *“I will try again.”* One woman jokingly said, *“Doctor I will give you the child”* – it was to be her fourth male child.

DISCUSSION

In the past women had made guesses of the sex of their unborn child which was confirmed only at parturition.

Table 1: Cross-tabulation of the sex as detected during obstetric scans against the actual sex at birth

USS sex	Sex at birth		Total
	Male	Female	
Male	108 (100)	0 (0)	108 (100)
Female	2 (2.1)	95 (97.9)	97 (100)
Total	110 (53.7)	95 (46.3)	205 (100)

Values are in n (% within USS sex); USS sex — sex detected at ultrasound; $\chi^2 = 197.123, P < 0.001$

Table 2: Binary classification tests for ultrasonic detection of male and females sexes respectively

	Sensitivity	Specificity	PPV	NPV	Accuracy
Males	98.2	100	100	97.9	99.0
Females	100	98.2	97.9	100	99.0

PPV - Positive predictive value; NPV - Negative predictive value; Figures are in percentage

The advent of ultrasound has allowed conduction of sex determination *in utero* with consequent anxiety alleviation associated with curiosity over the fetal sex experienced in the past. In medically indicated fetal sex determination to determine if the fetus is a male in x-linked disorder, 100% accuracy is desired. For instance a medicolegal case may arise if a female fetus is mistakenly identified as a male in a family with history of x-linked disorder and the pregnancy is lost Post-amniocentesis. In many studies 100% accuracy in prenatal gender assignment was achieved.^{1,10-12} However lower sensitivities values have been reported with accuracy ranging from 93% to 99% in scans done within the second and third trimesters.¹³⁻¹⁷ Our study recorded a similarly high accuracy of 99% for sonographic prenatal sex determination of fetuses greater than 17-week gestation.

This study demonstrates that ultrasonography is an effective way of identifying fetal gender in the second and third trimester. Out of the 205 pregnant women in this study only 2 had the sex of their babies at birth different from what was determined by ultrasonography. All females were accurately detected sonographically as females but two males were wrongly reported as females yielding 100% sensitivity for females and 98.2% for males. The women whose children's sex were wrongly identified did not fail to vent their anger citing that they had to go through shopping for new set of clothing for the babies leading to wastage of scarce resources and psychological shock at seeing the opposite sex to that expected at parturition. In similar situations hospitals had been sued for false results.⁵ It is possible that these mistakes occurred due to inability to identify the male genitalia with consequent assignment of a female gender instead of ensuring that the female external genitalia (the vulva, clitoris, and labia) is fully visualized, or that folded/coiled umbilical cord which easily mimics scrotum may have been the cause. However coiled umbilical cord can be easily differentiated from scrotal

sac if the gain setting is optimized or reduced if the gain was initially high. Application of Doppler on the suspected umbilical cord may show color flow while no significant flow will be seen if it is the scrotum.

In a study carried by Efrat *et al.*¹ to assess the accuracy of fetal sex determination at 11 to 14 weeks of gestation it was found that the accuracy of sex determination increased with gestational age with the accuracy increasing from 70.3% at 11 weeks gestation; to 98.7% at 12 weeks; and 100% at 13 weeks. Male fetuses were wrongly assigned as females in 56% of cases at 11 weeks gestation; 3% at 12 weeks gestation; and 0% at 13 weeks gestation. In our study the sensitivity at detecting a female fetus was 100% which is higher than that of detecting a male, 98.2%. Efrat *et al.*¹ also recorded similar findings as only 5% of the female fetuses at 11 weeks were incorrectly assigned as males with reduction of the false positive rate to 0% at 12 and 13 weeks. Other studies also support the observation that the sensitivity of female sex determination is higher than male and that gender determination sensitivity increases with advancing fetal age.²

In the ability to assign a male gender we got a reasonably high sensitivity of 98.2% and specificity of 100%. All the female fetuses were accurately assigned as females but the ability to rule out a fetus as not being a female was 98.2% (specificity). We achieved an accuracy of 99.0% which shows that 2D sonographic prenatal sex determination has a high clinical application in assigning gender *in utero*. Wrong gender assignment may occur if the pelvic floor muscles or the anal orifice is mistaken for female genitalia. Sometimes it may be difficult or impossible to visualize the genitalia to assign a sex to the fetus. Factors that may hinder easy visualization of the genitalia include breech presentation, closely apposed fetal thighs resulting in covering of the genitalia, close proximity of the fetal peritoneum to the placenta or myometrial wall, oligohydramnios, maternal obesity, technical problem with the machine or probe causing poor image quality.

Revealing fetal sex during obstetric scans raises numerous psycho-social, ethical, and legal dilemmas.⁵ Especially because of the effect falsely assigned sex will have on the women and their family which can boomerang on the sonologist/sonographer as a legal suit against the hospital. Consequently some sonologists do not perform ultrasound sex determination. Bashour *et al.*¹⁸ proposed that avoidance of incorrect diagnosis was the reason for refusal by some doctors to inform their patients of the fetal sex in Syria.¹⁸ Many of the women in our study were relieved when the fetal sex was told to them. A significant proportion (84.0%) remained happy even when the sex was different from that preferred with the expression that "it is God's will, who are we to judge?" We perceived the expression as a sign of resignation and it was expressed by 2 (0.9%) women. Only 3.5% of the women were unhappy with the

prenatal sex report most likely because it is contrary to the preferred sex.

Application of 3D ultrasound is an effective and fast way of identifying fetal sex in the first trimester using its volume rendering capability and multiplanar reconstruction including the midline sagittal plane which is essential for the “sagittal sign” of gender identification associated with the direction of genital tubercle angulation.^{3,19} In the detection of facial anomaly such as cleft palate and other part of the body’s physical abnormality 3D ultrasound is indispensable especially with its surface rendering mode function. However studies have shown that 3D ultrasound does not confer increased accuracy at gender assignment over 2D.²⁰ Consequently 2D ultrasound remains the gold standard in fetal gender assignment.

CONCLUSION

The sensitivity and binary classification test values are high. Hence we recommend the use of prenatal sonographic sex determination when requested and communication of the report to the women provided it is done by a competent trained health personnel.

REFERENCES

- Efrat Z, Akinfenwa OO, Nicolaides KH. First-trimester determination of fetal gender by ultrasound. *Ultrasound Obstet Gynecol* 1999;13:305-7.
- Pajkrt E, Chitty LS. Prenatal gender determination and the diagnosis of genital anomalies. *BJU Int* 2004;93 Suppl 3:12-9.
- Michaidalidis GD, Papageorgiou P, Morris RW, Economides DL. The use of three-dimensional ultrasound for fetal gender determination in the first trimester. *Br J Radiol* 2003;76:448-51.
- Ekele BA, Maaji SM, Bello SO, Morhason-Bello IO. Profile of women seeking foetal gender at ultrasound in a Nigerian obstetric population. *Ultrasound* 2008;16:199-202.
- Mubuuke AG. An exploratory study of the views of Ugandan women and health practitioners on the use of sonography to establish fetal sex. *Pan Afr Med J* 2011;9:36.
- Emerson DS, Felker RE, Brown DL. The sagittal sign. An early second trimester sonographic indicator of fetal gender. *J Ultrasound Med* 1989;8:293-7.
- Natsuyama E. Sonographic determination of fetal sex from twelve weeks of gestation. *Am J Obstet Gynecol* 1984;149:748-57.
- Stocker J, Evens L. Fetal sex determination by ultrasound. *Obstet Gynecol* 1977;50:462-6.
- Odeh M, Ophir E, Bornstein J. Hypospadias mimicking female genitalia on early second trimester sonographic examination. *J Clin Ultrasound* 2008;36:581-3.
- Hsiao CH, Wang HC, Hsieh CF, Hsu JJ. Fetal gender screening by ultrasound at 11 to 13 (+6) weeks. *Acta Obstet Gynecol Scand* 2008;87:8-13.
- Lev-Toaff AS, Ozhan S, Pretorius D, Bega G, Kurtz AB, Kuhlman K. Three-dimensional multiplanar ultrasound for fetal gender assignment: value of the mid-sagittal plane. *Ultrasound Obstet Gynecol* 2000;16:345-50.
- Scholly TA, Sutphen JH, Hitchcock DA, Mackey SC, Langstaff LM. Sonographic determination of fetal gender. *AJR Am J Roentgenol* 1980;135:1161-5.
- Reece EA, Winn HN, Wan M, Burdine C, Green J, Hobbins JC. Can ultrasonography replace amniocentesis in fetal gender determination during the early second trimester? *Am J Obstet Gynecol* 1987;156:579-81.
- Plattner G, Renner W, Went J, Beaudette L, Viau G. Fetal sex determination by ultrasound scan in the second and third trimesters. *Obstet Gynecol* 1983;61:454-8.
- Dunne MG, Cunat JS. Sonographic determination of fetal gender before 25 weeks gestation. *AJR Am J Roentgenol* 1983;140:741-3.
- Shalev E, Weiner E, Zuckerman H. Ultrasound determination of fetal sex. *Am J Obstet Gynecol* 1981;141:582-3.
- Birnholtz JC. Determination of fetal sex. *N Engl J Med* 1983;309:942-4.
- Bashour H, Hafez R, Abdulsalam A. Syrian women’s perceptions and experiences of ultrasound screening in pregnancy: Implications for antenatal policy. *Reprod Health Matters* 2005;13:147-54.
- Whitlow BJ, Lazanakis MS, Economides DL. The sonographic identification of fetal gender from 11 to 14 weeks of gestation. *Ultrasound Obstet Gynecol* 1999;13:301-4.
- Hackett LK, Tarsa M, Wolfson TJ, Kaplan G, Vaux KK, Pretorius DH. Use of multiplanar 3-dimensional ultrasonography for prenatal sex identification. *J Ultrasound Med* 2010;29:195-202.

How to cite this article: Igbinedion BO, Akhigbe TO. The accuracy of 2D ultrasound prenatal sex determination. *Niger Med J* 2012;53:71-5.
Source of Support: Nil, **Conflict of Interest:** None declared.

Staying in touch with the journal

1) Table of Contents (TOC) email alert

Receive an email alert containing the TOC when a new complete issue of the journal is made available online. To register for TOC alerts go to www.nigeriamedj.com/signup.asp.

2) RSS feeds

Really Simple Syndication (RSS) helps you to get alerts on new publication right on your desktop without going to the journal’s website. You need a software (e.g. RSSReader, Feed Demon, FeedReader, My Yahoo!, NewsGator and NewzCrawler) to get advantage of this tool. RSS feeds can also be read through FireFox or Microsoft Outlook 2007. Once any of these small (and mostly free) software is installed, add www.nigeriamedj.com/rssfeed.asp as one of the feeds.