



Sonographic Measurements of Ocular Biometry of Indigenous Nigerian Dogs in Zaria, Nigeria

Audu, H. A.¹; Idris, S. Y.²; Hamidu, A.³; Fadason, S. T.¹ and Lawal, M.¹ and Bappa, M. N.¹

¹Department of Veterinary Surgery and Radiology, Ahmadu Bello University Zaria; ²Department of Animal Health and Production, Binyaminu Usman Polytechnics Hadejia, Jigawa State; ³Department of Radiology, Ahmadu Bello University Teaching Hospital Zaria.. *Corresponding author: Email: drsheriffidris@gmail.com; Tel No:+2347037865325

SUMMARY

This study was aimed at conducting ophthalmic sonographic examination of Nigerian indigenous dogs to provide baseline information on some major ocular parameters. Healthy eyes of eighty (80) indigenous dogs were used for the study. The dogs were adequately restrained physically and the structure of the ocular globe was evaluated at a depth of 4-6 cm. For each dog, baseline data were obtained for D1= corneal thickness, D2= anterior chamber depth, D3= lens thickness, D4= vitreous chamber depth, and D5= the sagittal axial length of the eye. Similarly, the baseline data were obtained for A1= anterior chamber area, A2= lens area, A3= vitreous chamber area and A4= globe area. Result revealed that the baseline ocular parameters of the Indigenous Nigerian dogs' (in puppy, adult and older dogs respectively) were D1: 1.2 ± 0.2 mm, 1.4 ± 0.2 mm, 1.8 ± 0.2 mm; D3: 12.6 ± 0.6 mm, 13.6 ± 0.8 mm, 15.1 ± 0.9 mm and D5: 39.1 ± 1.4 mm, 42.5 ± 1.5 mm, 43.2 ± 2.1 mm. similarly, area biometry were obtained for A1: 30.8 ± 3.0 mm², 34.5 ± 3.6 mm² and 32.0 ± 4.6 mm² and A2: 213.7 ± 21.1 mm², 250.3 ± 23.6 mm², 264.8 ± 21.0 mm². Analysis of variance (ANOVA) with turkey's multiple comparison post-hoc test was used to compare the level of significance among the test groups. Values of $P < 0.05$ were considered significant at 95 % confidence. As such, it was deduced that these baseline ocular parameter values varied in two patterns: corneal thickness (D1), lens thickness and area (D3 and A2) and axial length and area (D5 and A4) increased with age from puppy to the adult and the older dogs in both sexes. However, the anterior chamber depth and area (D2 and A1) and vitreous depth and area (D4 and A3) increased initially with age from puppy to the adult dogs and then decreased slightly in the older dogs. The three (3) major ocular segments- anterior chamber, lens capsule and vitreous chamber was demonstrated in this study to represent approximately 2%, 17% and 76% respectively of the entire ocular globe area. The ciliary body and muscles, suspensory ligament and posterior chamber makes up the remainder 5%. This study has presented the baseline sonographic values of some major parameters of Indigenous Nigerian dogs in Zaria, and the values will be useful in the diagnosis ocular conditions that these may present.

Key words: Ultrasonography, Baseline Value, Nigerian indigenous Dog, Ocular Biometry.

INTRODUCTION

Vision is an integral part of every sighted animal's life (Anon, 1997). The organ of vision is the eye, and sight is a sense that is precious to humans as well as many animals, and hence, scientists have studied it more than any other sense. A dog's visual capabilities directly affect its ability to engage in high performance, visually orientated activities, such as guiding the blind, police work, obedience training, racing, and hunting (Miller and Murphy, 1995). The format and size of the canine skull vary according to the breed and individual conformation (Beserra *et al.*, 2009).

Different breeds of dogs have different eye shapes and dimensions, and also have different retina configurations (Anon, 1998). Anatomically, the eye is composed mainly of two segments - anterior and posterior eye segments (Shaw, 2011). Three portions make up the anterior eye segment. First is the anterior chamber which is bounded by cornea anteriorly and iris and anterior lens surface posteriorly and filled with aqueous humor. Second is the posterior chamber which is bounded anteriorly by iris, posteriorly by lens capsule and anterior vitreous face; filled with aqueous humor; and the third chamber is the vitreous, it is attached at the pars plana, posterior lens capsule and inner limiting membrane of retina; almost completely acellular. Separating the anterior and posterior chambers is the iris and ciliary body, whereas separating the posterior chambers and the vitreous chamber is the lens. The Posterior segment of the eye is composed of retina and choroid (Miller and Evans, 2013). The Uvea is composed of iris, ciliary body (anterior uvea) and choroid (posterior uvea). The Fundus is a part of the retina and all associated structures that are visible with the ophthalmoscope (Shaw, 2011).

Ultrasonography is useful for ophthalmologic examination of animals

because it is readily available, cost-effective, safe, and noninvasive and can typically be performed without sedation (Mettenleiter, 1995; Dietrich, 2007). The emergence of ultrasonography as a diagnostic tool has steadily increased ever since it was first used in the field of ophthalmology by Mundt and Hughes in 1956. Oksala and Lehtinen reported in 1958 the sound velocities in the various components of the eye. Baum and Greenwood came up with two dimensional immersion scan in 1958, which was subsequently improved upon by Purnell (1969), Coleman *et al* (1977) and Ossoinig (1979). Contact B-scan was introduced by Bronson and Fisher (1976), and it being portable, became part of everyday use in ophthalmology. There have been constant improvements in both, the standardized A-scan (Time amplitude scan) and B-scan (Brightness mode, two dimensional scan).

The diagnostic value of B-mode ultrasonography is high for animals with opacities of corneas, aqueous humor, lenses, or vitreous humor or pronounced eyelid swelling because direct observation of intraocular structures is not possible for such eyes and assessment of intraocular structures is important for determination of diagnoses and prognoses and for planning of treatments (Penninck *et al.*, 2001; Ramirez and Tucker, 2004). Even for animals for which direct observation of intraocular structures is possible, ultrasonography may be helpful for tumor identification, performance of measurements, and comparison of findings to those for the contralateral eye (Gonzalez *et al.*, 2001; Wollanke and Gerhards, 2011). Structures that cannot be observed by use of routine ophthalmologic examination techniques, such as ciliary bodies or retrobulbar spaces, can be evaluated via ultrasonography (Hoffmann *et al.*, 2004). Of the two display modes used during ocular ultrasonography of animals, brightness mode (B-mode) is

used more commonly than amplitude mode (A-mode) (Ramirez and Tucker, 2004). A-mode was recognized as more accurate than B-mode in detecting small lesions of the eye. (Ekesten 1994; Nyland and Mattoon, 1995).

The primary aim of this study is to provide baseline data on B-mode ultrasonographic examination of the normal eyes of Indigenous Nigerian dogs of various ages which may encourage veterinary practitioners in Nigeria to include ocular ultrasound as an integral part of ophthalmologic examination.

MATERIALS AND METHODS

Equipments

A Medison S600 ultrasound machine equipped with a 7.5MHz curvilinear probe along with a Sony videographic thermal printer was used. Other equipment used included a Riester-ri-scope ophthalmoscope (Otoscope-Ophthalmoscope, Type-C), Tonometer (icare tonometer ONE[®], TA02 model), clinical lab coat, disinfectants and mouth gag. Consumables used in the study included, thermal printing paper, aquasonic gel, tissue paper, 10 ml syringes (with 21 gauge needles), cotton wool, disposable gloves and mouth muzzle for dogs.

Source of Study Animals

A total of eighty dogs, 46 males and 34 females of different ages with clinically healthy eyes were used for the study, and they were divided into three (3) groups depending on their age (puppy/young-adult dogs as group 1, adult dogs as group 2 and older/senior-years dogs as group 3). The dogs that were presented belonged to people that resided in Hayin Dogo, Samaru and Sabon Gari areas of Faria, Kaduna state. The clients' (dog owners) consent was requested for and approval obtained before such dogs were included in the study.

Pre-ultrasound scanning consideration

All dogs that were selected for the study underwent a pre-study ophthalmic general

physical and clinical examination. This was to obtain the biodata of each dog (which was documented appropriately) and to ascertain that each of the dogs selected for the study had satisfied all the necessary clinical criteria for a healthy eye (or sight). Ophthalmoscopy and Tonometry were the two advanced ophthalmic examinations that were undertaken to further determine the status of each of the dogs' eyes.

Pre-scanning clinical physical examinations and tonometry were carried out in the open shade. However, the pre-scanning ophthalmoscopy was conducted in the lobby or any relatively dark section of the clients' home. The scanning procedure was carried out in the open shade as was tonometry. The dogs were adequately restrained using physical means (use of mouth muzzle in intractable ones) and psychologically subdued (by owners) all through the ophthalmic procedures of tonometry, ophthalmoscopy and ocular ultrasonography. Regular ophthalmic examination included direct ophthalmoscopy and tonometry. This was followed by ultrasonographic examination.

Ophthalmoscopy was carried out systematically, using the Reister-ri-scope ophthalmoscope, to view the ocular fundus, mainly the retina, some parts of the sclera and choroid as described by Maggs *et al.*, 2008. Restraint applied was with as minimal stress as possible; we ensured minimal to no restraint around the patient's neck and no pressure around the eye (Gellat, 2000).

Ultrasound Procedure/Technique

The dogs were positioned on sternal or lateral recumbency (depending on the convenience of examiner) and restrained manually, and the eyelids were held open by an assistant. The dog's head was firmly but lightly held, tilted and the eyelids were spaced out. Ultrasound coupling gel was applied to the cornea. Adequate contact between the probe of the ultrasound and the ocular surface was obtained with sterile

ultrasound gel (as described by Whitcomb, 2002).

Using the direct corneal contact technique, the transducer was placed directly on the cornea after spreading the coupling gel. Light pressure was applied on the eye during the scan as excess pressure encouraged blinking and a good contact between the transducer and the cornea was maintained. Both eyes were then examined. Light pressure was applied. Each eye was examined initially in longitudinal view (horizontal section) with the ultrasound beam running from the medial to the lateral canthi, and then the head of the transducer was rotated 90° to achieve the transverse view (visualize the vertical section of the eye), i.e parallel to the palpebral fissure and perpendicular to it. By convention the transducer position marker was placed towards the nose when scanning parallel to the palpebral fissure, and superior (dorsal) when scanning perpendicular to the palpebral fissure. The transducer was fanned from one side to the other to completely examine the globe as described by Whitcomb, 2002 and Bentley, 2003.

The structures of the globe were evaluated to a depth of 4–6 cm (Whitcomb, 2002). Ocular ultrasonograms were evaluated in respect to location of the intraocular structures of interest (i.e., anterior/posterior segment) and echo texture (isoechoic or hypo/hyper-echoic). A total of eighty dogs (160 eyes) were scanned. The structure of interest that were imaged and measured included the cornea (cornea thickness), anterior chamber (depth and area), anterior and posterior reflections of the lens capsule (lens thickness and area), and vitreous chamber (length and area). The globe was measured in an anterior to posterior direction at the point of maximal ocular diameter, so also was the area of the globe. The length dimensions were recorded in millimeter while the area dimensions were in millimeter square.

After ultrasound examination, excess coupling gel was carefully wiped from the

eyes using tissue paper. All images were digitally recorded and the views analyzed (Toni *et al.*, 2013). All measurements were determined using the in-built measurement facility of the scanner and the measurements taken were grouped. Measurements of axial globe length D5 in millimeter (mm) and globe area A4 in square millimeter (mm²) were determined in the horizontal (longitudinal) meridian.

Data was obtained as the mean of distances from three ultrasonograms for each measurement. Ultrasonograms were rejected when distances measured are more than 5% different from the others from the same eye, so as to minimize technical errors from machine and sonographer as suggested by Toni *et al.* (2013). The data generated were expressed as mean ± SD (standard deviation). Analysis of variance (ANOVA) with turkey's multiple comparison post-hoc test (T-Test) using Graph Pad Prism[®] version 5.0 for Windows[®] (Graph Pad software, san Diego, California, USA) was used to compare the level of significance among the test groups. Values of P < 0.05 were considered significant at 95 % confidence.

RESULTS

Pre-ultrasound ophthalmoscopic result of the fundus of the study dogs' eyes (right compared with left) revealed uniformity in size, shape, color and pigmentation of the fundic components – mainly the retina which was sighted through the red reflex, anterior segment disc, optic vessels, and lastly macula and fovea. This indicates that dogs' eyes were ophthalmoscopically normal. Tonometry also revealed that the IOP values were within the normal range (12-21mmHg) in all the study dogs examined.

The conductive ultrasonic gel used as a standoff pad was effective and allowed adequate scanning of the anterior segment of the eye, as well as identification of its structures in all eyes scanned as shown in plate I. The cornea was characterized by two parallel hyperechoic lines (anterior and

posterior corneal surface). The anterior chamber, filled with aqueous humor, was identified as an anechoic area just posterior to the cornea. It was possible to identify the lens by identifying both anterior and posterior capsules as parallel hyperechoic lines. The nucleus of the lens was identified as an anechoic area. The vitreous chamber, filled with vitreous humor, was identified as anechoic area. The posterior pole of the eye, which includes the retina, the choroid and the sclera, was identified. Measurement of the intraocular parameters of interest was obtained as thus, having identified each boundary bordering the structures. The baseline data values for corneal thickness (D1), anterior chamber length (D2), lens thickness (D3), vitreous chamber length (D4) and axial globe length (D5) were measured and recorded as shown in table 1. So also was the anterior chamber area values (A1), lens area values (A2), vitreous chamber values (A3) and globe area values

(A3) were measured and recorded for each group of the puppy, adult and older-years dogs that were studied (table 1).

The cornea thickness (D1), lens thickness and area (D3 and A2) and ocular globe length and area (D5 and A4) all increased with age from groups 1 to 3, in both sexes. However, the anterior chamber depth and area (D2 and A1) and vitreous length and area (D4 and A3) increased initially with age from puppy to adults and then decreased slightly in older dogs as illustrated in figures 1a and 1b.

There was no significant change observed in the mean and standard deviation (\pm SD) of biometric readings among the right and left eyes of dogs within the same group using turkey's multiple comparison post-hoc test ($P > 0.05$).

The three (3) major ocular segments- anterior chamber, lens capsule and vitreous chamber represent approximately 2%, 17% and 76% respectively of the entire ocular

Table 1: Baseline ocular biometry in Indigenous Nigerian Dogs

OCULAR BIOMETRY	GROUP 1 (Puppy/Young-adult dogs)	GROUP 2 (Adult dogs)	GROUP 3 (Older/senior-years dogs)
D1 Corneal Thickness	1.2 \pm 0.2 mm	1.4 \pm 0.2 mm	1.8 \pm 0.2 mm
D2 Anterior Chamber Length	2.3 \pm 0.2 mm	2.5 \pm 0.3 mm	2.5 \pm 0.4 mm
D3 Lens Thickness	12.6 \pm 0.6 mm	13.6 \pm 0.8 mm	15.1 \pm 0.9 mm
D4 Vitreous Chamber Length	23.0 \pm 1.0 mm	25.0 \pm 1.5 mm	23.9 \pm 1.4 mm
D5 Axial Globe Length	39.1 \pm 1.4 mm	42.5 \pm 1.5 mm	43.2 \pm 2.1 mm
A1 Anterior Chamber Area	30.8 \pm 3.0 mm ²	34.5 \pm 3.6 mm ²	32.0 \pm 4.6 mm ²
A2 Lens area	213.7 \pm 21.1 mm ²	250.3 \pm 23.6 mm ²	264.8 \pm 21.0 mm ²
A3 Vitreous Chamber Area	931.0 \pm 78.2 mm ²	1183.9 \pm 323.0 mm ²	1119.6 \pm 57.8 mm ²
A4 Globe Area	1336.9 \pm 82.2 mm ²	1455.6 \pm 57.7 mm ²	1477.9 \pm 84.7 mm ²

globe area as demonstrated in figure 2 . The remainder 5% is comprised of ciliary body and muscle, suspensory ligament and posterior chamber as shown in figure 2.

DISCUSSION

Biometry of the globe has been undertaken with A-mode ultrasonography where it is used to determine axial length prior to intraocular lens implantation (Gaiddon *et al.*, 1992) or for research purposes (Ekesten, 1994). In this study, B-mode ultrasonography was used to determine values for ocular parameters of dogs in the study area. Published research has shown A-mode and B-mode ultrasonography to give axial measurements that were not statistically significantly different and thus implies that B-mode ultrasonography can be as accurate as A-mode biometry (Osuobeni and Hamidzada, 1999; Williams, 2004). Biometry results for the one hundred and sixty (160) eyes of indigenous dogs, in which serial measurements were taken in this study, suggest that inaccuracy did not appear to be a problem.

Pre-ultrasound ophthalmology and tonometry were feasible in all dogs by mild manual and psychological restraint. Ophthalmic ultrasound was achieved by mainly manual restraint, placing dogs on sternal recumbency and manual opening of the eyelids, which was as described by Martins *et al.*, 2010. Thus, sedation and general anesthesia, proposed by earlier researchers such as Schiffer *et al.*, 1982 and Hager *et al.*, 1987, did not appear necessary in this circumstance. Therefore, anesthetic risks and additional costs were eliminated. All dogs were tolerant to ultrasound examination of the eye and no iatrogenic injury on the corneal surface was observed; this is in agreement with the findings of Martins *et al.* in 2010 and Toni *et al.* in 2010.

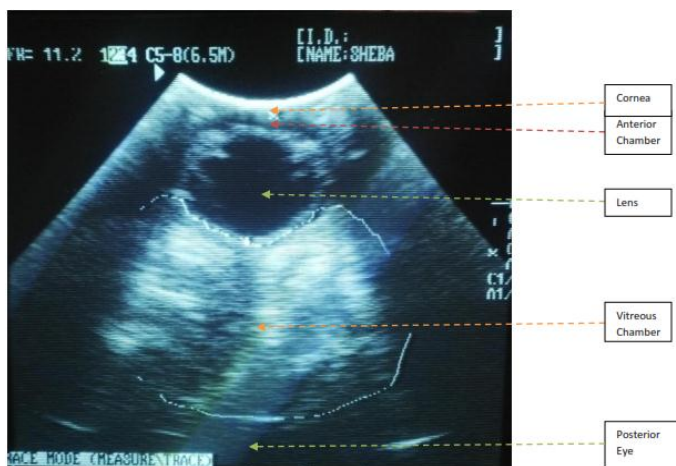


Plate I: Transcorneal B-mode ultrasonography from a normal Indigenous Nigerian dog's eye

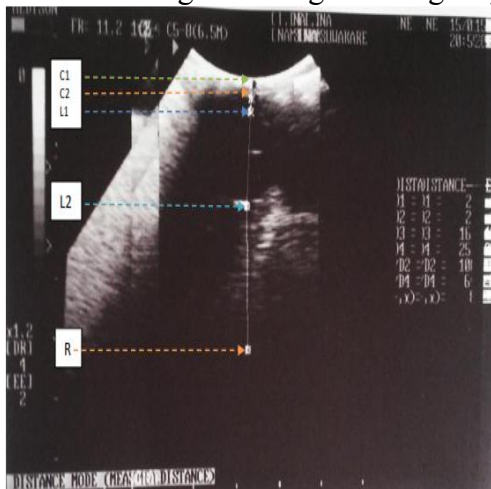


Plate II: Sonogram of ocular biometry of a clinically normal Indigenous Nigerian dog's eye
Key C: cornea; L1: anterior capsule, L2: posterior capsule, and R: retina.

Note the axial globe length (D5: 45mm, distance between C1 and R), corneal thickness (D1:2mm, distance between C1 and C2), the anterior chamber depth (D2: 2mm, distance between C2 and L1), lens thickness (D3: 16mm, distance between L1 and L2), and posterior chamber depth (D4: 25mm, distance between L2 and R)

The use of the conductive gel acting as a standoff pad (Cottrill *et al.*, 1989), allowed adequate visualization of the cornea and anterior chamber, which was important for the obtaining reliable images and measurements. It also provided adequate contact of the transducer with the surface of the cornea, with minimal pressure on the

eye, which resulted in less discomfort for the study animals, as stipulated by McMullen and Gilger, 2006; Wilkie *et al.*, 2006 and Toni *et al.*, 2010.

In the present study, there were no statistically significant differences observed when comparing the mean values obtained for intraocular biometric parameters between the right and left eyes of dogs in the same group (T – Test, with $P > 0.05$). This

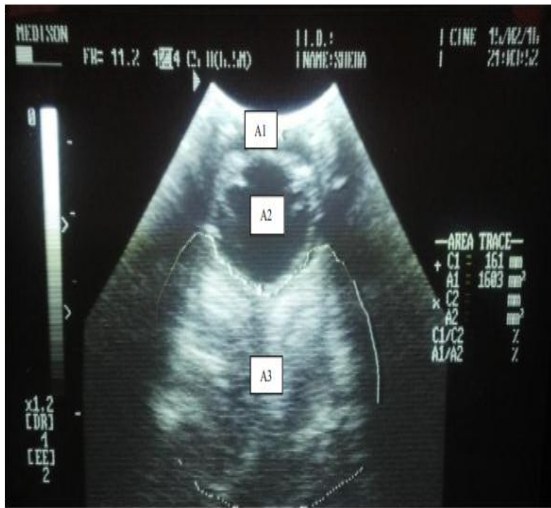


Plate III: Sonogram of an Indigenous Nigerian dog’s eye depicting area measurement of the vitreous chamber (A3:1603mm²)

Key A1: Anterior chamber area, A2: Lens area, A3: Vitreous chamber area (1603mm²)

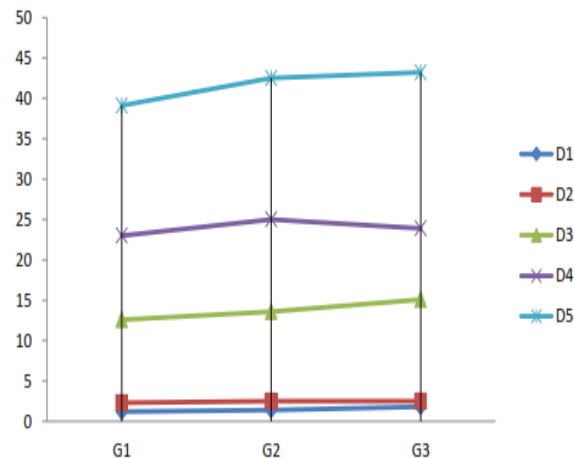


Figure 1a: Variability of Intra-ocular parameters according to age group in the study dogs (length in mm)

implied that the ocular parameters of the right and left eyes of a dog with healthy eyes were the same, confirming the same findings carried out in Samoyed dogs (Ekestén, 1994) and other species (Osuobeni and Hamidzada, 1999;

Paunksnienė and Babrauskienė, 1996; Paunksnienė *et al.*, 1997; Ramsey *et al.*, 1999), including humans (Lim *et al.*, 1992). Therefore, measurements of the normal eye can provide reliable parameters for determination of the size of eye prosthesis in cases of malformation or enucleation of the eye. This is similar with the reports by other authors (Williams, 2004; Tuntivanich *et al.*, 2007). However, the biometric values obtained for lens thickness, vitreous length and area, axial length and globe area were significant within and between the puppy, adult and older groups of dogs ($P < 0.05$). The finding revealed that these intraocular parameters increased significantly from puppy to adult and old age. Similar findings were documented by earlier researchers that revealed that the ocular variables were influenced by age (Paunksnis *et al.*, 2001) or weight and size (Sampaio *et al.*, 2002 and Toni *et al.*, 2013). This feature is important considering the use of dogs as experimental models for the study of myopia in humans (Black *et al.*, 2008; Williams *et al.*, 2011),

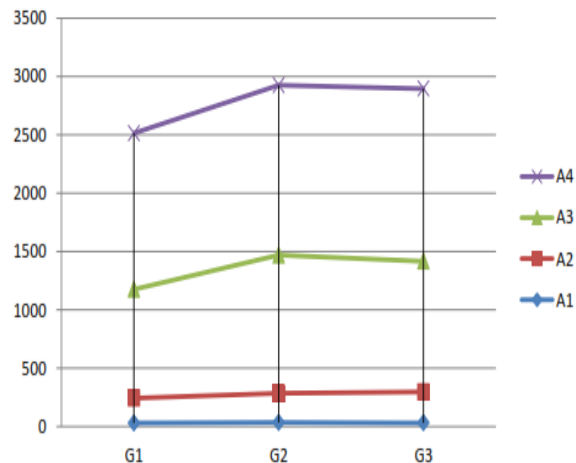


Figure 1b: Variability of Intra-ocular parameters according to age group in the study dogs (area in mm²)

which remains a significant and highly prevalent worldwide problem (Toni *et al.*, 2013).

Paunknis and his study teams reported in 2001 that canine corneal thickness biometric values measured by different researchers may not exactly be the same. The values found in the present study for corneal thickness measured by B- mode ocular ultrasound biometry in Nigerian indigenous dogs were similar to those found in the study reported by Paunksnis *et al.*, in 2001. According to Ekesten in 1994, the corneal thickness increased throughout the dog's life; initially it grows rapidly, but later it grows more slowly. This was illustrated in the present study too.

This study demonstrated and confirmed findings by Ekesten and Torrang in 1995 that axial length, increases with age. Axial length is typically regarded as the primary determinant of refractive error. The correlation with refractive error is larger for axial length than for any other component of the eye (Mutti *et al.*, 2007; Fontes *et al.*, 2011). It was also observed that lens thickness increased with age from puppy to adult and older aged dogs, a feature that was noted in previous reports by Williams in 2004 in dogs and by Hoffer in 1993, in the human subjects. It was also demonstrated that the anterior chamber depth and area, and vitreous length and area all increased initially with age from puppy to adult, but then decrease in older dogs. These changes could be due to the fact that increasing in lens thickness with age reduces the chambers of the eyes with which it borders with, i.e anterior chamber and vitreous chamber.

The findings of the present study also revealed that the vitreous chamber was the largest area within the eye globe. Next to it was the lens area and the smallest was the anterior chamber area.

Based on the findings arrived at in the present study it was possible to conclude that B-mode ophthalmic ultrasound was an effective method for the determination of the

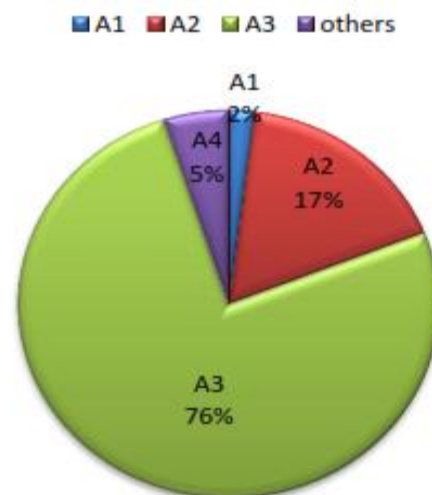


Figure 2: Percentage Area occupied by ocular chambers

Key: ■ A1: anterior chamber area ■ A2: lens capsule area ■ A3: vitreous chamber area ■ A4: others

Note: others represent area occupied by ocular structures other than the anterior chamber, lens and vitreous chamber, such as ciliary body and muscle, suspensory ligament and posterior chamber.

anatomical guide necessary to demonstrate the use of ocular sonograph in diagnosis of ocular conditions by determine baseline information on the ultrasonographic examination of the eyes of the dogs. Also, with an appropriate understanding of the indications for ocular ultrasonography and proper examination technique, one can gather a vast amount of information easily and quickly with ocular ultrasonography, which may not be possible with clinical examination alone in order to arrive at an acceptable diagnostic protocol and proffer management guide as well as prognosis for ocular conditions.

The intraocular parameters of length and area in the Indigenous Nigerian dogs' eyes are slightly lower than those of Exotic breeds and remarkably lower than those of the Dolicephalic exotic breeds.

REFERENCES

- ANON (1997): The Foundation of the American Academy of Ophthalmology. Museum of Vision and Ophthalmic Heritage 1997. www.museumofvision.org Accessed 11/11/2014, 9:23am
- ANON (1998): Arts and Entertainment Network. Big dogs little dogs: The world of our canine companions. GT publishing corporation. 23-55. <http://www.amazon.com/Bid-Dogs-Little-Canine-Companions/dp/1577193539>. Accessed 03/01/2014 at 9:44 am.
- BAUM, G. and GREENWOOD, I. (1958). The application of ultrasonic location, techniques to ophthalmology: theoretic considerations and acoustic properties of ocular media: Part 1, Reflective properties. *American Journal of Ophthalmology*. 46:319-329.
- BLACK, J., BROWNING, S. R., COLLINS, A. V., PHILLIPS, J. R. (2008). A canine model of inherited myopia: familial aggregation of refractive error in labrador retrievers. *Investigative Ophthalmology and Visual Science*. 49:11:4784-4789.
- BENTLEY, E., MILLER, P. E. and DIEHL, K. A. (2003). High resolution ultrasound as a diagnostic tool in veterinary ophthalmology. *Journal of American Veterinary Medical Association*. 223(11): 1617-1622.
- BESSERR, P. S., SALES, G. A., SANTANA, E. J. M., MIRANDA, S. A., BRITO, A. B., NICKOLAK, E., DOMINGUES, S. F. S. (2009). Relação entre a biometria ultrasonográfica em modo B do bulbo ocular e os diâmetros fronto occipital e bizigomático em Canis familiaris. *Pesquisa Veterinária Brasileira*, Vol.29, n.4, 286-290.
- COLEMAN, D. J.; LIZZI, F. L. and JACK, R. L. (1977). *Ultrasonography of the eye and orbit*. Philadelphia: Lea and Febiger. 76-77.
- COTTRILL N. B., BANKS W. J. and PECHMAN R. D. (1989). Ultrasonographic and biometric evaluation of the eye and orbit of dogs. *American Journal of Veterinary Research*.50,(6):898-903.
- DIETRICH, U. M. (2007). Ophthalmic examination and diagnostics part 3: diagnostic ultrasonography. In: Gelatt KN, ed. *Veterinary ophthalmology*. 4th ed. Ames, Iowa: Blackwell Publishing. 507-519
- EKESTEN B. (1994). Biological variability and measurement error variability in ocular biometry in Samoyed dogs. *Acta veterinaria Scandinavica*.35:427-433.
- EKESTEN, B. and TORRANG, I. (1995). Heritability of the depth of the opening of the ciliary cleft in Samoyeds. *American Journal of Veterinary Research*. 56:1138-1143.
- FONTES, B. M.; FONTES, B. M.; CASTRO, E. (2011). Intraocular lens power calculation by measuring axial length with partial optical coherence and ultrasonic biometry. *Arquivo Brasileiro de Oftalmologia*.74(3):166-170.
- GAIDDON J.; ROSOLEN S. G.; STERU, L. (1992). Use of biometry and keratometry for determining optimal power for intraocular lens implants in dogs. *American Journal of Veterinary Research*. 52(5):781-783
- GELATT, K. N. (2000). *Essentials of Veterinary Ophthalmology*. Lippincott Williams and Wilkins, Philadelphia, Pennsylvania, USA. 509-530
- GONZALEZ, E. M., RODRIGUEZ, A. and GARCIA, I. (2001). Review of ocular ultrasonography. *Veterinary Radiology and Ultrasound*. 42:6:485-495.
- HAGER, D. A.; DZIEZYC, J.; MILLCHAMP, N. J. (1987). Two-

- dimensional real-time ocular ultrasonography in the dog. *Veterinary Radiology*.28(2):60-66.
- HOFFER, K. J. (1993). Axial dimension of the human cataractous lens. *Archives of Ophthalmology*.111: 914-918.
- HOFFMANN, I. SCHÄFFER, E. and REESE, S. (2004). Die sonographische Untersuchung des vorderen Augenabschnittes beim Kleintier. Teil 2: pathologische Befunde. *Tierarztl Prax K*. 32:238-246.
- MAGGS, D.; PAUL M. and RON O. (2008). Slatter's *Fundamentals of Veterinary Ophthalmology*, 4th edition. Vol 2: Wiley Blackwell. USA
- MARTINS, B. C.; RODRIGUES JR, E. F.; SOUZA, A. L. G.; ALMEIDA, D. E.; BRITO, F. L.; CANOLA, J. C.; BROOKS, D. E.; LAUS, J. L. (2010). A and B mode ultrasonography in preoperative evaluation of lens and posterior segment of dogs eyes with cataract. *Pesquisa Veterinária Brasileira*.30(2):121-126.
- McMULLEN, R. J. Jr, and GILGER, B. C. (2006). Keratometry, biometry and prediction of intraocular lens power in the equine eye. *Veterinary Ophthalmology*. 9:357-360.
- METTENLEITER, E. M. (1995). Sonographic diagnosis (B-mode technique) for the eyes in horses. 1. Methods and normal findings. *Tierarztl Prax*.23:481-488.
- MILLER, M. E. and EVANS, H. E. (2013). *Miller's Anatomy of the Dog*. Erun de lara. 4th ed. Elsevier Health. Saunders. NewYork.
- MILLER, P. E and MURPHY C. J. (1995). Vision in dogs. *Journal of American Veterinary Medical Association*. 207:12
- MUNDT, G. H. and HUGHES, W. E. (1956). Ultrasonics in ocular diagnosis. *American Journal of Ophthalmology*. 41:488- 498.
- MUTTI, D. O.; HAYES, J. R.; MITCHELL, G. L.; JONES, L. A.; MOESCHBERGER, M. L.; COTTER, S. A.; KLEINSTEIN, R. N.; MANNY, R. E.; TWELKER, J. D.; ZADNIK, K. (2007). Refractive error, axial length, and relative peripheral refractive error before and after the onset of myopia. *Investigative Ophthalmology and Vision Science*.48(6):2510-2519.
- NYLAND, T. G. and MATTOON, J. S. (1995). *Veterinary diagnostic ultrasound*. W.B. Saunders company. P.178-197.
- OKSALA, A. and LEHTINEN A. (1958). A measurement of the velocity of sound in some parts of the eye. *Acta Ophthalmol (Copenh)*.36:633-639.
- OSUOBENI, E. P. and HAMIDZADA, W. A. (1999). Ultrasonographic determination of the dimensions of ocular components in enucleated eyes of the one-humped camel. *Research in veterinary science*.67:125-129.
- PAUNKSNIENĖ, M. and BABRAUSKIENĖ, V. (1996). Structural peculiarities of domestic eye tunics. *Veterinarija ir zootechnika*. T.1(23):90-94.
- PAUNKSNIENE, M., BABRAUSKIENE, V., and PAUNKSNIS, A. (1997). Ultrasonographic evaluation of animal eye dimensions. *Veterinarija ir zootechnika*. T.3(25):29-33.
- PAUNKSNIS, A.; SVALDENIENĖ, S.; PAUNKSNIENĖ, M. and BABRAUSKIENĖ, V. (2001). Ultrasonographic evaluation of the eye parameters in dogs of different ages. ISSN 1392-2114 *ULTRAGARSAS*, Nr.2(39).
- PENNINCK, D.; DANIEL, G. B. and BRAWER, R. (2001). Cross-sectional imaging techniques in veterinary ophthalmology. *Clinical*

- Techniques in Small Animal Practice. 16(1):22-30.
- PURNELL, E. W. (1969). B mode orbital ultrasonography. *International Ophthalmology Clinics*.9:643-665.
- RAMIREZ, S. and TUCKER, R. L. (2004). Ophthalmic imaging. *Veterinary Clinic of North American Equine Practice*.20:441-457
- RAMSEY, D. T., HAUPTMAN, J. G, and PETERSEN-JONES, S. M. (1999). Corneal thickness, intraocular pressure and optical corneal diameter in Rocky Mountain Horses with cornea globosa or clinically normal cornea. *American Journal of Veterinary Research*. 60:1317-1321.
- SAMPAIO, G. R.; RANZANI, J. J. T.; and SHELLINI, S. A. (2002). Sexo, peso e conformação anatômica do olho sobre o cálculo de poder dióptrico de lentes intra-oculares no cão. *Ciência Rural*. 32(2):263-268.
- SCHIFFER, S. P.; RANTANEN, N. W.; LEARY, G. A.; and BRYAN, G. M. (1982). Biometric study of the canine eye using A-mode ultrasonography. *American Journal of Veterinary Research*.43(5):826-830.
- SHAW, G. (2011). The Eye Anatomy, Histology & Histopathology. gillianshaw@gmail.com accessed on 04/04/2014 15:35 HR
- TONI, M. C.; MEIRELLES, A. E. W. B.; LAUS, J. L and CANOLA, J. C. (2013). Ophthalmic ultrasound of dogs with different skull conformations. *Revista Brasileira de Ciências Agrárias*. Recife.8(2):331-335.
- TONI, M. C.; MEIRELLES, A. E. W. B.; GAVA, F. N.; CAMACHO, A. A.; LAUS, J. L.; CANOLA, J. C. (2010). Rabbits' eye globe sonographic biometry. *Veterinary Ophthalmology*.13(6):384-386
- TUNTIVANICH, N., PETERSEN-JONES, S. M., STEIBEL, J. P., JOHNSON, C. and FORCIER, J. Q. (2007). Postnatal development of canine axial globe length measured by B-scan ultrasonography. *Veterinary Ophthalmology*.10(1):2-5.
- WHITCOMB, M.B. (2002). How to diagnose ocular abnormalities with ultrasound. *Proceedings in American Association of Equine Practitioners* 481: 272-275
- WILLIAMS, D. L. (2004). Lens morphometry determined by B-mode ultrasonography of the normal and cataractous canine lens. *Veterinary Ophthalmology*.7,(2):91-95.
- WILLIAMS, L. A., KUBAI, M. A., MURPHY, C. J. and MUTTI, D. O. (2011). Ocular components in three breeds of dogs with high prevalence of myopia. *Optometry and Vision Science*.88:2:269-274.
- WOLLANKE, B. AND GERHARDS, H. (2011). Atlas of ultrasound examination in the Horse. In: Glatzel P. S, ed. *Atlas of Equine Ultrasonography*: Schlütersche Publisher mbH Co. KG. . Hannover, Germany.