

ORIGINAL ARTICLE

Experience with the Use of Negative Pressure Bolster Dressing for Stabilization of Skin Grafts

Kingsley O OPARA¹
Ifeanyi C NWAGBARA²

¹Plastic Surgery Division

²Orthopaedic Surgery
Division

Department of Surgery
Imo State University Teaching
Hospital Orlu, Imo State
NIGERIA

Author for Correspondence

Dr Kingsley O OPARA
PO BOX 442 Woji, Port
Harcourt, NIGERIA

Phone: +234 803 097 7149

Email: kin2para@yahoo.co.uk

Received: December 5th, 2016

Accepted: January 20th, 2017

DISCLOSURES

There were no conflicts of interest, and the researchers did not receive any form of sponsorship for the study.

INTRODUCTION

Skin grafting is a dependable and well-accepted procedure for the management of skin loss. Survival of skin grafts, however, requires that the processes involved in graft nutrient uptake and vascularisation are not disrupted. These processes are plasmatic imbibition in the first 24-48hours, vascular inosculation in 2 to 4days, and neovascularisation which usually occurs by the 5th to 7th day.¹ Skin graft-wound bed contact must, therefore, be secure to prevent disruption of these fragile processes. Ensuring

ABSTRACT

Background: The ability to apply a skin graft snugly to the bed, and limit shearing forces, goes a long way in determining outcome. It is often a challenge achieving this over highly contoured wounds and wounds located on highly mobile regions of the body, where the use of external splints pose some difficulty.

Objective: To assess the outcome of negative pressure wound dressing as an alternative means of skin graft stabilization over contoured wounds and wounds located in complex anatomic regions of the body.

Methodology: This was a prospective study of consecutive patients from January 2009 to December 2010, with wounds over uneven and highly mobile anatomic regions that had their skin grafts stabilized using negative pressure wound dressing. Data on patients' age, sex, region of the body that was skin grafted, size of skin graft and graft-take were analysed using descriptive statistics.

Results: There were 12 patients with 15 wounds. Regions of the body involved were the dorsum of the hand(6), the anterior chest wall (3), the anterior neck region(1), the axilla(2), the elbow region(1), the dorsum of the foot(1) and a below knee amputation stump(1). Wound sizes ranged from 80cm² to 192cm². Nine wounds were covered with partial thickness skin grafts, while 6 had full thickness skin grafts. Graft survival was 98 to 100% in all wounds with no case of graft infection.

Conclusion: Negative pressure dressing is an effective means of graft stabilization over anatomically complex wounds.

Keywords: Anatomic region, Complex, Outcome, Wounds

such security over anatomically challenging areas such as highly mobile regions and uneven surfaces is often a challenge and success with skin grafting over such regions has been limited.²

The use of cotton bolster dressings and external splints have been the time honoured traditional means of securing skin grafts over such anatomically challenging regions of the body.³ Their use, however, could be cumbersome in certain regions of the body

like the neck, hands, axilla, anterior chest wall, etc.

Negative pressure wound dressing first described by Fleischmann, *et al.* in 1993, has gained momentum over the years, not just as an effective method of dressing wounds of varying aetiologies, but in more recent years as an effective means of securing skin grafts.^{4,5,6} By applying negative pressure evenly distributed over the entire wound surface, it ensures good graft-bed contact and graft stabilization even in wounds with complex contours and those located in highly mobile regions of the body.

The aim of this study was to examine the outcome of the use of negative pressure wound dressing (Vacuum Assisted Wound Closure[VAC]) as a bolster dressing for skin grafts over anatomically challenging parts of the body, without the additional use of external splints.

METHODOLOGY

This was a prospective study. In the period of study (January 2009 to December 2010), consecutive patients who required skin grafting over anatomically challenging areas of the body such as the neck, axilla, hands, anterior chest wall and elbow regions were recruited into the study. All VAC applications, skin grafting procedures and graft inspections, were carried out by the same primary surgeon to ensure consistency of procedure and to avoid inter - observer error.

Procedure

After adequate wound bed preparation, skin grafts were pie crusted (Figure 1), and secured over the wound bed using interrupted sutures. A non-sticky dressing (framycetin sulphate impregnated gauze) was applied over the skin graft before application of the negative pressure dressing. The KCI Wound VAC system (*Kinetic Concepts, Inc, San Antonio, TX Model N0. M3252719 Rev E, C22.2 number 601-1-M90*) was used with granular

VAC foam dressing (Figure 2). A negative pressure of -125 mmHg was used in all cases. All patients were managed on in-patient basis for the period of negative pressure therapy. All grafts were inspected on the seventh post-operative day as no complications warranting earlier graft inspection occurred.

Data on patients' age, sex, region of the body skin grafted, size of skin graft in square centimetres, and parameters of outcome such as graft infection, graft displacement and graft take were collated and analysed using simple descriptive statistics.

RESULTS

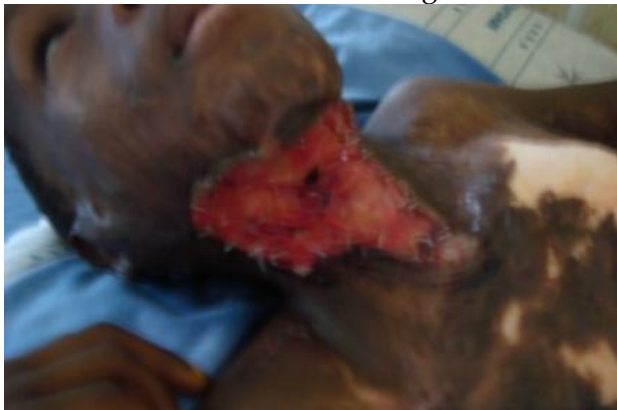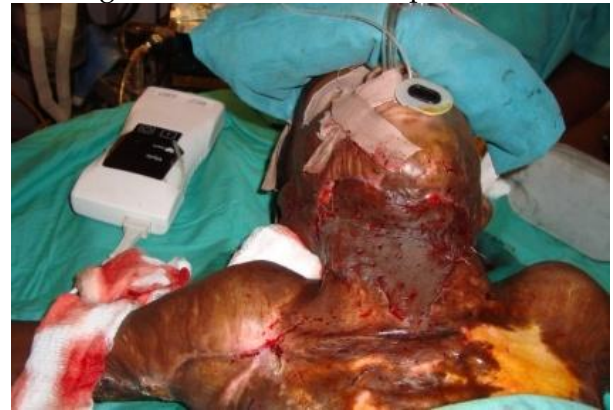There were 12 patients with 15 wounds. Five of the patients were males and seven females. Their ages ranged from 8 to 78 years with a mean age of 39.9 years (Figure 3). Six wounds involved the dorsum of the hand, 3 were anterior chest wall wounds and 1 an anterior neck wound. Other regions of the body involved were the axilla in 2 patients, and the elbow in one patient. The dorsum of the foot was involved in one patient, and a below knee amputation stump in another (Table 1). Ten wounds were secondary defects resulting from release of post-burn contractures, three were post-tumour excision wounds, one was post-traumatic, and one followed wound breakdown in a below knee amputation stump.

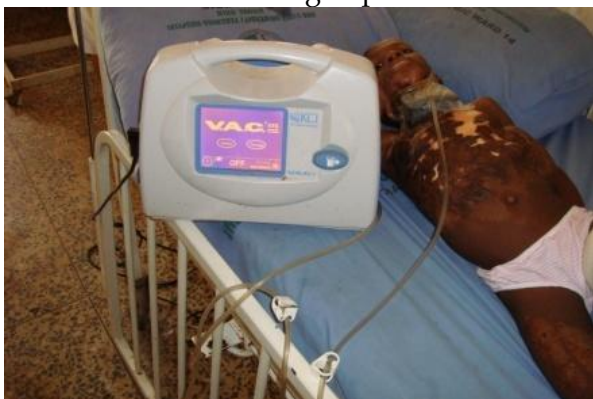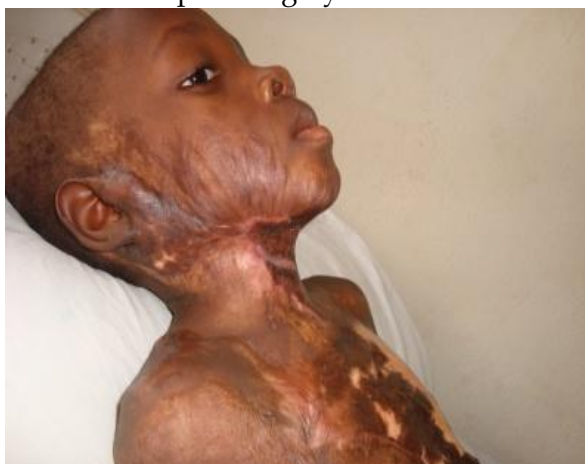Wound sizes were recorded as a product of the length and width of the wounds in their widest dimensions. In this series, the wound sizes ranged from 80cm² to 192cm². Nine wounds were covered with partial thickness skin grafts, while 6 had full thickness skin grafts.

There were no signs of graft infection and no graft displacement in any of the patients. Fluid collections such as haematomas and seromas were absent in all cases. Graft survival was 98 to 100% in all wounds, *see Table 1.*

Table 1. Patient Characteristics

Serial No.	Sex	Aetiology	Body region	Wound size(cm2)	Type of skin graft	Graft Take
1	F	Mento-sternal contractures	Anterior Neck	168	STSG	98%
2	F	Post-tumour resection	Left Anterior chest wall	155	STSG	100%
3	F	Post-tumour resection	Left Anterior chest wall	192	STSG	100%
4	F	Post-tumour resection	Left Anterior chest wall	104	STSG	100%
5	M	Post-burn contracture release	Dorsum Right hand	182	FTSG	100%
			Dorsum Left hand	168	FTSG	99%
6	M	Post-burn contracture release	Dorsum Right hand	110	FTSG	98%
			Dorsum Left hand	88	FTSG	100%
7	F	Post-burn contracture release	Dorsum Right hand	80	STSG	99%
8	M	Post-burn contracture release	Dorsum Right hand	64	STSG	99%
9	M	Amputation stump wound breakdown	Left b/k amputation stump	99	STSG	100%
10	F	Post-burn contracture release	Left Axilla	120	FTSG	100%
		Post-burn contracture release	Left elbow	84	FTSG	100%
11	M	Post-burn contracture release	Left Axilla	72	STSG	100%
12	F	Post-traumatic	Dorsum Right foot	80	STSG	100%

Figure 1. Skin defect following release of mento-sternal contracture, reconstructed with integra and split thickness skin graft pie-crusting, with VAC bolster dressing.**1a.** Skin defect covered with integra**1b.** Integra overlaid with STSG pie-crusting

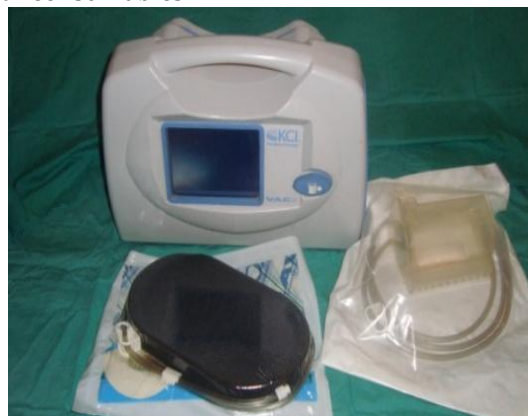1c. VAC bolster dressing in place**1d. Six weeks post surgery****DISCUSSION**

Conventional skin graft stabilization techniques such as bolster dressings and external splints are often cumbersome and may be ineffective in some complex anatomic regions.² In these situations the aim of these stabilization techniques which is the prevention of shearing forces, and prevention of the accumulation of fluid or haematoma beneath the graft may not be easily achievable using these conventional techniques. The negative pressure wound dressing has been reported to be able to achieve these even in complex anatomic regions. Indeed in our study, no patient had fluid collections, and none of the skin grafts were displaced. It is even more encouraging to note that external splints were not utilized in any of these patients. These splints in certain regions of the body may be cumbersome and unacceptable to the patients; for example, the use of aeroplane splints for immobilization of the axilla.⁷ This is especially important in children and the elderly, in whom the use of

Negative Pressure Wound Dressing to the preclusion of the use of external splints may be more acceptable. In addition, the undesirable sequelae associated with the use of these splints are avoided. This is especially important in the very young and elderly who are more at risk of developing complications with the use of splints.⁸ The applicability of the Negative Pressure Wound Therapy in virtually all age groups as shown in our study makes it a welcome alternative especially in these age groups.

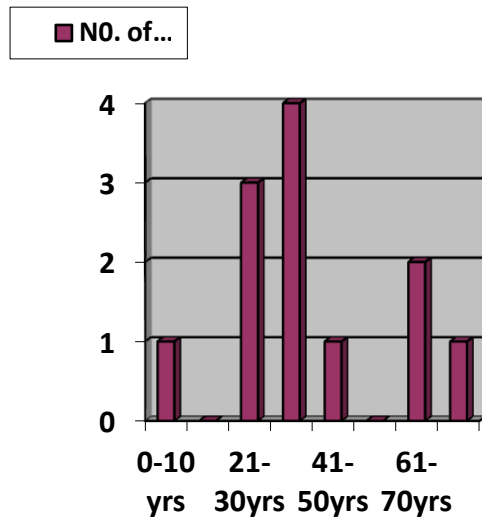
In this study, Negative Pressure Dressing was used in stabilization of skin grafts in virtually all regions of the body with excellent results (Table 1). Even in regions of the body such as the perineum where the use of splints and bolster cotton dressings may be quite challenging, the use of negative pressure dressing for skin grafts has showed excellent results.^{9,10} This adaptability in its application makes it a versatile tool in the stabilization of skin grafts.

Figure 2. Vacuum Assisted Closure (VAC) device, with consumables



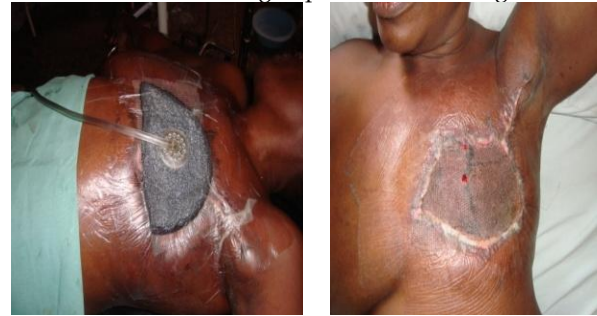Graft-take was excellent in all patients with graft survival above 95% in all cases (table 1). This is similar to reports from other studies on Negative Pressure Wound Therapy stabilization of skin grafts. In theory, a minimum downward pressure of 25mmHg is required by the tie-over dressing to exceed capillary pressure and prevent haematoma formation.¹¹

Figure 3. Age distribution of patients



It has been proposed that pressure necrosis may occur if too much pressure is exerted, especially over bony prominences. With tie over dressings, the pressures exerted by these dressings may be difficult to regulate as it would vary with the surgeon. With the Negative Pressure Wound Therapy (NPWT) however the pressure exerted on the skin graft is regulated, and therefore the risk of skin graft necrosis from excessive application of pressure is limited. Even for full thickness skin grafts which require more stringent conditions for take, graft survival was equally excellent (figures 4, 5 & 6). The most frequent reasons for graft failure, which are non adherence and accumulation of secretions between the graft and the wound bed, are effectively counteracted by negative pressure dressing.¹² In addition, negative pressure dressing has been shown to increase blood flow, increase the rate of granulation tissue formation, reduce local wound oedema and decrease wound bacterial counts significantly.^{5,13} All of these may indeed contribute to the accelerated process of graft take reported in experimental models.¹⁴

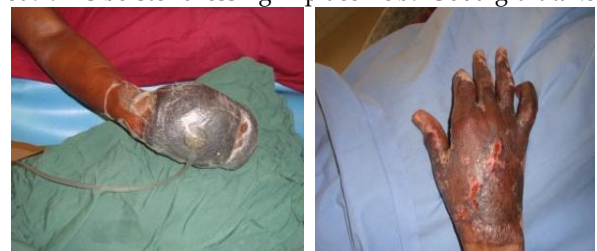4a. VAC bolster dressing in place **4b.** Good graft take



The challenge with this technique of skin graft stabilization however may be its cost effectiveness. This is especially important in a resource poor environment like ours, with limited funds available for medical care. Other researchers have suggested cheaper alternatives to the conventional VAC machine. These alternatives include the regular suction machines, surgical vacuum bottles or even weight loaded syringes.^{15,16}

Figure 5. Full thickness skin graft re-construction of the dorsum of the hand after excision of scar contracture:

5a. VAC bolster dressing in place **5b.** Good graft take



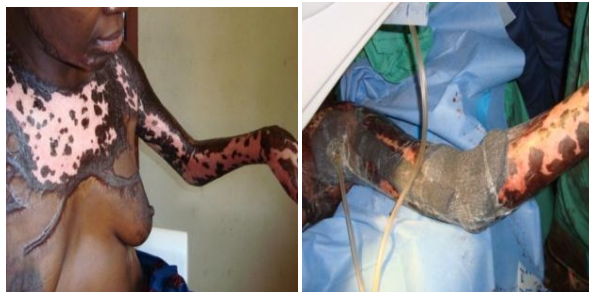5c: Good range of motion achieved



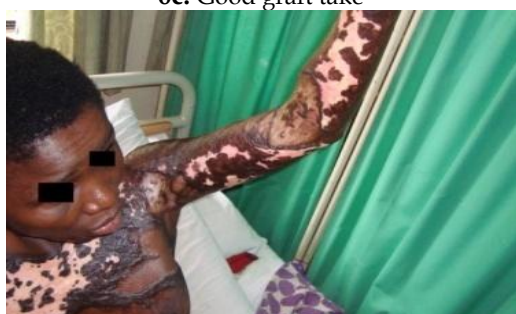The challenge with the use of these alternative devices, however, is in maintaining the negative pressure generated within the optimum range of 80 to 125mmHg suggested by Borgquist, *et al.*¹⁷ Such devices if appropriately adapted for use in negative pressure wound dressing should be more cost effective.

Figure6. Release of axillary and elbow contractures and full thickness skin graft reconstruction of the secondary defects, VAC dressing used in skin graft stabilization

6a. Contractures **6b.** Graft stabilization with VAC



6c. Good graft take



CONCLUSION

Negative pressure dressing is an effective means of graft stabilization over anatomically complex wounds and may improve graft survival both for split thickness and full thickness skin grafts.

REFERENCES

- Kelton PL Skin grafts and skin substitutes. Selected Readings in Plastic Surgery 1999; 9(1):1-24.
- Blackburn JH, Boemi L, Hall WW, et al. Negative-pressure dressings as a bolster for skin grafts. *Ann Plast Surg* 1998; 40:453-457.
- Rudolph R, Ballantyne DL. Skingrafts. In: McCarthy J, editor. Plastic Surgery: Vol. 1 General Principles Philadelphia, PA: WB Saunders; 1990. p. 221-274.
- Fleischmann W, Strecker W, Bombelli M, et al. Vacuum sealing as treatment of soft tissue damage in open fractures. *Unfallchirurg* 1993; 96:488-492.
- Argenta LC, Morykwas MJ. Vacuum-assisted closure: a new method for wound control and treatment: clinical experience. *Ann Plast Surg* 1997; 38:563-577.
- Hynes PJ, Earley J, Lawlor D. Split-thickness skin grafts and negative-pressure dressings in the treatment of axillary hidradenitis suppurativa. *Brit J Plast Surg* 2002; 55:507-509.
- Morgan WP, Harding KG, Hughes LE. A comparison of skin grafting and healing by granulation, following axillary excision for hidradenitis suppurativa. *Ann R Coll Surg Engl* 1983; 65:235-236.
- Halanski M, Noonan KJ. Cast and splint immobilization: complications. *J Am Acad Orthop Surg* 2008; 16:30-40.
- Weinfeld AB, Kelley P, Yuksel E, et al. Circumferential negative-pressure dressing (VAC) to bolster skin grafts in the reconstruction of the penile shaft and scrotum. *Ann Plast Surg* 2005; 54:178-183.
- Senchenkov A, Knoetgen J, Chrouser KL, et al. Application of vacuum-assisted closure dressing in penile skin graft reconstruction. *J Urol* 2006; 67:416-419.
- Seymour FK, Giele HP. Tie-overs under pressure. *Br J Plast Surg* 2003; 56:494-497.
- Sposato G, Molea G, DiCaprio G, et al. Ambulant vacuum-assisted closure of skin graft dressing in the lower limb using a portable mini-Vac device. *Br J Plast Surg* 2001; 54:235-237.
- Fabian TS, Kaufman HJ, Lett ED, et al. The evaluation of sub-atmospheric pressure and Hyperbaric oxygen in ischemic full-thickness wound healing. *Am Surg* 2000; 66:1136-1143.
- Simman R, Forte R, Silverberg B, et al. A Comparative Histological Study of Skin Graft Take with Tie-Over Bolster Dressing Versus Negative Pressure Wound Therapy in a Pig Model: A Preliminary Study. *Wounds* 2004; 16(2):76-80.
- Meyer DC, Husler R, Werner CM, et al. Weight loaded syringes as a simple and cheap alternative to pumps for vacuum-enhanced wound healing. *Plast Reconstr Surg* 2005; 115:2174-2176.
- Steve T. An introduction to the use of vacuum assisted closure. World Wide Wound. 2001. pp. 1-12. Available from: <http://www.worldwidewounds.com/2001/may/Thomas/Vacuum-Assisted-Closure.html>
- Borgquist O, Ingemansson R, Malmso M. Wound edge microvascular blood flow during negative-pressure wound therapy effects of pressures from -10 to -175. *Plast Reconstr Surg* 2010; 125:502-509