

## CASE REPORT

## Histologically Diagnosed Cases of Nasopharyngeal Carcinoma in Two Nigerian Children within One Year Period: Case Reports and Review of Literature

Michael E

**ONWUKAMUCHE**  
Chinedu O **NDUKWE**  
Cornelius O **UKAH**

Department of Histopathology  
Nnamdi Azikiwe University  
Teaching Hospital Nnewi  
Anambra State, NIGERIA

Author for correspondence

Michael E **ONWUKAMUCHE**  
Department of Histopathology  
Nnamdi Azikiwe University  
Teaching Hospital, PMB 5025  
Nnewi, Anambra State  
NIGERIA

Email: kamuchemike@gmail.com  
Phone: +2348030949947

Received: August 12<sup>th</sup>, 2016

Accepted: October 10<sup>th</sup>, 2016

DISCLOSURES: NONE

## INTRODUCTION

The high prevalence of inflammatory diseases in paediatric patients makes the occurrence of prominent adenoidal tissue and cervical lymphadenopathy a common finding. Unfortunately, rare nasopharyngeal carcinoma (NPC) shares these physical findings in common with benign inflammatory diseases of the pharynx. These patients are generally treated with several courses of antibiotics without response, and ultimately require a biopsy to exclude other pathologies such as NPC or lymphoma. There are no specific symptoms that point to the

**ABSTRACT**

**Background:** Nasopharyngeal carcinoma is a rare tumour arising from epithelium of the nasopharynx. It constitutes only 1-5% of all cancers. In Nigeria, it represents 1.7-2% of all cancers with a prevalence rate of 4/100,000. The incidence of nasopharyngeal carcinoma in children is even rarer, accounting for less than 1% of all childhood malignancies. Ten to twenty percent of nasopharyngeal carcinoma in Nigeria occurs in children.

**Aim:** To increase the index of suspicion of clinicians to this disease in children for prompt diagnosis and management.

**Case Reports:** The patients were 8 and 16 year-old Nigerian males who presented with painless neck swelling at the paediatric clinic of a tertiary hospital in south eastern Nigeria. Both were misdiagnosed and managed for tuberculous lymphadenitis until a histological diagnosis suggested nasopharyngeal carcinoma. They were referred to a paediatric oncologist at a premier tertiary hospital for further management, following confirmation by otorhinolaryngologists.

**Conclusion:** Though rare, nasopharyngeal carcinoma should be included as a differential in children presenting with cervical lymphadenopathy. As a result, a throat examination by an ENT surgeon should be made routine in all children presenting with cervical lymphadenopathy. This is desirable since early diagnosis and prompt treatment lead to a better prognosis.

**Keywords:** Airway, cervical, children, lymphadenopathy, tuberculosis

diagnosis of NPC. High index of suspicion is, therefore, necessary to diagnose NPC in children.

## CASE REPORTS

**Case 1**

An 8-year old Nigerian boy with 4 month history of painless, progressively increasing, bilateral neck swelling and intermittent low grade fever was seen at the paediatric clinic of a tertiary hospital in South-East Nigeria. Clinical examination revealed massive, discrete lymphadenopathy, and bilateral neck swelling extending from the angle of the

jaw to the mid neck on both sides. An initial clinical diagnosis of tuberculous lymphadenitis to rule out Non-Hodgkin's lymphoma was made.

Full blood count results were essentially normal, Erythrocyte sedimentation rate was 30mm/hr. Lateral neck x-ray of the head and neck showed soft tissue fullness of the roof and posterior wall of nasopharynx with associated narrowing of the nasopharyngeal airway. There were few irregular and punctate calcifications noted around the aforementioned soft tissue but with no definite associated bony destruction seen. Findings were suggestive of nasopharyngeal mass lesion. A computed tomography (CT) scan of the base of the skull and nasopharyngeal region was advised. However, CT scan was not done due to financial constraints. Chest x-ray was normal. An incisional biopsy of the mass was done and a trial of anti-Koch's regimen was started while awaiting histological diagnosis. However, the patient's condition continued to deteriorate as he subsequently developed haemoptysis, epistaxis and hearing impairment while on admission.

Examination of routinely stained Haematoxylin and Eosin slides showed complete effacement of normal nodal architecture due to proliferating poorly-differentiated squamous cells disposed in irregular masses, see Figure 1. A histological diagnosis of metastatic carcinoma arising from a possibly nasopharyngeal primary was made.

Otorhinolaryngologists were then invited to review the patient and a biopsy of the nasopharyngeal tumour was taken which confirmed the nasopharyngeal origin of the tumour.

### Case 2

A 16-year old Nigerian male presented with a left, painless neck mass that has been increasing progressively in size for about 1year and 7months with associated headache, occasional fever, and intermittent bleeding

from the nose and mouth. There was also blurred vision on the left eye.

On clinical examination, vital signs were normal. The neck mass measured 12cm x 15cm, hard and nodular. It was fixed to underlying structures but not attached to overlying skin. Full blood count result was essentially normal. Erythrocyte sedimentation rate was elevated at 56mm/hr.

A diagnosis of tuberculous lymphadenitis was entertained and patient started on trial anti-Koch's regimen based on clinical judgement. Mantoux test was done and it was within the normal range. With poor response after 2weeks of treatment, the suspicion of Hodgkin's lymphoma was entertained. The patient was started on Cyclophosphamide-Vincristine - Methotrexate - Prednisolone regimen, based on clinical presentation and deteriorating condition of the patient before incision biopsy was done.

Examination of routinely stained Haematoxylin and Eosin slides showed complete effacement of normal nodal architecture due to proliferating poorly-differentiated squamous cells disposed in irregular masses, see Figure 2. A histological diagnosis of metastatic carcinoma arising from a nasopharyngeal primary was made.

Otorhinolaryngologists were invited to review the patient and a biopsy of the nasopharyngeal tumour was taken. On confirmation of the nasopharyngeal origin of the tumour, the patient was referred to a paediatric oncologist at a premier tertiary hospital for further management.

### DISCUSSION

Nasopharyngeal carcinoma (NPC) was first described as a separate entity by Regaud and Schmincke in 1921.<sup>1</sup> It is a rare tumour arising from epithelium of the nasopharynx. Nasopharyngeal carcinoma constitutes only 1-5% of all cancers. The incidence of NPC in children is even rarer accounting for less than 1% of all childhood malignancies.<sup>2</sup> It has a bimodal age distribution. A small peak is

observed in late childhood (adolescence), and a second peak occurs in people aged 55-65 years. Our second patient was also an adolescent. The youngest case of NPC reported was a two-year old and the eldest was 91 years old.<sup>2</sup>

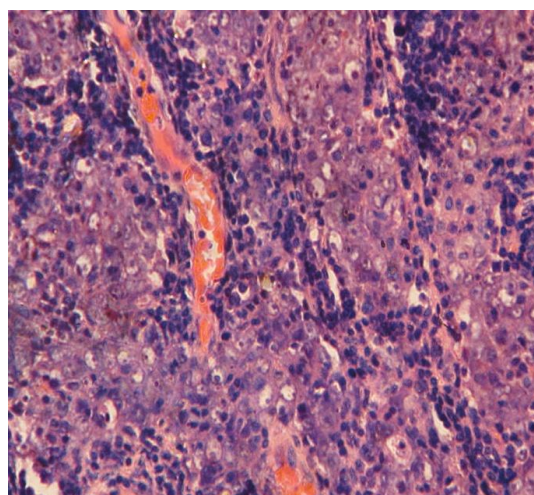
It is primarily a disease of adults and its incidence in children varies with geographical location. Incidence is approximately 1 in every 100,000 children annually, among Caucasian children of North America and Europe. The disease is far more common in children of Southeast Asian and Northern African descent, with an incidence of 8-25 in every 100,000 children annually. In China, where there is a high frequency of this tumour, less than 1% of NPC occurs in children under 14 years of age. By comparison, 10-20% of NPC in Tunisia, Uganda, Kenya, Nigeria, and Sudan occur in children.<sup>3</sup>

It represents 1.7-2.0% of all cancers in Nigeria with a prevalence rate of 4 per 100,000.<sup>4,5</sup> There is a male preponderance with a male-to-female ratio of approximately 2:1.<sup>4,5,6</sup> The two cases reported here were also males, agreeing with the higher incidence in males.

As in both cases presented, nasopharyngeal carcinoma rarely comes to medical attention before it has spread to regional lymph nodes. The most common physical finding is a neck mass, which is painless, firm lymph node enlargement seen in 80% of patients.<sup>2</sup> Studies showed more than 90% of patients presented with neck swelling.<sup>7,8</sup> Neck involvement is often bilateral; the most common nodes involved are the jugulodigastric, upper and middle jugular nodes in the anterior cervical chain.

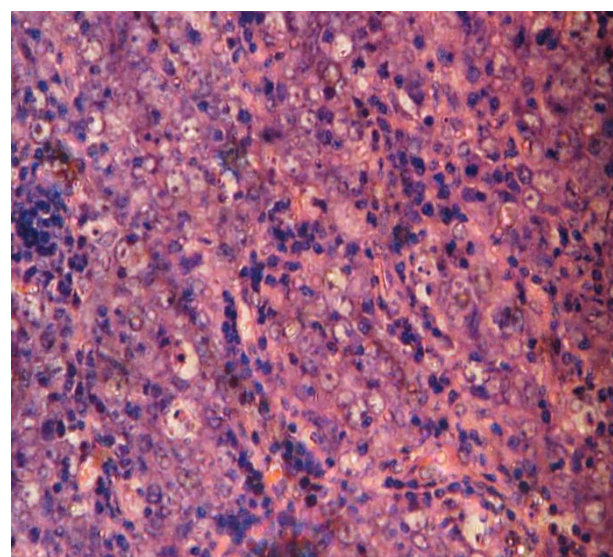
Epstein Barr Virus (EBV) Viral deoxyribonucleic acid (DNA) in nasopharyngeal carcinoma has revealed that EBV can infect epithelial cells and is associated with their transformation to cancer.

**Figure 1.** Photomicrograph of case 1



A genetic aetiology has been considered due to the higher rates of disease within specific ethnic groups, patients with first-degree relatives with the disease, patients with A2 human leucocyte Antigen (HLA) haplotypes, and cytogenetic abnormalities identified within tumour samples. Environmental causes must be considered due to the geographical distribution of the disease and association seen in patients who consume a large amount of preserved foods and/ or salted fish.<sup>5</sup>

**Figure 2.** Photomicrograph of case 2



Nasopharyngeal carcinoma in childhood differs from its adult counterpart in the high prevalence of the undifferentiated subtype,



advance clinical stage at diagnosis and better chances of survival.<sup>9</sup>

The results of recent clinical trials that include both radiation therapy and chemotherapy, generally report long-term survival between 50-80% overall.<sup>10,11</sup> The risk of long-term treatment-related toxicity also may be a more important issue in these individuals.

#### CONCLUSION

Though rare, nasopharyngeal carcinoma should be included as a differential in children presenting with cervical lymphadenopathy. As a result, a throat examination by an ENT surgeon should be made routine in all children presenting with cervical lymphadenopathy. This is desirable since early diagnosis and prompt treatment lead to a better prognosis.

#### REFERENCES

1. Chyi S, Fatterpekar G, Chen C, Son PM. The imaging of diverse manifestation of nasopharyngeal carcinoma. *AJR Am J Roentgenol* 2003; 180: 1715-1722.
2. Noorizan Y, Chew YK, Khir A, Brito-Mutunayagam S. Nasopharyngeal Carcinoma: Recognizing it Early in Children with Otitis Media with Effusion. *Med J Malaysia* 2008; 63(3): 261-262.
3. Stanbuk HE, Patel SG, Mosier KM, Wolden SL, Holodney AI. Nasopharyngeal Carcinoma: Recognizing the Radiographic Features in Children. *AJNR Am J Neuroradiol* 2005; 26:1575-1579.
4. Obafunwa JO, Bhatia PL. Nasopharyngeal Carcinoma in Plateau State, Nigeria: A Pathological Study. *Eur J Surg Oncol* 1991; 17(4):335-337.
5. Alabi BS, Badmus KB, Afolabi OA, et al. Clinico-pathological Pattern of Nasopharyngeal Carcinoma in Ilorin, Nigeria. *Niger J Clin Pract* 2010; 13(4):445-448.
6. El-Husseiny G, Alam A, Khafaga Y, et al. Nasopharyngeal Carcinoma in Children and Adolescents. *J Egyptian Nat Cancer Inst* 2000; 12(3): 151-155.
7. Iseh KR, Abdullahi A, Malami SA. Clinical and Histological characteristics of Nasopharyngeal Cancer in Sokoto, North-West Nigeria. *W Afr J Med* 2009; 28(3): 151-155.
8. Laskar S, Sanghavi V, Muckaden MA, et al. Nasopharyngeal Carcinoma in Children: Ten years' experience at the Tata Memorial Hospital, Mumbai. *Int J Radiat Oncol Biol Phys* 2004; 58(1): 189-195.
9. Ayan I, Altun M. Nasopharyngeal carcinoma in children: retrospective review of 50 patients. *Int J Radiat Oncol Biol Phys* 1996; 35(3):485-492.
10. Roper HP, Essex-Cater A, Marsden HB, Dixon PF, Campbell RH. Nasopharyngeal Carcinoma in Children. *Pediatr Hematol Oncol* 1986; 3(2):143-152.
11. Sahraoui S, Acharki A, Benider A, Bouras N, Kahlain A. Nasopharyngeal Carcinoma in Children under 15years of Age: A Retrospective Review of 65 Patients. *Ann Oncol* 1999; 10(12):1499-1502.